

Volume 58 Number 3
June/July 2012

 IDA
irish dental association

Journal of the Irish Dental Association

Iris Cumainn Déadach na hÉireann



Root canal

Radiographic evaluation of the technical quality of undergraduate endodontic 'competence' cases in Dublin Dental University Hospital: an audit

An *in vitro* scanning electron microscopic study comparing the efficacy of passive ultrasonic and syringe irrigation methods using sodium hypochlorite in removal of debris from the root canal system

Welcome to a new layer of expertise in dentine hypersensitivity

Today you can go further than simply relieving your patients' dentine hypersensitivity.

Today you have new Sensodyne® Repair & Protect containing NovaMin® calcium phosphate technology. NovaMin® builds a reparative hydroxyapatite-like layer over exposed dentine and within the tubules¹⁻⁵

Starting to form from the first use,⁵ this reparative layer creates an effective and lasting barrier to dentine hypersensitivity⁶⁻⁸

*Explore the new layer of opportunity
with Sensodyne Repair & Protect*

Visual representation of dentine cross-section and dynamic reparative layer



IDA PRESIDENT **Dr Conor McAlister**
 IDA CHIEF EXECUTIVE **Fintan Hourihan**
 JOURNAL CO-ORDINATOR **Fionnuala O'Brien**

EDITOR

Professor Leo F.A. Stassen
 FRCS(Ed), FDSRCS, MA, FTCD, FFSEM(UK) FFDRCSI

DEPUTY EDITOR

Dr Dermot Canavan
 BDentSc, MGDS(Edin), MS(UCalif)

EDITORIAL BOARD

Professor Finbarr Allen
 BDS PhD MSc FDS FDS(Rest Dent) RCPS
 FFDRCSI

Dr Michael Crowe
 BSc BDentSc DPDS (Bristol)

Dr David Hussey
 BDS PhD FHEA FDSRCS FFDRCSI FDSRCS

Dr Mark Kelly
 BA BDentSc

Dr Christopher D. Lynch
 BDS PhD MFDRCSI FDS (RestDent)RCSI
 FACD FHEA

Jennifer O'Rourke
 RDN

Dr Ioannis Polyzois
 DMD, PhD, MDentCh, MMedSc

Dr Ciara Scott
 BDS MFD MDentCh MOrth FFD (RCSI)

Dr Seamus Sharkey
 BDS NUI FRACDS (Syd) MFDSRCS DChDent
 (Prosthodontics) FFDRCSI

Dr Simon Wolstencroft
 BDS FDSRCS MScD MOrth FDSOrth

The *Journal of the Irish Dental Association* is the official publication of the Irish Dental Association. The opinions expressed in the Journal are, however, those of the authors and cannot be construed as reflecting the Association's views. The editor reserves the right to edit all copy submitted to the Journal. Publication of an advertisement does not necessarily imply that the IDA agrees with or supports the claims therein.

For advice to authors, please see:
www.dentist.ie/resources/jida/authors.jsp

Published on behalf of the IDA by
 Think Media, 537 NCR, Dublin 1
 T: 01-856 1166
www.thinkmedia.ie

EDITORIAL

Ann-Marie Hardiman, Paul O'Grady

DESIGN AND LAYOUT

Tony Byrne, Tom Cullen, Ruth O'Sullivan

ADVERTISING

Paul O'Grady

The Journal of the Irish Dental Association:
 - is the only dental publication produced in Ireland;
 - is Irish dentists' own Journal of record.

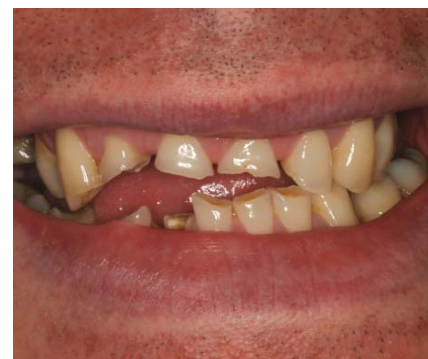125	EDITORIAL
126	PRESIDENT'S NEWS A time to form alliances
127	LETTERS TO THE EDITOR
128	NEWS
130	QUIZ
134	BUSINESS NEWS
136	EU NEWS CED meets in Copenhagen – amalgam hits the headlines
138	FACT FILE Types of bruxism
142	ABSTRACTS
145	IDA NEWS Tax status of associates and hygienists ... IDA makes submissions to Government ... Complaint resolution service ...
149	PEER-REVIEWED
149	Lingual orthodontics: an illustrated review with the incognito fully customised appliance <i>J Buckley</i>
156	An <i>in vitro</i> scanning electron microscopic study comparing the efficacy of passive ultrasonic and syringe irrigation methods using sodium hypochlorite in removal of debris from the root canal system <i>VS Agrawal, S Kapoor</i>
162	Radiographic evaluation of the technical quality of undergraduate endodontic 'competence' cases in the Dublin Dental University Hospital: an audit <i>M Kumar, HF Duncan</i>
168	CLASSIFIED
170	DIARY OF EVENTS



News

131

The Minister comes to Killarney



Fact file

138

Types of bruxism



Peer-reviewed

149

Lingual orthodontics

Irish Dental Association Unit 2 Leopardstown Office Park, Sandyford, Dublin 18.
 Tel: +353 1 295 0072 Fax: +353 1 295 0092 www.dentist.ie
 Follow us on Facebook (Irish Dental Association) and Twitter (IrishDentists).



Total average net circulation 01/01/11 to 31/12/11:
3,397 copies per issue. Circulated to all registered dentists
 in the Republic of Ireland and Northern Ireland.

DENTAL COVER.IE

by Vhi DeCare

Introducing DentalCover.ie, the new face of Vhi DeCare Dental
and the new name for dental insurance in Ireland

Visit our online store and oral health hub at
www.dentalcover.ie or call our Dental Practice
Support team on 1890 222 422



50% OFF
KIDS
IN JUNE*

Tell your patients

Each member that signs up to
Dental Plan before June 30th
will get an amazing 50% off their
children's premiums*

FIND OUT MORE...

www.dentalcover.ie

*Child must be under 18 years at policy start date. Promotion rate is 50% off the standard net child rate of Dental Plan purchased in June with an effective date of 1st, 8th, 15th or 22nd June 2012. At least one adult must be insured on Dental Plan. There is no cash equivalent to this offer. DentalCover.ie Rules – Terms & Conditions apply. We reserve the right to extend this offer.

The Voluntary Health Insurance Board trading as Vhi Healthcare and DentalCover.ie is regulated by the Central Bank of Ireland.
This product is underwritten by DeCare Dental Insurance Ireland Limited trading as DentalCover.ie and is regulated by the Central Bank of Ireland.

Lit000048

Good science matters

Honorary Editor LEO STASSEN calls on dentists to stand up for good science and better oral health.

This *Journal* is accompanied by a supplement that has been put together by a group of experts to reflect on 50 years of fluoride in the Irish drinking water supply. It demonstrates, again, that fluoridation of the Irish water supply has delivered measurable benefits. And even though we are marking 50 years since the introduction of the first of the statutory instruments giving power to the Act, the arguments for fluoridation are as relevant as ever. In addition, perhaps unusually with an academic journal, our timing is critical. An individual, Declan Waugh, describing himself as an independent environmental scientist, has authored a report in which he makes several alarming claims about the effects of fluoridation.

Closer scrutiny of these claims by The Irish Expert Body on Fluorides and Health, chaired by Dr Seamus O'Hickey, shows that Waugh's claims are spurious. Specifically, the Irish Expert Body says: "The author of this report, Mr Declan Waugh, contends that fluoridation is harmful to humans and the environment. The report contains a great number of allegations of ill health and potential damaging effects. The Irish Expert Body on Fluoridation and Health has examined this report and finds that it is not reliable". It goes on to state: "The report is expertly produced and is impressive in size and appearance. However, in spite of its presentation, its content is decidedly unscientific".

Speaking out

This brings me to another issue of relevance to our profession and our Association. We need our experts, such as Seamus O'Hickey, to speak out on these issues. Difficult as it may be, the profession needs to engage with mainstream media on topics of scientific import. In recent years, the Association has made great progress in changing the public perception of the Irish dentist and there is a much more nuanced understanding of Irish dentistry now than existed even five years ago. We need to take advantage of this and have our experts speak out on important issues. The mouth cancer awareness campaign is a good example of what we can achieve. We need to do the same now on science and policy, such as when the benefits of fluoride are denigrated, and on how the oral health of our population is being allowed to decline because the Government appears entirely ignorant of the consequences of its decisions. I strongly encourage leaders in dentistry and leaders in the community to speak out –

loudly – on every appropriate occasion. Dentistry deserves more respect than it is receiving and we have the power to raise awareness among ourselves.

Packed issue

This is a packed issue of the *Journal* and would occupy you fully even without our supplement. We have excellent peer-reviewed papers on lingual orthodontics, methods of removing debris from the root canal system, and radiographic evaluation of undergraduate endodontic cases in DDUH, and a top class fact file on bruxism. Tom Feeney reports on an important meeting in Europe and there is an interesting exchange of letters on professional indemnity. And, of course, there is the report from the very successful proceedings in Killarney of the IDA Annual Conference.

Welcome to our new President

Finally, we welcome Dr Andrew Bolas for the first of his President's messages. He takes office at a difficult time for dentistry and has already demonstrated a sure touch in his management of the Annual Conference. We wish him every success and hope that many more will join him in advocating for better oral health in Irish society.



A handwritten signature in blue ink that reads "Leo F. A. Stassen".

Prof. Leo F. A. Stassen

Honorary Editor

A time to form alliances

It is a great pleasure and honour for me to write my first President's news, says DR ANDREW BOLAS.

I thank the HSE Dental Surgeons Group of the Association for nominating me for the role. I hope to continue the good work of our outgoing President, Dr Conor McAlister, and I congratulate him on a successful year as President of the Association. I also congratulate Dr Sean Malone of the Metro Branch on his nomination as President Elect for next year.

For those of you who don't know me, I am an oral surgeon employed by the HSE in Sligo as the Senior Administrative Dental Surgeon. I qualified in Queens in 1990, and worked for a number of years in hospitals in Northern Ireland. I then worked in general practice and limited practice before finally settling in Sligo in 1997.

Many of you will know me through dental radiology, which I studied in King's College, London, and which has become one of my favourite parts of my current practice.

Annual Conference 2012

The Annual Conference is just over, and like me, many of you might still be recovering. My appreciation and thanks go out to all the delegates who travelled down to the Kingdom. I hope you all left with a little extra wisdom, some new friends and as many good memories as I have.

To our trade sponsors, a massive THANK YOU: without your support it would be impossible to make the conference the event it is each year. I hope you enjoyed meeting us as much as we enjoy meeting you.

As always, our speakers performed above and beyond the call of duty and the feedback I have received has been outstanding. I am always amazed and delighted when those speakers who have travelled come away saying how much they enjoyed their audiences at the conference, and our social programmes are legendary.

We were fortunate to be joined on the Friday afternoon by the Minister for Health, Dr James Reilly TD. He was not the bearer of good news, but neither did he land any bombshells. He did however spend some time speaking to our Association CEO Fintan Hourihan and myself.

For those that could not make it to the gala dinner on the Saturday night, words cannot quite do justice to our after-dinner speaker, Kingsley Aikens, whose wit and insight were a pleasure to listen to. And of course Dario's dancing masterclass later on helped to finish off a very entertaining evening.

Year ahead

Turning to the year ahead, I have no doubt that the economic climate will be slow to change and we will be faced with many challenges.

I feel that this year should be an opportunity for us to form strategic alliances with other representative bodies, such as the Irish College of General Practitioners and the Irish Medical Organisation, for issues like smoking cessation, the links between oral health and general health, and oral cancer awareness. Opportunities also exist to work with other bodies such as the Irish Pharmacy Union.

A number of processes are likely to come to a conclusion in the coming year, such as the Review of Orthodontic and Maxillo-facial Services, and we must await the reports from these to assess how the Union and the Association must respond. The second phase of the HSE Dental Service restructuring is also likely to commence, and in the near future we will have a permanent appointment as National Lead for Oral Health.

We must also seek to address the inequalities in the DTSS and DTBS schemes, and take the initiative in proposing how these schemes should be run.

Mouth Cancer Awareness Day will happen this year on September 19, and I hope I can call on all my colleagues to support the day and build on the success of last year's event.

Dr Andrew Bolas

IDA President



Dear Editor,

I note with dismay that dental indemnity insurance for dentists operating in the Republic of Ireland is approximately €6,000 per year. For most young associate dentists this means that they are working pro bono for at least a month per year to pay this charge. It is unfair to burden general dentists who do not participate in high-risk activities such as orthodontics, endodontics and cosmetic treatments with this charge. I propose that as a profession we have a debate about how we price dental indemnity insurance. Perhaps it is time to look at a similar model to car insurance, where those with previous accidents, a nonchalant attitude to safety, and who drive large expensive cars pay more. It may interest some of your readers to know that I pay less than €800 a year for dental indemnity insurance in Australia, yet dental treatment is very expensive in this country. Blaming the recession or a litigious population is simply not good enough; we need to take the plank out of our own eye first.

Yours sincerely,

Dr Jarlath Loftus
Canberra, Australia

Dear Editor,

I am grateful to you for the opportunity of responding to this interesting letter, which is very timely after a period of rapid escalation of dental claims in Ireland, and a significant increase in the cost of dental professional indemnity – although I should perhaps point out that only a small minority of Irish dentists would be paying the €6,000 to which reference is made. As your readers may know, Dental Protection Limited (DPL) is the provider of professional indemnity to the large majority of dentists in Ireland and they may also know that since April 2012 DPL has introduced two initiatives, one of which rewards (through subscription reductions) those members who take active steps to reduce their risk, while those who have a significantly higher than average claims experience will pay up to five times more than the normal subscription – so we have already gone somewhat further than your reader suggests on both counts.

What your readers may not know is that DPL also has over 5,000 members in Australia, a country where we have worked in every state and territory for over 40 years. A typical full-time practitioner in Australia, having graduated four or more years, pays the equivalent of €1,700-2,000, although this varies from state to state, and just as in Ireland, recent graduates pay a lot less than this in the first two years. However, your readers may find it interesting to learn why there is such a wide difference in subscriptions between Australia and Ireland.

Twelve years ago Australia suffered what became known as its “medical indemnity crisis” when the (then) leading provider of professional indemnity for medics (AMIL/“United”) went into receivership, leaving 60% of Australian medics without indemnity overnight. A subsequent Government inquiry concluded that the company concerned had, over many years, consistently failed to collect sufficient

subscriptions/premiums to meet its long-term liabilities, having been more concerned with undercutting competitors and increasing its market share. The Australian Government stepped in to guarantee all the liabilities of the failed company in order that the medics (and some dentists) could continue to practise and hospitals could re-open. The Government funded this emergency action by a statutory levy that all the former members of that organisation were required to pay on top of the subscriptions they had already paid. In short, they ended up paying what they should have been paying in the first place. The imposition of this compulsory levy deliberately included retired medics and dentists who had benefited from the artificially low rates.

What then followed was a major series of tort law reforms affecting all Australian states to a greater or lesser degree – in short, the law relating to clinical negligence claims was fundamentally changed, making it much more difficult for claimants and their solicitors to bring such claims against medics and dentists alike. In New South Wales and Victoria dental claims shrank from a flood to a trickle, and in Queensland they virtually disappeared altogether. The same can hardly be said for the situation in Ireland, where the number of claims has recently almost doubled in little more than a year.

Another hugely important difference is that all medical and dental indemnity in Australia must now, by law, take the form of contractual insurance. Such “claims made” insurance arrangements typically defer some of the total cost of the claims that will arise in the future and because of this, they can appear cheaper initially – especially for people who have only recently commenced practice – because they have no historic claims to fund. The kind of indemnity provided by DPL here in Ireland is the very different and much more comprehensive “occurrence-based” indemnity, where the payment of a subscription for a given membership year provides indemnity for an unlimited number of years into the future, for all the treatment provided during that membership year. There is also no financial limit on the level of cover provided by DPL (unlike any kind of insurance where financial limits, terms, conditions and exclusions will generally apply).

In summary, comparing Ireland with Australia where dental professional indemnity is concerned is about the most extreme example one could choose of comparing apples with pears. Responsible indemnity providers need to take and act upon the best possible actuarial advice and charge neither more nor less than they need to charge in each individual jurisdiction. The Australian experience starkly demonstrates the crucial difference between the rates that healthcare professionals would prefer to pay, and what rates are actually necessary to keep them safe. As a not-for-profit organisation that is owned jointly by its members, DPL does not charge them a single Euro more than is absolutely necessary in order to protect them securely. Charging any less simply stores up serious problems for the future, and the members of a mutually owned organisation like DPL have a right to expect a lot better than that.

Yours sincerely,

Kevin J Lewis BDS FDSRCS FFGDP LDS RCS
Dental Director, DPL

New eLearning resource for dentistry

A Community of Practice (CoP) for Dentistry has been established within the National Digital Learning Resource (NDLR), a service funded by the Higher Education Authority.

The vision for this CoP is to create an online learning resource where the Cork (UCC), Dublin (TCD) and Belfast (QUB) Dental Schools would contribute instructional videos or online resources in clinical disciplines where they have particular expertise. This would allow for the wide dissemination of teaching material. Furthermore, it would promote collaboration between the three dental schools in developing student-centred and innovative forms of teaching. Additionally, the CoP would promote, support and sustain the integration of teaching, learning and research.

Dentistry is a three-dimensional subject and online media such as videos, podcasts, interactive applications and collaborative websites can greatly enhance a student's educational experience; it allows them to control and manage the time, location and pace at which their learning takes place. It also allows revision and repetition of the same topic as many times as is required. It is impossible to control the quality of everything posted on the internet, and what students can



Pictured are: Dr Noel Ray; Dr Frank Burke; Dr Gerry McKenna; and, Dr Sharon Curtin from Cork University Dental School and Hospital, UCC, who attended the recent NDLR Fest in Croke Park, Dublin, to present the initial outcomes of the project. The project confirmed the relevance of eLearning to dentistry and substantiated the need to expand and further develop the CoP for dentistry.

Will you still be smiling at the end of the year?

Make sure your practice is profitable in 2012

As Ireland's only specialist dental accountants we're here to help you control your practice costs

QUARTERLY ACCOUNTS

PAYROLL SERVICES

TAX CONSULTANCY

COST OF TREATMENT



MedAccount SERVICES

Medaccount offer a full range of specialist dental accounting support and advisory services for Associates, Principals, Expense Sharing Partners and Hygienists.

FIRST
CONSULTATION
FREE

MedAccount Services

96 Lower Georges Street

Dun Laoghaire

Co Dublin

Tel: 01 280 6414

Email: info@medaccount.ie

First consultation free of charge, with no obligation to engage

and will access. Therefore, one of the benefits of the CoP is that the NDLR provides a platform for educators to control and monitor the content that is uploaded. This provides standardisation of educational material throughout the dental schools as students will access material that has been vetted by the educator.

The main areas that have been identified for initial creation of resources are: restorative dentistry; orthodontics; oral surgery; paediatric dentistry; oral medicine; dental materials science; behavioural science as applied to dentistry; cross infection control in clinical practice; dental materials technology; and, special care dentistry.



Irish dentist receives prestigious alumni award

Mr Martin Kelleher has been awarded the prestigious Alumnus Distinguished Service Award by the King's College London Dental Alumni Association.

The award is intended to honour a long-serving member of staff who has made a significant contribution to the Dental Institute or one of its constituent

Schools. Mr Kelleher, who is a graduate of University College Dublin, is a Consultant in Restorative Dentistry at King's College London Dental Institute. He has lectured extensively both nationally and internationally for over 25 years, and is the author of many peer-reviewed articles and a book on dental bleaching.

Postgraduate Diploma in Conscious Sedation in Dentistry

The Dublin Dental University Hospital (DDUH) is inviting applications to the 18-month Postgraduate Diploma in Conscious Sedation in Dentistry, which will commence in January 2013.

The course is aimed at primary care dental practitioners providing support for those patients with dental anxiety and undertaking dentistry in a safe, effective and anxiety-free manner. It also aims to provide a recognised education and training programme that will equip dentists with the knowledge, skills and experience to safely and independently use conscious sedation techniques in their own clinics. The objectives of the course are to provide:

1. A comprehensive education in clinical practice of conscious sedation, anxiety and pain control for patients, and in the theoretical principles.

2. Development of an ability to critically analyse and apply the findings of the professional literature.

The Postgraduate Diploma is awarded by the University of Dublin, Trinity College, and is a registerable qualification with the Dental Council. The course will involve attendance for 11 didactic days and a minimum of 20 clinical, hands-on sessions in the DDUH or an associated hospital over an 18-month period. Assessment throughout the course will be by:

- written examinations;
- course work and essays;
- oral presentations;
- a literature review project; and,
- professional practice placement logbook.

Further details may be obtained by logging on to www.dentalhospital.ie or www.tcd.ie/graduatestudies. Applications to the course can only be made online by logging on to www.tcd.ie/courses/postgraduates from May 2012, with a closing date of September 30, 2012. Please address any enquiries to Catherine Creagh, Course Administrator, Tel: 01-612 7354 between 9.30am and 1.30pm, or Email: catherine.creagh@dental.tcd.ie.



medray
helping you to help others





Wireless Intraoral Camera

The ideal tool for any dental practitioner

Carestream 1500 Intraoral Camera





Authorised Dealer

Only
€3,499

Quote this advertisement for your discount
Terms & Conditions apply;
Offer valid until 31/07/12
Prices excluding VAT.

Wireless - Intraoral Camera
**€500
Discount**

Call Us Today For A Demo...

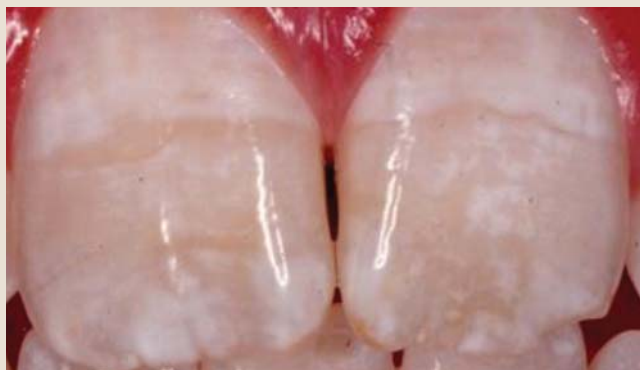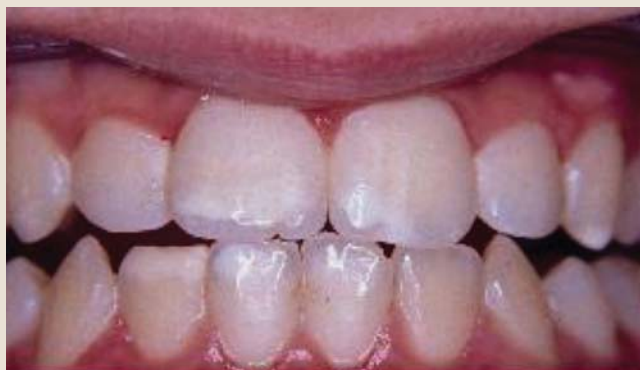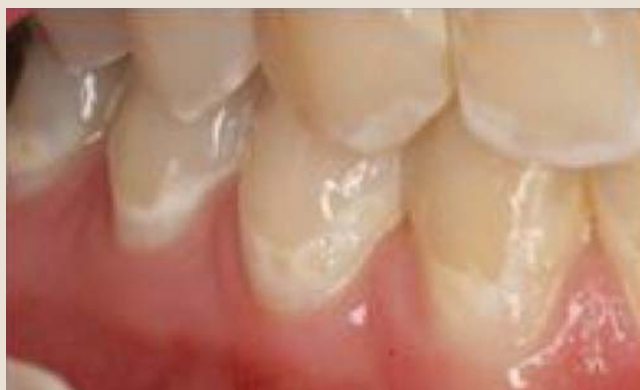www.medray.ie

T: +353 1 466 3773 E: info@medray.ie

Quiz

Submitted by Jennifer Carmody.

Figures 1, 2 and 3 show enamel opacities.



1. What are they and how would you treat them?
2. What do these examples of enamel opacities have in common?
3. Which of them is the odd one out?

Answers on page 143

Dentists welcome GAA move on gumshields



The Irish Dental Association (IDA) has welcomed the decision by the GAA to make it compulsory for players to wear mouth guards in football games and training.

The recent GAA Congress passed a motion making it mandatory for juvenile players up to minor grade to wear mouth guards from the start of 2013. The rule will come into effect for senior players from the start of 2014.

While some senior inter-county players have already expressed reservations about the rule, Dr Maurice Quirke of the IDA has urged all players, parents and coaches to support it fully.

"Anybody who is playing contact sports without a mouth guard is being irresponsible. It's like going on a motorbike without a helmet. I would urge all players to protect their teeth from injury by using a gumshield immediately. Players are important role models for children so it is particularly important that they back the move," he said.

IDA figures indicate that Ireland has one of the highest rates of sport-related oral injuries in the EU, with one-third of all adult dental injuries being sports related. In many sports such as rugby and hockey the wearing of gumshields is the norm, with nearly all clubs adhering strictly to a 'no gumshield – no game' rule. The IDA believes that parents and coaches in particular will have a key role to play in ensuring that a similar situation pertains for young players in gaelic football.

Dr Quirke, who is based in New Ross, Co. Wexford, said that some players were put off by ill-fitting gumshields and it was important to ensure that the mouth guard was as good a fit as possible.

"Pre-formed rigid mouth guards offer very little protection and are uncomfortable to wear. We wouldn't recommend using this type. Customised gumshields offer the best protection. A well-fitted sports guard made by your local dentist is what people should be opting for. For children between six and 12 years old whose teeth are constantly changing, the boil and bite type of mouth guard offers a practical and economical solution," he concluded.

The IDA believes the gumshield rule should also apply to hurling and is hopeful that the GAA will introduce a similar measure for that sport in the near future.

Minister salutes quality of Irish dentistry

Minister for Health Dr James Reilly TD praised Irish dentists and their representatives in his address to delegates at this year's Annual Conference in Killarney.

In his speech, the Minister praised the Dental Council for initiatives such as the Code of Practice, practice fee display and the Dental Complaints Resolution Service, all of which he said enhanced public confidence in the profession. He said that the Department would continue to work with the IDA for the benefit of the profession and patients, saying that: "no one has ever questioned the quality of Irish dentists".

The Minister acknowledged that the current economic situation meant that he would not be restoring benefits under the two dental schemes; however, he professed his willingness to begin discussions on the schemes, using this period of recession to design a new system of dental care to benefit the population in years to come.

Minister Reilly said that he recognised the challenges faced by dentists who were dealing with shrinking budgets, decreased spending, and the difficulty of retaining patients who no longer have access to PRSI benefits. He also said that there will be a public education process on patient entitlements under the DTSS.

The Minister briefly addressed the subject of orthodontic waiting lists, referring to a pilot project in the mid-west that has resulted in a shortening of waiting lists. He said that this was part of a series of ongoing initiatives to improve services without adding to costs.

He also stated that he is currently examining issues around competition law, and told delegates that the appointment of a Clinical Oral Health Lead is underway.

Ortho delays

The unacceptable delays experienced by children who need orthodontic treatment were among the issues highlighted by new Association President Dr Andrew Bolas in his inaugural address to delegates. Dr Bolas, who is a Senior Dental Surgeon with the HSE in Sligo, said that between 15,000 and 20,000 Irish children are on waiting lists for orthodontic treatment, with many waiting up to five years.

"The public health system only treats patients with severe dental problems so we know the children on these lists have serious issues. But the problem is much bigger than this. Tens of thousands of other children will not qualify for treatment and will either have to go without or pay for private treatment," he said.

Dr Bolas said that a totally inconsistent approach to school screenings meant thousands of other cases were being missed and he accused the Government of a betrayal of its duty of care to young people.

"In theory, all children under 16 are entitled to receive dental health screening and preventive treatments. In all they should be examined three times in primary school but some children are only receiving their initial screening in sixth class."

The Conference, with a theme this year of 'Wisdom in the Kingdom', saw several hundred dentists, dental nurses, hygienists, and



IDA President Dr Andrew Bolas and CEO Fintan Hourihan welcome Minister for Health Dr James Reilly to Killarney.

technicians gather to hear presentations from renowned national and international speakers.

Thursday's Pre-Conference courses offered hands-on training in everything from endodontics to ergonomics, and the Association and Union AGMs on Thursday evening gave delegates the opportunity to vote on motions that determine policy for the coming year.

Dental Team Day on Friday covered a dizzying range of topics. Beginning with Dr Tim Donley's presentation on 'The new perio', the sessions covered clinical and non-clinical subjects for all dental professionals. In their presentation on motivational interviewing, Drs Don Morrow and Jennifer Irwin adopted an interactive approach to show delegates how to tap into patients' values to improve quality of care, while Bethany Valachi turned the focus to the practitioner with a look at how dental professionals can prevent serious joint and muscle damage by adopting the correct working postures, and using the right equipment. Dr Yusuf Omar ended the morning with an entertaining and informative look at the skills and equipment needed to deal with medical emergencies in the dental surgery.

The Minister's address on Friday afternoon was followed by a presentation from Dr Kevin Lewis of Dental Protection, which made excellent use of video footage to demonstrate different types of challenging patients and how best to deal with them in the dental practice. The final segment of the afternoon was a very interesting debate on 'Dentistry in the digital age', which brought together Dr Eamon Croke, President of the Dental Council, general dentist Dr Ryan Hennessy, and consumer affairs commentator Tina Leonard. Each speaker gave their view (and in Dr Croke's case the Dental Council's view) of the issues around patients' and dentists' use of digital



Winner of the Costello Medal, Thomas Murphy from UCC, is pictured with IDA President Dr Andrew Bolas and Mrs Jackie Costello.



Winner of the Moloney Award, Emily Clarke, with IDA President Dr Andrew Bolas and Dr Mary Coleman of the Dental Health Foundation.



Dr Andrew Bolas pictured with David Kiernan, Aoife Moran, and Finbarr O'Riordan of Colgate.



Siobhan Crowley and Jason Roddy of Medray.



Sam Boyle and Frederica Dawson of Wrigley with Dr Andrew Bolas.



Dr Ed Cotter gave a pre-conference course on denture repairs and additions.



Delegates could hone their skills at a range of pre-conference courses.



Dr Johanna Glennon offers expert advice on endodontics at one of the pre-conference courses.

technology to access and promote dental services. The presentations were followed by some lively discussion, ably chaired by Dr Jane Renehan, where issues such as the difference (if any) between 'patient' and 'consumer', and the importance of price in choosing dental care, were thrashed out.

On Saturday, team members divided for tailored sessions throughout the Malton Hotel's excellent conference facilities. Presentations once again covered a wide range of clinical and practice management issues, from effective collaboration between the dental and medical professions (an inspiring talk from Dr Steve Geiermann), to jaw disproportion in contemporary orthodontics (from Dr Simon Wolstencroft), and a fascinating insight into the latest research in orofacial pain management (from Dr Dermot Canavan).

Social

As ever, the Conference had a lively social side, augmented this year by opportunities to see the wonderful scenery around Killarney by

either hill walking in the National Park or, if that seemed a little too strenuous, a fascinating tour of Muckross House and Gardens. Team night on Thursday was game show and quiz night, and Friday saw the trade show party get things off to a great start, including the launch of the Sensodyne Sensitive Dentist of the Year Awards (see page 135). The highlight, as ever, was the Annual President's Dinner on Friday night, where guest speaker Kingsley Aikens set the tone for a great night of dinner, dance and craic.

Trade show

The dental trade was extremely well represented in Killarney, with over 40 stands displaying the very latest technology and products set up in the vicinity of the Conference sessions. There was a great buzz, as delegates interacted with the trade representatives, enjoying fruit, chocolates, sugar-free gum, and even 'toothy' cupcakes as they went! The organisers remain grateful to the trade sponsors for their ongoing support, without which the Conference could not take place.



Dr Conor McAlister received the past president's pin from new President Dr Andrew Bolas.



Speaker Dr Padraig McAuliffe; Susan Johnston, President of the Irish Dental Hygienists Association; and, speaker Dr Nick Lewis.



Drs Don Morrow and Jennifer Irwin, who presented on motivational interviewing.



Dr Andrew Bolas with Dr Tim Donley, who spoke on 'The new perio medicine'.



Dr George Priest addresses delegates.



Dr Kevin Lewis addressed delegates on managing challenging patients.



Consumer affairs commentator Tina Leonard took part in the debate on dentistry in the digital age.



It was all smiles for a pre-Heineken Cup Final face-off between Leinster aficionado Conor McAlister and Ulster stalwart Andrew Bolas (Conor's smile was of course destined to last as Leinster were triumphant on the day).



The Financial Experts for Dentists

At Omega Financial Management, our mission is to deliver financial solutions to meet the specific needs of dentists.

We understand how busy you are and how you work. So we provide a nationwide team of financial planning experts who will meet you at a time and location that suits you. They understand the financial challenges faced by dentists and will develop solutions specifically for you.

Speak to a financial expert who understands **your** world.

Call us at 1850 260 261 or email info@omegafinancial.ie for an appointment with your regional consultant.



OFM Financial Ltd trading as Omega Financial Management is regulated by the Central Bank of Ireland

Omega Financial Management

Sensodyne Sensitive Dentist competition launched

The launch of the Sensodyne Sensitive Dentist of the Year Awards 2012 took place at the recent IDA Annual Conference in Killarney. In front of a very impressive ice sculpture (and a mouth-watering display of 'toothy' cupcakes), IDA Assistant CEO Elaine Hughes introduced Michelle Darlington, Brand Manager-Oral Health with GlaxoSmithKline, who said that GSK and the Sensodyne brand were delighted to be associated with the Awards.

"This is the fourth year of the Awards, which recognise clinical excellence and patient care by encouraging patients to nominate their dentists for the exceptional care they receive," she said. Michelle then introduced Dr Marcas Mac Domhnaill from nearby Tralee, who was the recipient of a highly commended citation in last year's awards.

According to Marcas: "It was lovely to be nominated; it's great to promote your own practice, and the profession of dentistry, particularly to people who suffer from fear of dental treatment".

Dentists can obtain the competition pack from GSK by returning the Freepost postcard, which is part of the wrap going around the outside of this edition of the *Journal*.



Pictured at the launch of the Sensodyne Sensitive Dentist of the Year Awards 2012 were: Michelle Darlington of GSK and IDA President Dr Andrew Bolas.

DentalCover.ie launched at IDA Conference



IDA President Dr Andrew Bolas (centre) at the launch to the profession of DentalCover.ie, with Maureen Walsh, General Manager, and Dr Ger Gavin, Chief Dental Officer, DentalCover.ie.

DentalCover.ie is the new name for the Vhi DeCare Dental business in Ireland. Launched to the profession at the IDA Conference in Killarney, the fresh look and feel of DentalCover.ie will create a new profile for dental insurance in Ireland. The dental insurance products themselves

have been revamped to include new features requested by both customers and dentists. DentalCover.ie is supported by a dedicated website and online store, where the public can compare product benefits and purchase online. The website also features an interactive 'find a dentist' section, which will be constantly updated with feedback from dental practices, along with comprehensive oral health resources, including an online version of the very popular *Oral Health Zone* magazine. These features will help consumers to be much more active in how they manage their oral health.

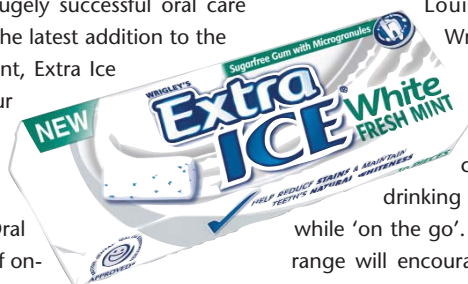Chief Dental Officer Dr Ger Gavin comments: "The new name, DentalCover.ie, will help customers recognise our dental insurance as a stand-alone product and differentiate it from health insurance".

Enhanced product benefits will include a simplification of the current Dental Starter Plan, along with the inclusion of loyalty benefits on Dental Plan, which will include a €500 orthodontic benefit for adults and children and increased yearly maximums. To mark the launch, each member that signs up to Dental Plan in June can avail of 50% off their children's premiums. See www.dentalcover.ie.

A fresh new flavour from Wrigley

Wrigley has added a new flavour to its hugely successful oral care brand, Extra. Extra Ice White Fresh Mint is the latest addition to the Extra Ice range, joining Extra Ice Peppermint, Extra Ice Spearmint and Extra Ice White. The four Extra Ice flavours, along with the Extra range and Orbit Complete, make up Wrigley's sugar-free oral care range.

This new addition comes as the Wrigley Oral Healthcare Program is developing a range of on- and offline resources for dental professionals with



the focus on educating patients on the benefits of sugar-free gum.

Louisa Rowntree, Communications Manager for Wrigley's Oral Healthcare Program says: "More and more consumers are recognising the benefits of chewing sugar-free gum and the launch of Extra Ice White Fresh Mint provides more flavour choice. Chewing sugar-free gum after eating and drinking is a simple and proven way to look after oral health while 'on the go'. We hope that the variety of products in our Extra range will encourage patients to look after their teeth by chewing sugar-free gum throughout the day".

Wireless intraoral camera

Medray Imaging Systems, based in Dublin, is introducing the new wireless Carestream 1500 intraoral camera to the Irish market. According to Medray, the Carestream 1500 intraoral camera is an ideal tool for any dental professional. Delivering precise, true-to-life images with each shot, the 1500 camera provides the visual evidence dentists need to educate patients and make more accurate diagnoses. Available in both a wired and wireless version, the 1500 Camera was designed for mobility and ease of use. Boasting a true autofocus and intuitive camera lighting system, this dental digital photography camera requires no manual adjustments and is easily shared between different examination rooms and chairs.



The Carestream 1500 wireless intraoral camera.

Assessing plaque problems

Effective plaque control is the cornerstone of any attempt to prevent and control periodontal diseases, but Colgate asks: are your patients achieving this on a daily basis?

Although the latest UK Adult Dental Health Survey* states that 75% of adults claimed that they cleaned their teeth at least twice a day, it reported that 66% of adults had visible plaque on up to 35% of their teeth. This is an improvement on the last survey, in 1998, where 75% of adults had visible plaque on 36% of their teeth. However, the survey explains that: "even moderate amounts of plaque can be difficult to see on the tooth with the naked eye, so where plaque has been recorded in this survey, it generally indicates a substantial accumulation. Visible deposits of plaque take some time to develop (at least 24 hours) and as most people brush their teeth once or twice a day, for plaque to have been recorded in this survey it is likely to be at points in the mouth where tooth cleaning has been ineffective on a fairly consistent basis".

The prevention and management of periodontal diseases requires consideration of the patient as a whole, and should be seen as a life-long process, shared between the clinician and their patient. It is therefore essential that clinicians assess the evidence for the advice they give and the efficacy of the products they recommend to optimise the periodontal health of their patients.

'Delivering Better Oral Health – an evidence-based tool kit for prevention' provides advice and support to be given to patients to improve their plaque control and gingival health. The strength of evidence is ranked from level V evidence, "opinions of respected authorities based on clinical evidence and descriptive studies", to level I evidence, "strongest evidence from at least one systematic review, of multiple, well designed, randomised control trial/s".

In the 'Improving periodontal health' section, level I evidence suggests that brushing teeth with a toothpaste containing triclosan and copolymer is more effective than ordinary fluoride toothpaste in improving plaque control and gingival health.

Colgate Total uniquely contains triclosan and copolymer, delivers 12-hour antibacterial protection, and is approved by the Irish Dental Association. See www.colgateprofessional.ie.

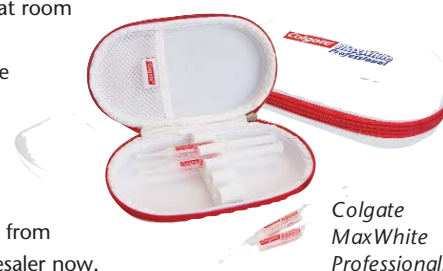

*UK Adult Dental Health Survey 2009, NHS Information Centre for Health and Social Care. *Delivering Better Oral Health – An evidence-based toolkit for prevention*, published by the Department of Health (England), Second Edition, July 2009.

Visibly whiter teeth in three days

Colgate is pleased to announce the launch of the Colgate MaxWhite Professional whitening system. This is a take home whitening system that gives your patients visibly whiter teeth in three days. Presented in an easy-to-use syringe format, it requires just 30 minutes' application time. New Colgate MaxWhite Professional contains 6% hydrogen peroxide and is clinically proven to be effective. It has been formulated with the addition of sodium fluoride and potassium nitrate to reduce patient sensitivity. Each kit contains 4 x 3ml syringes and should be stored at room temperature.

Colgate MaxWhite Professional is only available to dental professionals and can be purchased from your dental wholesaler now.



Colgate MaxWhite Professional.

CED meets in Copenhagen – amalgam hits the headlines

The recent CED meeting in Copenhagen covered a range of topical issues but dental amalgam, in the context of the Community Strategy Concerning Mercury, has now very definitely risen to the top of the agenda. DR TOM FEENEY reports.

A possible phase down, over a prolonged time period, of the use of dental amalgam is looking increasingly likely. What is now also very clear is that the non-use of amalgam separators in dental practices will no longer be tolerated.

Globally binding treaty on mercury

Mercury has been recognised as a substance of global concern by the United Nations' Environment Programme (UNEP) since 2003 and is, at EU level, subject to a comprehensive set of control measures under the Community Strategy Concerning Mercury adopted in 2005.

The EU has asked for the negotiation of a global legally binding instrument on mercury under the auspices of the UNEP. The agreed overall EU position (Council Conclusions from December 2008) calls for a comprehensive mercury instrument, covering actions to: reduce the supply of mercury; reduce the demand for mercury in products and processes; reduce international trade in mercury; reduce atmospheric emissions of mercury; achieve environmentally sound management of mercury-containing wastes; find environmentally sound storage solutions for mercury; address remediation of existing contaminated sites; and, increase knowledge.

The Decision of the Governing Council GC 25/5 gives the Intergovernmental Negotiating Committee (INC) a similarly broad mandate for a comprehensive instrument. INC-1, 2 and 3 have taken place, and INC-4 will take place in the week of June 25, 2012, in Punta del Este (Uruguay).

The Danish Presidency and the Commission are about to start preparations for this session in order to ensure that the EU continues to play an active and constructive role in the process. Final decisions will be made at a global level and, while Europe is very active in the global decision-making process, ultimately any global treaty will be binding on all territories.

CED reaction to the BIOIS report

In March 2012 BIOIS produced a draft report on reducing mercury pollution from dental amalgam. This was followed later that month by a stakeholders' consultation workshop where BIOIS presented its draft report and EU stakeholders, including the CED, provided oral feedback. In summary, BIOIS recommended: i) improved enforcement of EU waste legislation regarding dental amalgam; and, ii) banning the use of mercury in dentistry by 2018.

The CED sees the BIOIS draft final report as a significantly flawed and unbalanced draft document, which attempts to suggest inappropriately that a highly complex situation can be solved with an overly simple solution.

1. Much of the data it relies on is based on a survey requesting information from 27 disparate countries, which, as the CED previously discovered, is almost impossible to access with accuracy. Trends can be demonstrated, but the factors underpinning those trends and the dangers of destabilising evolution in situations that are, in any case, improving, must be better understood.
2. Regardless of the acknowledged estimations, assumptions and rough guesses, more worryingly the report contains dangerous speculation and inaccuracies of fact. It pays scant regard to the very complex issues that influence and surround the necessity to continue to improve the oral health of the populations of Europe in terms of social, economic, scientific and public health outcomes and, consequently, fails to balance that properly with the need to reduce the equally complex environmental load from dental practice as a whole.
3. Nevertheless, the draft report makes recommendations that in part confirm the CED's approach to dentists' responsible attitude to the environment. BIOIS's dismissal of a measured and controlled phase down of the availability and use of dental amalgam flies in the face of expert recommendations in the fields of dental materials, public health, health economics and dental academia, as documented in the 2009 WHO report 'Future Use of Materials for Dental Restoration'.
4. The CED urges the Commission to take a more balanced view than that which is represented in the current version of the BIOIS draft final report.

Next steps

At a meeting with DG Environment on May 3, 2012, the CED presented and explained its response to the BIOIS draft report. The EU position on dental amalgam and policy options for the future were also discussed, together with the likely impact of the global treaty on the EU approach. The CED plans to proceed as follows:

1. Prepare its response to the BIOIS final report when published.
2. Start preparing an evidence-based summary of alternative materials, starting with those containing Bisphenol A.
3. Internally consider the implications of a path to 'phase down' of dental amalgam.

Implications for amalgam use in Ireland

The CED recommends that EU Member States should ensure the full implementation and enforcement of the Directive on Waste (Directive 2008/98/EC of the European Parliament and of the Council of

November 19, 2008), and the CED fully supports examination into whether this is happening. Recent data indicates that amalgam separators, which are an effective way of reducing harmful waste, are now used in most and obligatory in many EU countries. It is time for Ireland to move into line with its European counterparts and make the use of amalgam separators mandatory.

On the question of a phase down of amalgam use, this is a topic that has risen to the top of the agenda in Europe and one that will have to be considered in depth in this country also, and in the short to medium term. It is no longer a topic that can be deferred indefinitely.

Tooth whitening

The CED Guidelines to Interpret and Implement Council Directive 2011/84/EU on tooth whitening products provide guidance for interpreting and implementing the Council Directive 2011/84/EU of September 20, 2011, amending Directive 76/768/EEC, concerning cosmetic products, for the purpose of adapting Annex III thereto to technical progress. It intends to support CED members and observers when they contact the ministries, competent authorities, fellow dentists and the public. The Directive entered into force on November 18, 2011. Member States will have to apply the Directive provisions from October 31, 2012.

What has changed in the Directive?

The Directive regulates the use of hydrogen peroxide and other compounds or mixtures that release hydrogen peroxide in tooth-whitening or bleaching products.

The current Directive establishes a new legal framework, in that products between 0.1% and 6% of hydrogen peroxide present or released in tooth-whitening or bleaching products can now only be sold to dental practitioners and must have their first use within the dental practice, i.e., by dental practitioners (or under their direct supervision if an equivalent level of safety is ensured). The rest of the cycle of use can be performed by consumers themselves as long as the access to the product is provided by dental practitioners (or by other qualified dental professionals who are under the dental practitioner's direct supervision and responsibility if an equivalent level of safety is ensured). These concentrations cannot be used on a person under 18 years of age.

Labelling

The Directive specifies the conditions of use and warnings that must be printed on the label of tooth-whitening and bleaching products containing more than 0.1% and up to 6% of hydrogen peroxide, present or released. It requires the following:

- the indication in percentage of the concentration of hydrogen peroxide present or released;
- the warning that it cannot be used on a person under 18 years old; and,
- the warning that it can only be sold to dental practitioners, specifying that for each cycle of use the first use can only be done by dental practitioners or under their direct supervision if an

equivalent level of safety is ensured. Afterwards, the product may be provided to the consumer (by the dental practitioner) to complete the cycle of use.

Template

The Commission is very keen that data on the undesirable side effects of tooth-whitening products is gathered, and where a case occurs, related information such as the type of reaction, duration, concentration of hydrogen peroxide, form of the product, etc., is gathered.

The CED is committed to the highest level of patient safety in the use of tooth-whitening products and is keen to co-operate with the Commission. In order to fulfil this commitment, a template has been prepared for distribution among CED member countries. It will be uploaded into national dental association and chamber websites, so that their respective members are encouraged to use it. More recently, the CED Board approved the proposed way forward and requested that a template letter also be sent to CED members to allow them to inform the relevant national ministries as to why and how the CED will be collecting data about the use of tooth-whitening products.

Professional qualifications directive

CED members have reaffirmed their views on the possible changes to the Directive on the Recognition of Professional Qualifications (Directive 2005/36/EC), which is currently being considered by the European Parliament. Amendments have been drafted by the sectoral professions on the questions of partial access, language requirements, delegated acts and common training pathways.

The CED has called for defining of the minimum duration of training for dental practitioners not only in years (five years) but also in training hours (5,000 hours), to maintain a high standard of dental education in the interests of patient safety.

CED members support language checks for dentists practising in another Member State, but believe that the wording proposed by the European Commission should be simplified in order to avoid confusion. The area of language requirements has long been a contentious one and the proposed amendment by the sectoral professions is very clear on what is needed. It includes the wording: "In case of professions with public health and patient safety implications, Member States may confer to the competent authorities the right to verify the language knowledge necessary to carry out the specific role. Language verification undertaken by the competent authority does not prevent the employer from carrying out additional checks, as appropriate".

The CED supports the increased use of electronic means in recognition of professional qualifications through the IMI system, but calls for extension of the newly introduced short deadlines imposed on competent authorities, particularly in view of the suggested tacit approval of recognition if the deadline is not met. Finally, CED members are strongly opposed to the application of the principle of partial access and ask for a clear exemption for healthcare professions and professions related to public health.

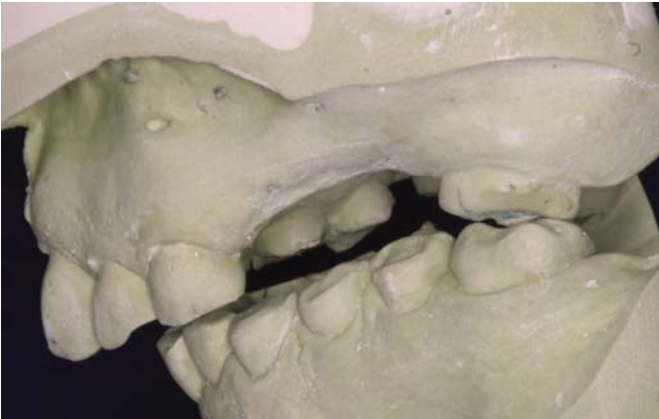


FIGURE 1: Occlusal interferences like the one shown on the left molars may be coincidentally found in bruxers but are not thought to be the cause of bruxism.

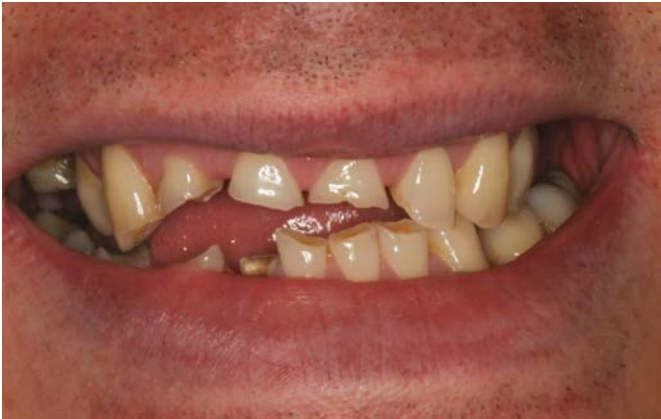

FIGURE 2: This patient had a severe, observable daytime clenching habit and reported wearing a splint almost every night for six years.

Types of bruxism

There are two main types of bruxism – wake and sleep bruxism. DR PADRAIG McAULIFFE presents an overview of their diagnosis and management.

Table 1 summarises the main characteristics of wake and sleep bruxism.

Causes of bruxism

What is the current best evidence?

The short answer to this question is that the pathogenesis of bruxism is not yet certain,¹ but is most likely associated with sleep arousals or disturbances in the sleep pattern.² These arousals happen normally in most people but only lead to bruxism in some.³ This relatively new understanding of the role of sleep in the aetiology of bruxism has led most authorities to consider it a sleep-related movement disorder rather than a dental condition.⁴

Can abnormal occlusion cause sleep bruxism?

While it is a commonly held view that there is a link between bruxism and occlusion, the evidence behind this claim is actually very weak.^{5,6}

TYPES OF BRUXISM	
WAKE/DAYTIME BRUXISM	SLEEP/NOCTURNAL BRUXISM
20% of the population	8-20% of the population
Mostly vertical clenching	Mostly lateral grinding
Strongly stress related	Related to sleep arousal
Managed by patient education	Managed by occlusal splints

Logically, the fact that occlusal interferences occur in about 90% of the population, but only 8-20% have bruxism, makes it highly unlikely that there is a direct and strong cause and effect relationship (**Figure 1**). As a result, the practice of occlusal adjustment or equilibration as a treatment for bruxism is not supported by evidence and has been discredited by most experts in the field.

Does stress cause bruxism?

There does seem to be a link to stress, particularly for wake bruxism. The link with sleep bruxism is not completely clear yet, but research is ongoing in several centres.⁷ Treatment methods that have focused on stress reduction or management have not shown consistent or sustained improvements in bruxism severity, and the quality of this evidence is generally low.⁸

Does the patient have active bruxism?

Table 2 lists the most reliable indicators of active bruxism.

TABLE 2: Reliability of history and clinical examination as indicators of current bruxism activity	
More reliable indicators	Less reliable indicators
Grinding witnessed by bed partner	Tooth surface loss
Muscle pain and trismus in the morning	Self report
Repeated fracture of sound teeth or restorations	Soft tissue indentations
Diagnosis in a sleep study or with home monitoring technology of some kind	Bony exostoses on the buccal of the upper or lingual of lower alveolar ridges
Patient is aware of wakeful bruxism	Loss of vertical dimension

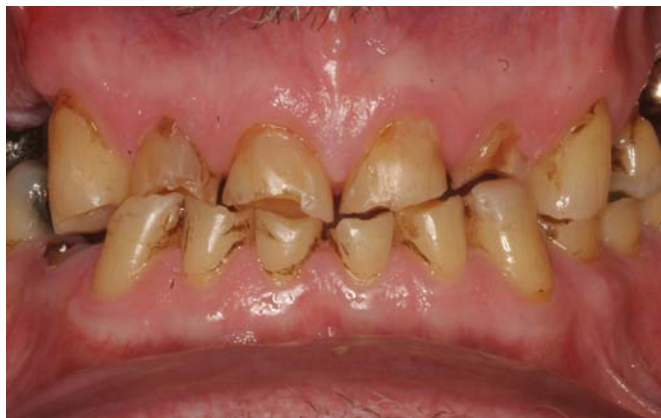

FIGURE 3: The upper and lower wear facets match closely, indicating sleep bruxism.

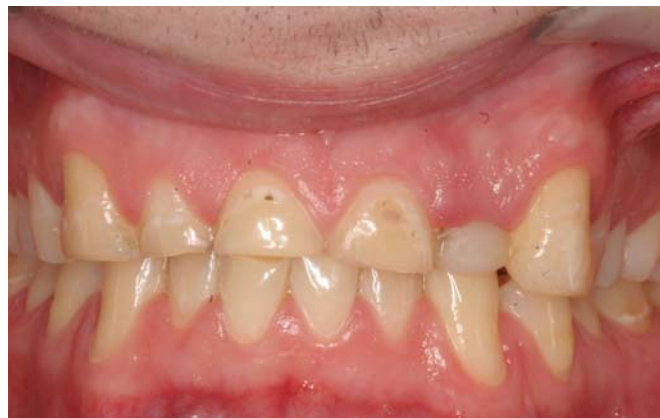

FIGURE 4: The anterior teeth are affected more than the posterior teeth.

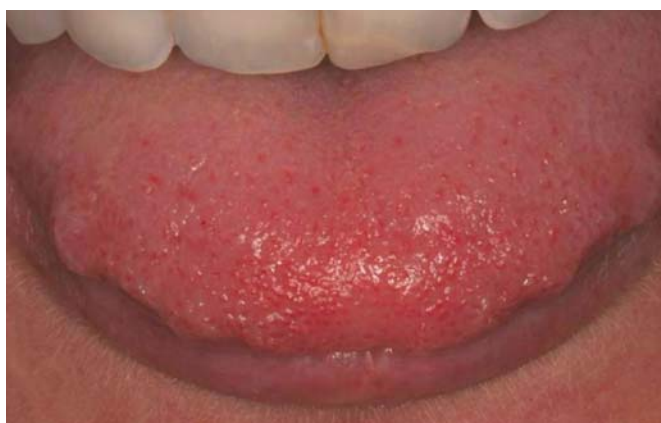

FIGURE 5: A scalloped tongue can be an indicator of clenching during sleep but the evidence is weak.

Why is tooth wear not always reliable for predicting active bruxism?

There are distinct patterns of tooth surface loss that are caused by bruxism (Figures 2, 3 and 4). However, it can be difficult to know whether bruxism is currently active or how severe it is in the early stages before damage has been done. Also, lack of wear on the teeth does not mean that bruxism is not occurring.⁹ The reasons that wear is a poor predictor of bruxism severity or current activity are:

- wear resistance of the teeth differs between people;
- salivary consistency and intra-oral pH are important and hard to measure; and,
- there are no reliable clinical ways of knowing whether the wear happened recently or is historical.

Many clinicians wonder about the use of taking serial casts to monitor the ongoing progress of bruxism and tooth wear. This has been shown to be of limited practical use. Except in cases where the wear progresses quickly or the models are taken at long intervals, the increments in wear can be difficult to detect. Other indicators of clenching during sleep have been cited, such as a scalloped tongue, but the evidence is weak (Figure 5).

Does the absence of facial pain mean that a patient is not a bruxer?

Trismus in the morning, tenderness to palpation of the masticatory muscles, and muscle discomfort on eating are all good indicators that a patient may be grinding actively. However, the absence of pain does not at all ensure the absence of bruxism. In fact, there is some evidence to suggest that the muscles of the most intense or frequent bruxers become physically 'fit', and they get less muscle pain than low frequency bruxers as a result.¹⁰

Can bruxism be stopped?

It appears that there is no reliable way to actually stop a patient from bruxing long term. Splints have been shown to reduce bruxism activity by 50-70% initially. However, in most people it returns to pre-treatment levels after only four to six weeks of splint use.¹¹⁻¹³ Bruxism activity is known to vary over time,¹⁴ but that variance cannot be predicted at present.¹⁵ Experimental studies have been done on the use of various medications (such as clonidine, clonazepam, L-dopa and propranolol) to reduce bruxism activity. No suitable and safe candidate has been identified for long-term use.

How should I manage patients with bruxism?

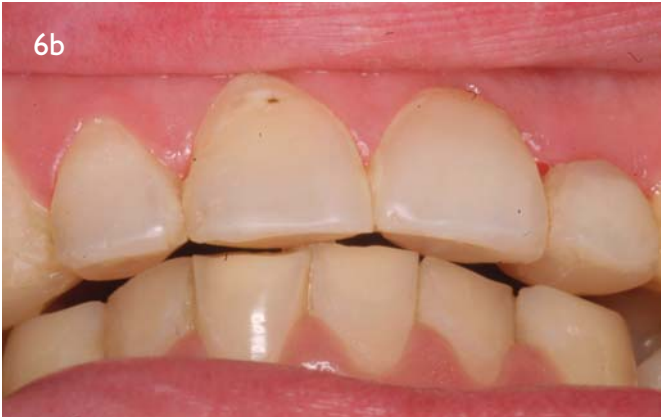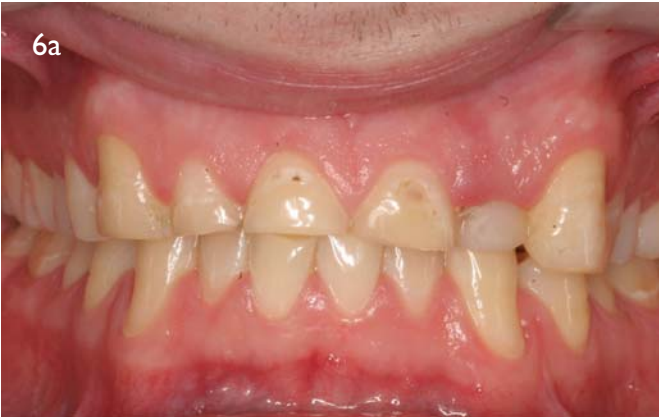Wake bruxism is generally controlled by patient education or, in rare cases, with lower occlusal splints worn during the day. Because sleep bruxism apparently cannot be stopped, we need to approach sleep bruxism patients with a risk management frame of mind. A full description of the restorative management of bruxers is beyond the scope of this fact file but some important aspects include:

Managing expectations

It is important to ensure that bruxism patients understand in advance that their restorations may not last quite as long as otherwise expected, and that they have a major role to play in preventing premature failure of restorations by using a splint.

Splints – for how long, which type and how to make a good one

Where the presenting complaint relates to damage to the teeth, it is



FIGURES 6a-d: This patient had wear on the anterior teeth only and had limited resources. A Dahl approach was used to create space for anterior crowns. The posterior teeth did not require restoration.

logically more likely that the bruxism has been longstanding and intense, so the splint should be used indefinitely. If the presenting complaint is of recent morning facial pain only and there is no damage to the teeth, then the splint use can usually be stopped once the symptoms have resolved. Where the pain persists for longer than a few weeks, referral to a facial pain specialist is important to avoid the risk of a chronic pain problem. Soft splints are rarely recommended for either case, as they have been shown to increase bruxism activity in

approximately 50% of patients and will be quickly perforated by heavy bruxism activity.¹⁶ Hard acrylic splints or thermoformed hard-soft splints are a better choice.

Hard acrylic splints can be very frustrating and time consuming to fit. There are, however, some things that can be done to make this a more predictable procedure. As splints are essentially hard prostheses supported by hard tooth tissue, a silicone impression with medium body or putty and wash is more appropriate, as it makes a more dimensionally accurate cast. This is particularly the case where there is no facility in the practice to immediately pour an alginate impression. To avoid excessive occlusal adjustments in the second molar region, a hard wax record in centric relation should also be taken. The splint should be at least 1.5-2mm thick in the molar region to avoid perforation or fracture in heavy bruxists. It is almost always better to ask for a flat plane splint instead of one with occlusal indentations. Anterior ramps are added by some practitioners to exclude the posterior teeth, but these have not been proven to be necessary or superior. **Table 3** shows options for restoration materials in cases of bruxism.

TABLE 3: Material selection	
Opposing materials	<ul style="list-style-type: none">▶ Material/substance of opposing teeth should have similar wear rates and be highly polished. Hard, wear-resistant materials, particularly if rough, greatly accelerate the wear of opposing softer materials.▶ The order of hardness of common materials is as follows: cobalt chrome > porcelain > gold (similar to enamel) > amalgam > composite.
All ceramics	<ul style="list-style-type: none">▶ Caution with multiple units in severe bruxers.▶ Use high strength ceramics, e.g., Procera alumina, in preference to feldspathic porcelain.▶ Very important to highly polish or reglaze adjusted areas.
Cements	<ul style="list-style-type: none">▶ Do not over-rely on cements for retention on short preps. Consider elective endodontics, post and core, or crown lengthening to improve preparation resistance form first.▶ Resin cements are best on short preparations that cannot be improved.▶ Polycarboxylate cements for provisional crowns.
Temporary crown materials	<ul style="list-style-type: none">▶ Choose materials based on the duration of time you expect they will be needed, e.g., bis-acryl materials will not last six months in heavy bruxers.▶ Consider preformed polycarbonates for anterior teeth, e.g., Directa crown forms.
Composites	<ul style="list-style-type: none">▶ Do not rely on composites holding cracked teeth together.▶ Avoid having occlusal contacts at the tooth restoration margins.▶ Try to avoid using composite for the long term on teeth involved in excursive guidance.

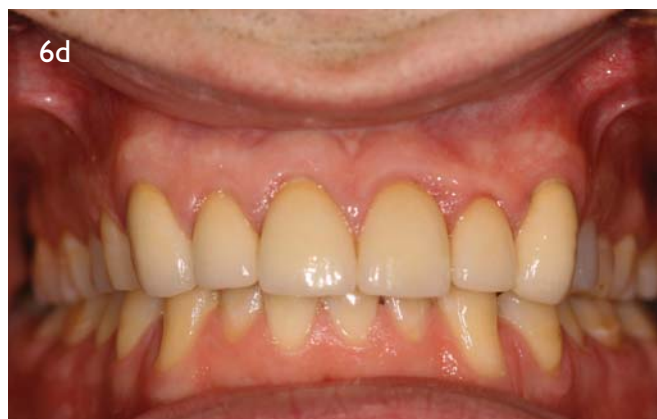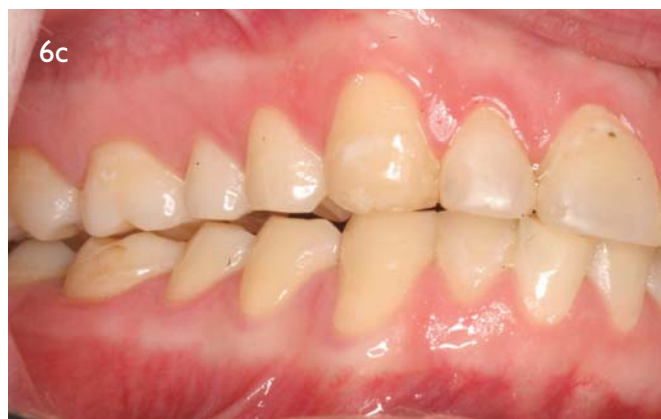Timing of intervention

Obviously, the earlier the intervention the less complex the eventual solution has to be. There are a few warning signs to indicate that a patient is a bruxer:

- wear facets on the upper and lower teeth match in excursive movements;
- maxillary incisors are all the same length with flat broad incisal edges;
- there are flat shiny areas on the cusps of posterior teeth; and,
- there is a significant number of fracture lines around small posterior fillings.

Where the wear is diagnosed early and is limited to the anterior teeth only, a Dahl approach can sometimes be appropriate, as shown in **Figures 6a, b, c and d**.

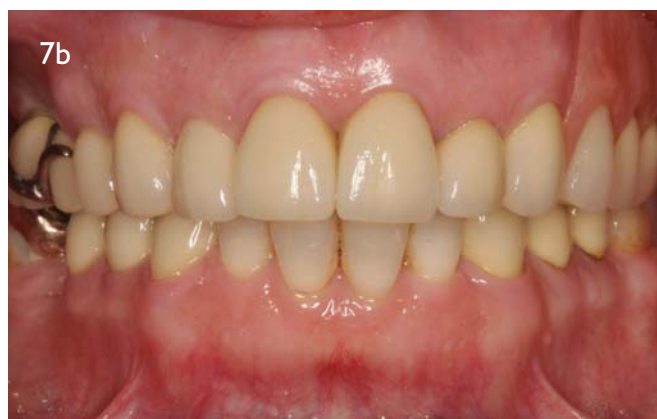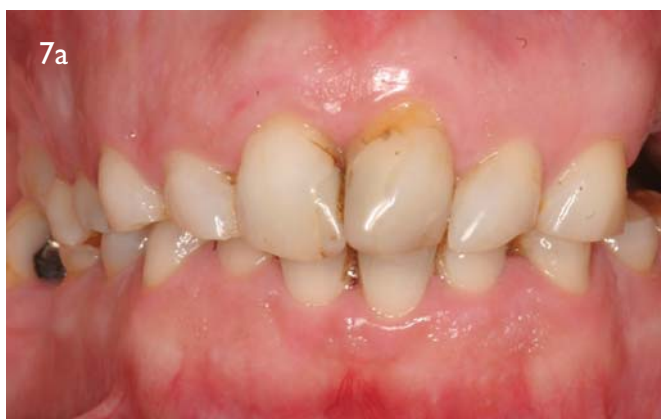Once the posterior teeth have lost cuspal anatomy to the point where there is no longer a clear maximal intercuspal position and dentine is exposed, restoration can become much more complex. At this point, protection of the teeth from further destruction and the re-



establishment of a stable occlusion commonly involve a complex prosthodontic reconstruction, as shown in **Figures 7a and b**.

References

1. **Lobbezoo, F.J., Van Der Zaag, J., Naeije, M.** Bruxism: its multiple causes and its effects on dental implants – an updated review. *J Oral Rehabil* 2006; 33 (4): 293-300.
2. **Kato, T., et al.** Evidence that experimentally induced sleep bruxism is a consequence of transient arousal. *J Dent Res* 2003; 82 (4): 284-288.
3. **Macaluso, G.M., et al.** Sleep bruxism is a disorder related to periodic arousals during sleep. *J Dent Res* 1998; 77 (4): 565-573.
4. **Kato, T., et al.** Topical review: sleep bruxism and the role of peripheral sensory influences. *J Orofac Pain* 2003; 17 (3): 191-213.
5. **Clark, G.T., et al.** Sixty-eight years of experimental occlusal interference studies: what have we learned? *J Prosthet Dent* 1999; 82 (6): 704-713.
6. **Magnusson, T., Enbom, L.** Signs and symptoms of mandibular dysfunction after introduction of experimental balancing-side interferences. *Acta Odontol Scand* 1984; 42 (3): 129-135.
7. **Kato, T., et al.** Bruxism and orofacial movements during sleep. *Dent Clin North Am* 2001; 45 (4): 657-684.
8. **Lobbezoo, F., et al.** Principles for the management of bruxism. *J Oral Rehabil* 2008; 35 (7): 509-523.
9. **Abe, S., et al.** Tooth wear in young subjects: a discriminator between sleep bruxers and controls? *Int J Prosthodont* 2009; 22 (4): 342-350.
10. **Rompere, P.H., et al.** Identification of a sleep bruxism subgroup with a higher risk of pain. *J Dent Res* 2007; 86 (9): 837-842.
11. **van der Zaag, J., et al.** Controlled assessment of the efficacy of occlusal stabilisation splints on sleep bruxism. *J Orofac Pain* 2005; 19 (2): 151-158.
12. **Harada, T., et al.** The effect of oral splint devices on sleep bruxism: a six-week observation with an ambulatory electromyographic recording device. *J Oral Rehabil* 2006; 33 (7): 482-488.
13. **Dube, C., et al.** Quantitative polygraphic controlled study on efficacy and safety of oral splint devices in tooth-grinding subjects. *J Dent Res* 2004; 83 (5): 398-403.
14. **Lavigne, G.J., et al.** Variability in sleep bruxism activity over time. *J Sleep Res* 2001; 10 (3): 237-244.
15. **Carlsson, G.E., Egermark, I., Magnusson, T.** Predictors of signs and symptoms of temporomandibular disorders: a 20-year follow-up study from childhood to adulthood. *Acta Odontol Scand* 2002; 60 (3): 180-185.
16. **Okeson, J.P.** The effects of hard and soft occlusal splints on nocturnal bruxism. *J Am Dent Assoc* 1987; 114 (6): 788-791.



FIGURES 7a and b: This patient had wear of anterior and posterior teeth with significant occlusal issues. A full mouth reconstruction was required.

Hierarchical decisions on teeth vs. implants in the periodontitis-susceptible patient: the modern dilemma

Donos, N., Laurell, L., Mardas, N.

It is estimated that advanced periodontitis typically affects about 10% of most adult populations studied. These individuals can be considered highly susceptible to periodontitis and often present difficulties for clinicians in therapeutic decision making, especially when dental implants are involved. Poor plaque control and smoking are well-established risk factors for periodontitis, as well as for peri-implant disease. Long-term follow-up studies have clearly demonstrated that treatment of periodontal disease, even if disease is advanced, can be successful in arresting disease progression and preventing (or at least significantly delaying) tooth loss. With the increasing development of implant dentistry, traditional well-documented and evidence-based therapies to treat periodontal diseases may sometimes not be used to their full potential. Instead, there appears to be an increasing tendency to extract periodontally compromised teeth and replace them with implants, as if implants can solve the problem. However, peri-implant diseases are prevalent, affecting between 28% and 56% of people with implants, and (at the implant level) 12-43% of implants. A history of periodontal disease, smoking and poor oral hygiene, are all risk factors for developing peri-implantitis. Unlike periodontitis, there are currently no predictable means for treating peri-implantitis, although resective surgery seems to be the most effective technique. Consequently, if implant treatment is considered in patients who are susceptible to periodontitis, it should be preceded by appropriate and adequate periodontal treatment or re-treatment to control the condition, and should be followed by a stringent supportive maintenance programme to prevent the development of peri-implant disease. The decision whether implant treatment should be performed should be based on an assessment of the patient's risk profile at the subject level, as well as at the site level.

Periodontology 2000 2012; 59 (1): 89-110.

EAO guidelines for the use of diagnostic imaging in implant dentistry 2011. A consensus workshop organised by the European Association for Osseointegration at the Medical University of Warsaw

Harris, D., Horner, K., Gröndahl, K., Jacobs, R., Helmrot, E., Benic, G.I., et al.

Diagnostic imaging is an essential component of patient selection and treatment planning in oral rehabilitation by means of osseointegrated implants. In 2002, the EAO produced and published guidelines on the use of diagnostic imaging in implant dentistry. Since that time, there have been significant developments in both the application of cone beam computed tomography and in the range of surgical and

prosthetic applications that can potentially benefit from its use. However, medical exposure to ionising radiation must always be justified and result in a net benefit to the patient. The 'as low a dose as is reasonably achievable' principle must also be applied, taking into account any alternative techniques that might achieve the same objectives. This paper reports on current EAO recommendations arising from a consensus meeting held at the Medical University of Warsaw (2011) to update these guidelines. Radiological considerations are detailed, including justification and optimisation, with a special emphasis on the obligations that arise for those who prescribe or undertake such investigations. The paper pays special attention to clinical indications and radiographic diagnostic considerations, as well as to future developments and trends.

Clinical Oral Implants Research (Online) 2012.

Cuspal deflection and microleakage in premolar teeth restored with bulk-fill flowable resin-based composite base materials

Moorthy, A., Hogg, C.H., Dowling, A.H., Grufferty, B.F., Benetti, A.R., Fleming, G.J.

Objectives: To assess the cuspal deflection and cervical microleakage of standardised Class II cavities incrementally filled with a dimethacrylate resin-based composite (RBC) or bulk-fill flowable RBC bases.

Methods: Twenty-four sound upper premolar teeth with Class II cavities were allocated to three groups (n=8). Restoration of the teeth involved the placement of an RBC (GrandioSO) in eight oblique increments in Group A, and Groups B and C were restored to within 2mm of the palatal cusp in a single increment with bulk-fill flowable RBC bases (SDR and x-tra base) before the two occlusal cavity increments were placed with GrandioSO. Buccal and palatal cusp deflections were recorded post irradiation using a twin-channel deflection-measuring gauge. Following restoration, the teeth were thermocycled, immersed in 0.2% basic fuchsin dye for 24 hours, sectioned and examined for cervical microleakage.

Results: The mean total cuspal deflection for the oblique incremental restoration technique was 11.26 (2.56) μm (Group A), 4.63 (1.19) μm (Group B), and 4.73 (0.99) μm (Group C) for the bulk-fill flowable RBC bases. A significant increase in the mean total cuspal deflection for the incrementally filled GrandioSO compared with the SDR- ($p=0.007$) and x-tra base- ($p=0.005$) restored teeth was evident. No significant difference in the cervical microleakage scores was recorded between groups A and C ($p>0.05$).

Conclusions: The bulk-fill flowable RBC bases significantly reduced cuspal deflection compared with a conventional RBC restored in an oblique incremental filling technique with no associated change in cervical microleakage recorded.

J Dent 2012; 40 (6): 500-505.

Changes in centring and shaping ability using three nickel–titanium instrumentation techniques analysed by micro-computed tomography (μCT)

Stern, S., Patel, S., Foschi, F., Sherriff, M., Mannocci, F.

Aim: To compare the centring ability and the shaping ability of ProTaper (PT) files used in reciprocating motion and PT and Twisted Files (TF) used in continuous rotary motion, and to compare the volume changes obtained with the different instrumentation techniques using micro-computed tomography.

Methodology: Sixty mesial canals of 30 mandibular molars were randomly assigned to three instrumentation techniques: group 1, canals prepared with the PT series (up to F2) (n=20); group 2, canals prepared with the F2 PT in reciprocating motion (n=20); and, group 3, canals prepared with the TF series (size 25) (n=20). Teeth were

scanned pre- and postoperatively using micro-computed tomography to measure volume and shaping changes, and the obtained results were statistically analysed using parametric tests.

Results: The increase in canal volume obtained with the three instrumentation techniques was not significantly different. Canals were transported mostly towards the mesial aspect in the apical and mid-third of the roots, and towards the furcal aspect coronally. No difference in the transportation and centring ratio was found between the techniques. There was no significant difference between the times of instrumentation (TF: 62.5 ± 5.4 s; PT: 60.6 ± 3.9 s; and, F2 PT file in reciprocating motion: 51.0 ± 3.3 s).

Conclusions: PT files used in reciprocating motion, and PT and TF used in continuous rotary motion, were capable of producing centred preparations with no substantial procedural errors.

International Endodontic Journal 2012; 45 (6): 514-523.

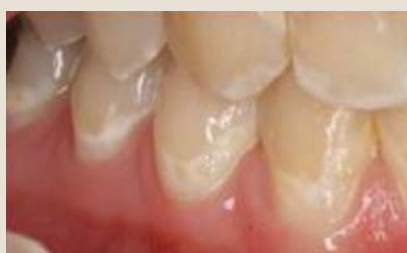

Figure 1.

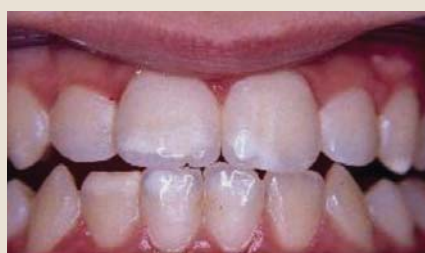

Figure 2.

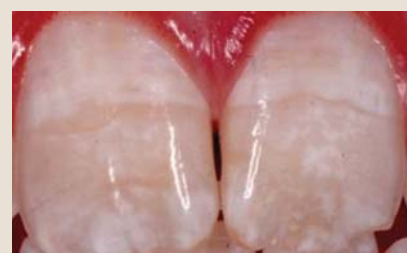

Figure 3.

Quiz answers

(questions on page 130)

1. **Figure 1** is a white spot lesion. White spot lesions are the early signs of tooth decay. These are initial caries lesions that induce a loss of mineral, while the surface layer remains intact. This is demineralisation and is reversible at this stage. It does not require any immediate restorative treatment. The combined application of chlorhexidine and fluoride varnishes is shown to be effective for remineralisation. Dietary advice is a key component of this treatment.

Figure 2 is molar-incisor hypomineralisation (MIH). MIH is a developmental condition resulting in enamel defects in the first permanent molars and permanent incisors. Early diagnosis is essential to prevent acute symptoms. It can be caused by a number of factors, including perinatal conditions, high fever diseases, hypoxia, etc. These teeth may be sensitive to thermal and mechanical stimuli. It is recommended that preventive measures are utilised, such as fluoride varnish and fissure sealing. Treatment can become more complicated depending on the severity of the condition, and composites or crowns may be required. The condition does not always require treatment and should be monitored.

Figure 3 is moderate fluorosis. Fluorosis can occur due to excessive fluoride reaching the developing tooth during enamel formation. This can occur due to early and frequent brushing with fluoride toothpaste, ingestion of fluoride toothpaste and the inappropriate use of fluoride supplementation. Simple techniques can be used to treat these areas such as whitening and micro-abrasion. Severe fluorosis can be treated with composite veneers, crowns and veneers as the individual case may indicate. However, severe fluorosis is uncommon in Ireland.

2. Immediate restorative treatment is not indicated in any of these opacities. White spot lesions do not indicate decay: at this point the effects can be reversible. MIH requires preventive attention, but treatment should be conservative. Fluorosis is considered a cosmetic condition, so treatment will be aesthetic in nature only.
3. The odd one out is fluorosis. MIH and white spot lesions require preventive attention and monitoring. Fluorosis occurs at the development stage, so the opacity will not worsen if left untreated.



SENSODYNE



IDA

journal of the irish dental association
Iris Cumainn Déadach na hÉireann



COULD YOU BE THE SENSODYNE Sensitive Dentist of the Year™?

The search for the 2012 Sensodyne Sensitive Dentist of the Year has begun.

This awards programme is dedicated to showcasing the marvellous work of Irish dentists
– and all through the words that mean most: those of your patients.

Patients have come forward, through this programme, in huge numbers to commend their dentists for the
care and professionalism with which they have been treated.

To register for a competition pack, fill in the postcard on the dedicated wraparound
on the cover of this issue and return it via Freepost. We will send you the necessary details and information
and your patients will have until November 30 this year to make their nominations.



Lingual orthodontics: an illustrated review with the incognito fully customised appliance

Journal of the Irish Dental Association 2012; 58 (3): 149-155.

Introduction

One of the major challenges in orthodontics is to achieve an excellent result with appliances that are both aesthetic and comfortable. There is currently enormous interest in so-called 'invisible orthodontics'; this has been contributed to by the intensive marketing campaigns run by the manufacturers of various removable clear aligner systems. However, the available research tells us that the mean accuracy of tooth movement with Invisalign is only 41%.¹ Aligner systems, because of their inherent biomechanical limitations, can only accomplish certain types of tooth movement. Their role is therefore limited to the correction of specific malocclusions.

In this article the author will describe how lingual orthodontics has evolved and how many of the problems originally associated with the lingual technique have been minimised. The manufacture of one type of fully customised lingual appliance, namely the 'incognito appliance', will be described, and the lingual technique will be illustrated with two treated cases.

Lingual orthodontics

Lingual orthodontics as we understand it today (a full multi-bracket appliance, e.g., **Figures 1** and **2**) began in the 1970s. A Japanese orthodontist, Dr Kinja Fujita,² developed the appliance, not primarily for aesthetic reasons but rather to protect the soft tissues (lips and cheeks) of his orthodontic patients who practised martial arts. Independently, in the USA, Dr Craven Kurz worked to develop a lingual appliance at this time.^{3,4} The first lingual appliances used standard labial brackets, which were modified by the clinician and bonded to the teeth using a direct technique, the same

technique as is employed to bond labial brackets. Lingual orthodontics achieved a certain amount of popularity in the 1980s; however, its popularity soon decreased due to clinical difficulties associated with the technique.

There has been an enormous resurgence of interest in lingual orthodontics in the last ten years. This can be accounted for by two factors: the invention of the incognito lingual appliance; and, the increase in the number of adults seeking orthodontic treatment. This appliance has now been used worldwide to treat over 30,000 cases. It has succeeded in minimising the traditional problems associated with lingual orthodontics. Recent research would suggest that it is an effective appliance, which can achieve the objectives of the orthodontic treatment plan.⁵

Orthodontic treatment should not be commenced, or indeed continued, in the presence of inadequate oral hygiene, or when the patient has unsatisfactory dietary habits. However, decalcification remains a significant risk in labial orthodontics.^{6,7} Lingual orthodontics has the advantage that split mouth studies have shown that the incidence of decalcification is one-quarter of that associated with labial orthodontics, and when decalcification does occur it is one-tenth as severe as the decalcification seen in labial orthodontics.⁸ In addition, the decalcification is not of aesthetic importance, as it is on the lingual surface of the teeth. The reduced risk of decalcification is a significant advantage when treating teenagers, although, of course, the practitioner must endeavour to ensure that excellent oral hygiene and dietary habits are maintained throughout the course of orthodontic treatment.

**Dr John Buckley BDS FDS
MOrth MScD MDO FFD**
Riverhouse Orthodontic Practice,
Riverhouse,
New Quay
Clonmel
Co. Tipperary

T: 087-248 5663
E: admin@clonmelorthodontics.ie

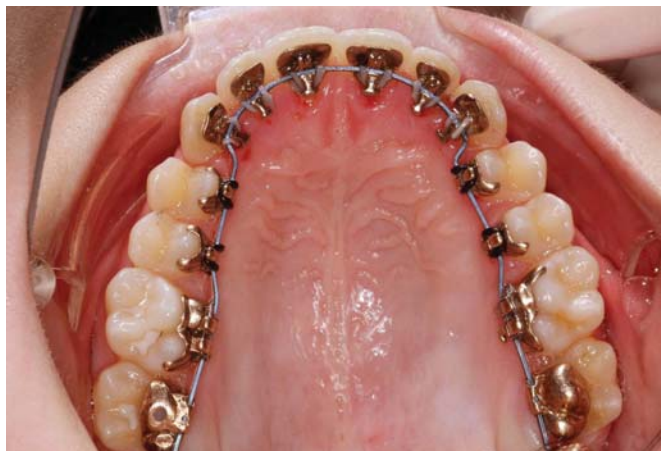

FIGURE 1: Contemporary upper lingual appliance.

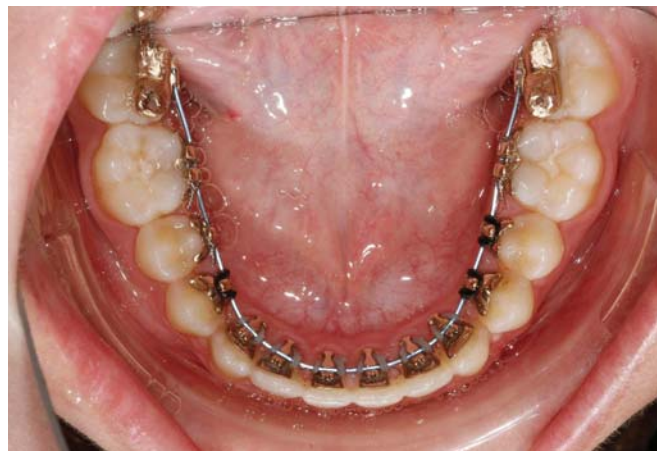

FIGURE 2: Contemporary lower lingual appliance.



FIGURES 3a and 3b: Two-phase polyvinyl siloxane impressions are taken to produce accurate models of the patient's teeth. (Figures 3-12 inclusive courtesy of 3M Unitek; Monrovia, California, USA).



The incognito lingual appliance

Lingual orthodontics has advanced to a highly sophisticated level where CAD/CAM (computer-aided design/computer-aided manufacture) technology is employed to manufacture both the brackets and arch wires for each patient individually in the incognito appliance system. The incognito lingual appliance system is used to treat both teenagers and adults. It can be used in combination with functional appliances like the Herbst appliance, and 'bite jumpers' like the Forsus appliance. It can be used without difficulty in the management of orthodontic patients who require orthognathic surgery.

Fabrication of the incognito lingual appliance

Bracket fabrication

Two-phase polyvinyl siloxane impressions are taken to produce accurate models of the patient's teeth (Figure 3). The plaster models are used to prepare an individualised therapeutic target set-up that is created by cutting between the teeth and setting them up to the desired target position in wax.

The target set-up is constructed from the plaster teeth set-up to the desired position in wax. A high-resolution optical 3D scanner permits non-contact scanning of the therapeutic target set-up. The scan produces a three-dimensional digital representation of the teeth consisting of many thousands of minute triangles that can be documented and processed in the computer (Figure 4).

Specialised CAD/CAM software is used to design and build customised brackets and bases (Figure 5). Because of the extreme accuracy of the scan, the bases mould precisely to the teeth (Figure 6). Large pad surfaces provide greater bond strength and make them easy to place on the teeth for bonding and re-bonding.

Wax patterns of the virtual customised brackets are created using rapid prototyping wax printers (Figure 7). The patterns are then placed in an investment cast, burned out and a dental gold alloy is poured into the cast to create the brackets (Figure 8). After casting, the brackets are tumbled and polished until they are smooth to ensure high patient comfort. They are then positioned on the original malocclusion model (Figure 9).

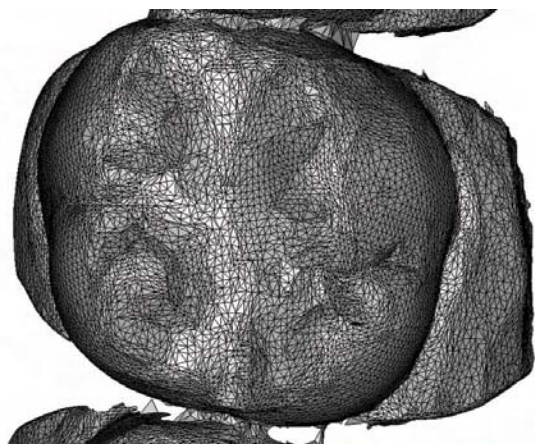


FIGURE 4: 3D digital representation of a tooth from the target set-up.




FIGURE 5: The virtual brackets conform exactly to the individual patient's dental morphology.

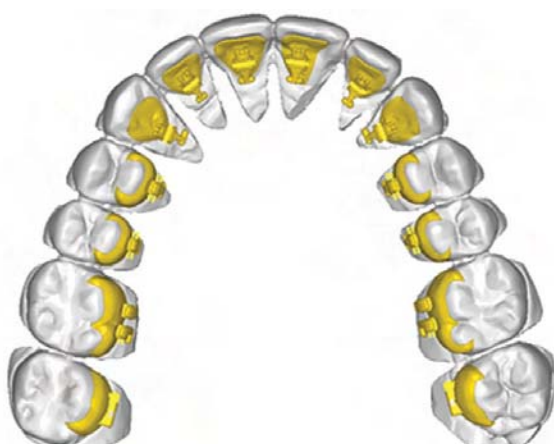

FIGURE 6: Complete set of virtual brackets constructed for an individual's maxillary arch.

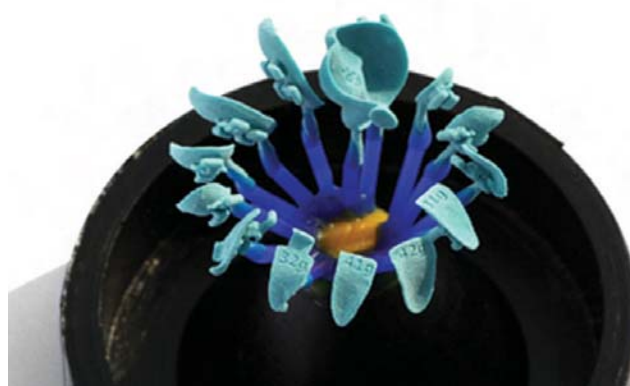


FIGURE 7: The virtual brackets are now a reality in wax (wax patterns) prior to casting.



FIGURE 8: The final brackets after investment casting.

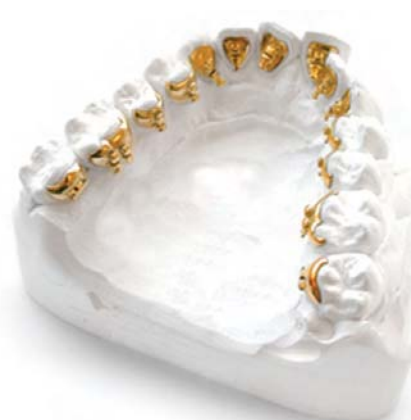

FIGURE 9: The polished gold brackets are placed on the original malocclusion model.

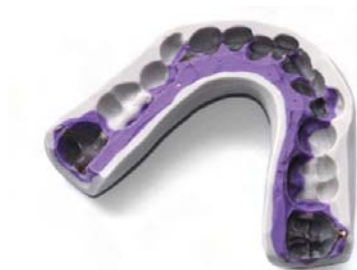

FIGURE 10: An indirect bonding tray containing the brackets. (The fitting surfaces of the lingual brackets are a dark colour due to the application of bonding materials.)

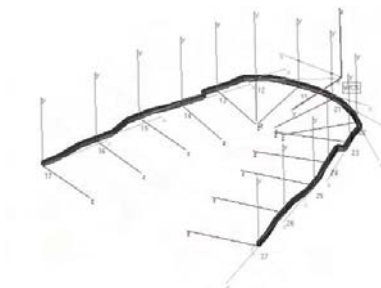


FIGURE 11: Computer-designed wire to match the target set-up.



FIGURE 12: Robot bending the arch wire to patient's individual prescription.

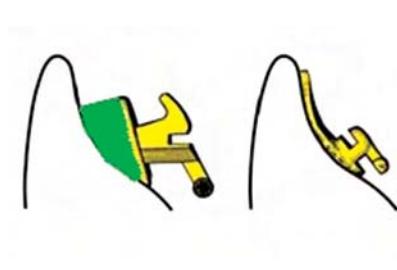


FIGURE 13: Comparison of a conventional lingual bracket (left) with an incognito bracket (right) shows a pronounced difference in size. (Figure courtesy of Dr D Wiechmann, Bad Essen, Germany.)

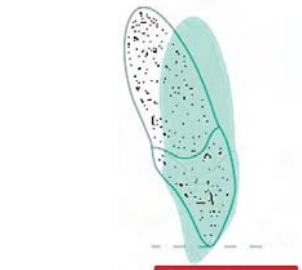

FIGURE 15: Incorrect torque will cause vertical discrepancies in the position of the incisal edges. (Figure courtesy of Dr D Wiechmann, Bad Essen, Germany.)

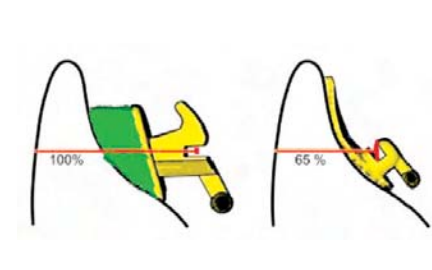


FIGURE 16: In the incognito bracket system (right), because the arch wire is closer to the labial surface of the tooth, an incorrect torque will have a lesser effect, especially on the vertical dimension.⁸ (Figure courtesy of Dr D Wiechmann, Bad Essen, Germany.)

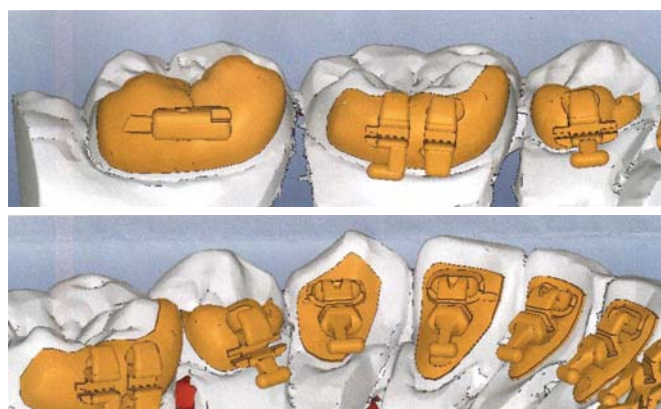


FIGURE 14: Screen shots of the 3D representation of the positioned brackets from various angles (as above) serves as an additional rebonding aid.

The brackets are transferred to the patient's mouth using an indirect bonding technique. This involves constructing an indirect bonding tray, which contains the brackets (**Figure 10**). This is constructed over the brackets, which are set up on the original malocclusion model, as in **Figure 9**. All the brackets in one tray are bonded simultaneously to the palatal surfaces of the teeth in one arch using the acid etch bonding technique, as in **Figures 1** and **2**.

It takes approximately three to six weeks from the time of impression taking until the finished appliance is delivered to the practitioner. The laboratory costs for the incognito appliance are significant, with a standard upper and lower fixed appliance costing the practitioner approximately €2,000.

Wire fabrication

The wire geometry is calculated by the CAD/CAM program (Figure 11) and then sent to a machine for fabrication (Figure 12). Each wire in the sequence has the same geometry targeted to the final position of the teeth.

Problems

Originally, there were three main problems associated with the lingual orthodontics technique:

1. Patient difficulties during the adaptation stage.
2. Difficulties with exact rebonding in the event of bracket loss.
3. Exact finishing.⁹

The incognito appliance has largely overcome these problems.

Patient difficulties during the adaptation stage

During the initial adaptation stage, immediately after the appliances are fitted, patients may experience three main problems: speech disturbances; irritation of the tongue; and, masticatory difficulties.¹⁰ Most patients report a decline in these symptoms in the first two to four weeks of treatment, though a few are affected for a longer period.¹¹⁻¹³ At the initial consultation, it is important to explain to patients about these three potential problems and to explain that there is an adaptation phase. In general, in adults only one arch is bonded initially (normally the lower) and then the other arch is bonded a few weeks later when the patient has had a chance to adapt. Once patients are aware that there is an adaptation phase this provides reassurance during the period immediately after the appliances have been fitted. In general, with teenagers both arches are bonded at the same time, as they adapt very quickly to the appliances.

The incognito lingual bracket system uses custom-made brackets, which are much thinner than the conventional brackets used in previous lingual orthodontic appliances. The lower profile of the incognito brackets causes significantly less severe symptoms during the adaptation phase, and shortens the period of adaptation (Figure 13).^{9,14}

Difficulties with exact rebonding in the event of bracket loss

The debond rate of the incognito lingual bracket is very low and comparable to labial appliances.¹⁵ The extensive individualised base of the incognito lingual bracket, which covers much of the tooth surface (significantly more than for a labial bracket on the same tooth), allows each bracket to be directly bonded. This means that a bracket can be directly rebonded accurately without the additional support of positioning aids such as small silicone trays. The fact that the base of the bracket is made to precisely fit the lingual surface of the tooth results in a positive lock when the bracket is pressed onto the tooth; this greatly facilitates accurate repositioning of the debonded bracket. In addition, where the teeth have less pronounced morphology, as found in particular on the lingual surfaces of the lower incisors, accurate rebonding of the lingual brackets is facilitated by means of 'screen shots' (Figure 14) from the manufacturing process, which are routinely supplied with each case.

Exact finishing

Before the development of the incognito lingual appliance, finishing and detailing of the occlusion was a major problem in lingual orthodontics. Three factors originally contributed to problems in the finishing phase of lingual orthodontic treatment:¹⁶

1. Inaccurate bracket positioning.
2. Inaccurate arch wire fabrication.¹⁷
3. Inaccurate fit between brackets and arch wires (torque play).

Inaccurate bracket positioning

The virtual production of the brackets on the computer almost completely eliminates errors in the actual production of the bracket bases. By using the extended bases (positive lock) and the screen shots (Figure 14), positioning the brackets on the individual teeth is relatively easy, with little room for error.

Inaccurate arch wire fabrication

All of the arch wires in the incognito system are produced with CAD/CAM technology; because of this, inaccurate arch wire fabrication is of minor significance. This has helped to simplify finishing with lingual orthodontics.

Inaccurate fit between brackets and arch wires (torque play)

Torque play in lingual orthodontics contributed to substantial difficulty in finishing cases in the past. This is because before the development of the incognito appliance, the arch wires used tended to be smaller and the slots noticeably larger than the given values; these two factors alone contributed to significant torque play.^{18,19}

Incorrect torque will affect the vertical position of the incisal edges of the teeth (Figure 15). Stamm *et al.* have shown that a 10-degree discrepancy in torque will cause a vertical discrepancy of 1.2mm in the incisal edge.²⁰ The incognito bracket is manufactured to a much higher degree of accuracy than other available lingual brackets.^{18,19}

The combined effect of accurate bracket slot production and proximity of the bracket slot to the labial surface of the tooth means that the incognito appliance has largely overcome the problems traditionally associated with torque when finishing lingual orthodontic cases (Figure 16).⁹

Examples of patients treated with the incognito appliance:

Patient 1

A 20-year-old male presented with a mild Class II Division II type malocclusion. He was treated with an upper and lower incognito appliance and class II intermaxillary elastics (Figures 17-20).

Patient 2

A 43-year-old female with a Class II Division I malocclusion. She was treated with the extraction of the upper left first premolar and upper and lower incognito lingual appliances (Figures 21-24).

Conclusion

Lingual orthodontics has evolved progressively since the 1970s. Technological developments mean that lingual orthodontics is now far more acceptable to the patient, as discomfort and interference with speech and mastication have been minimised. Although lingual orthodontics is more difficult than labial orthodontics to perform, it can achieve a high standard of orthodontic result comparable to labial orthodontics when properly applied.⁵ It is, like labial orthodontics, dependent on patient compliance. The laboratory costs associated with the production of the incognito appliance are high, although it is likely that with increasing competition from other orthodontic manufacturers, the cost of appliances will be reduced in the future.

Acknowledgements

The author is currently completing an MSc in lingual orthodontics in the Hannover Dental Hospital (Medizinische Hochschule Hannover) in Germany. The author would like to acknowledge that Professor R Schwestka-Polly and Dr Dirk Wiechmann of the Department of Orthodontics In Hannover Dental Hospital (Medizinische Hochschule Hannover), Germany, supervised the treatment of the two cases presented.

The author wishes to confirm that he has no competing interests.

References

1. Kravitz, N., Kusnoto, B., BeGole, E., Obrez, A., Agrane B. How well does Invisalign work? A prospective clinical study evaluating the efficacy of tooth movement with Invisalign. *Am J Orthod Dentofacial Orthop* 2009; 135: 27-35.
2. Fujita, K. New orthodontic treatment with lingual bracket and mushroom archwire appliance. *Am J Orthod Dentofacial Orthop* 1979; 76: 657-675.
3. Alexander, C., Alexander, R., Gorman, J., Hilgers, J., Kurz, C., Scholz, R., et al. Lingual orthodontics: a status report, Part 1. *J Clin Orthod* 1982; 16: 255-262.
4. Kurz, C., Swartz, M., Andrieko, C. Lingual orthodontics: a status report, Part 2: Research and Development. *J Clin Orthod* 1982; 16: 735-740.
5. Grauer, D., Proffit, W. Accuracy in tooth positioning with a fully customised lingual orthodontic appliance. *Am J Orthod Dentofacial Orthop* 2011; 140: 433-443.

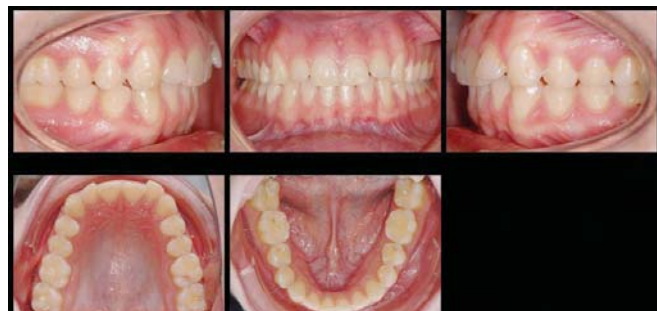

FIGURE 17: Patient 1 pre treatment.

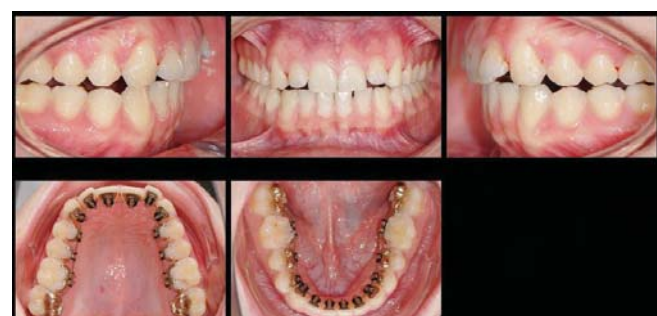

FIGURE 18: Patient 1 in treatment.

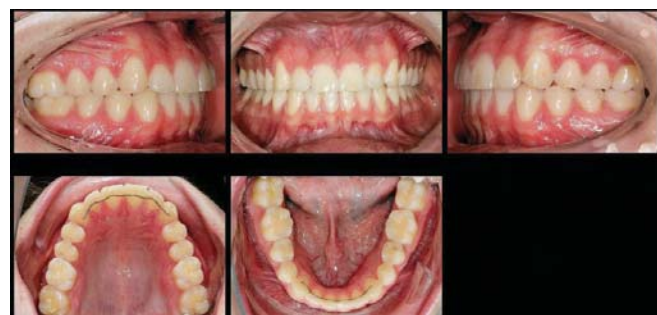

FIGURE 19: Patient 1 post treatment.

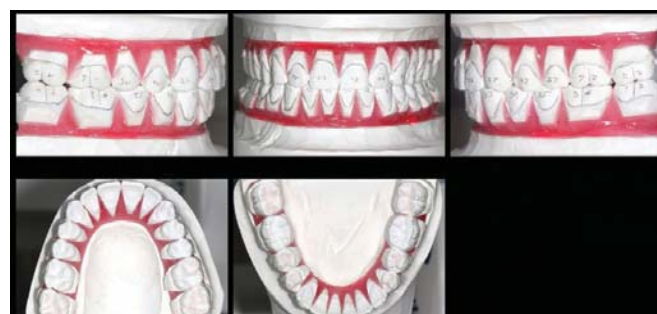

FIGURE 20: Patient 1 – original target set-up used to make the patient's incognito appliance. The post-treatment result achieved is very similar to the target set-up.

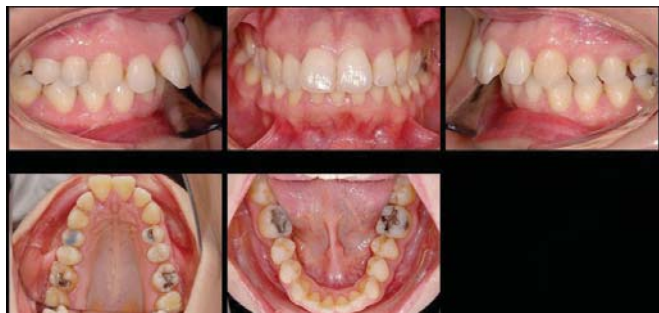

FIGURE 21: Patient 2 pre treatment.

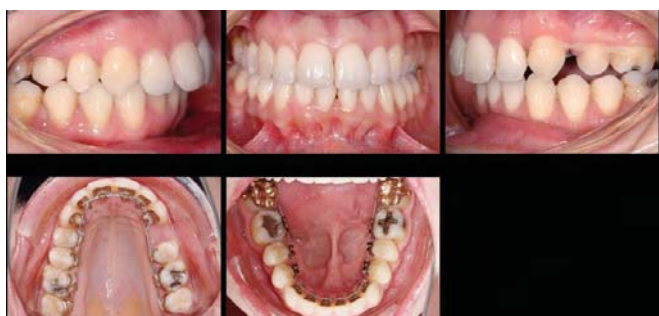

FIGURE 22: Patient 2 in treatment.

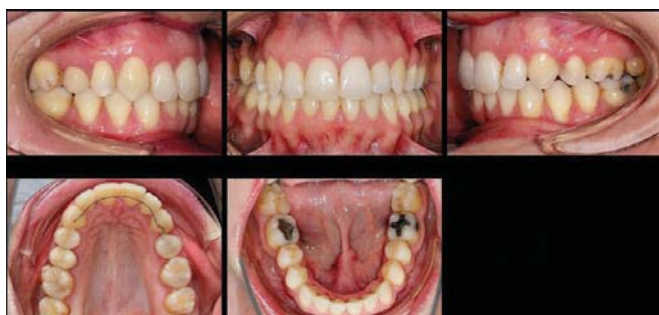

FIGURE 23: Patient 2 post treatment.

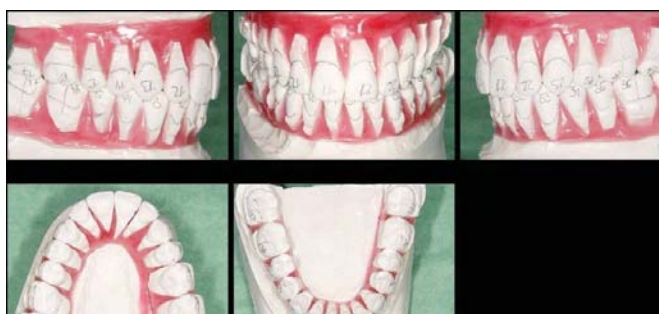

FIGURE 24: Patient 2 – original target set-up used to make the patient's incognito appliance. The post-treatment result achieved is very similar to the target set-up.

6. Enai, M., Bock, N., Ruf, S. White-spot lesions during multi-bracket appliance treatment: A challenge for clinical excellence. *Am J Orthod Dentofacial Orthop* 2011; 140: e17-e24.
7. Richter, E.M., Arruda, A.O., Peters, M.C., Woonsung, S. Incidence of caries lesions among patients treated with comprehensive orthodontics. *Am J Orthod Dentofacial Orthop* 2011; 139: 657-664.
8. Van der Veen, M.H., Attin, R., Schwestka-Polly, R., Wiechmann, D. Caries outcomes after orthodontic treatment with fixed appliances: do lingual brackets make a difference? *Eur J Oral Sci* 2010; 118: 298-303.
9. Wiechmann, D. A new bracket system for lingual orthodontic treatment. Part 1. Theoretical background and development. *J Orofac Orthop* 2002; 63: 234-245.
10. Fillion, D. Improving patient comfort with lingual brackets. *J Clin Orthod* 1997; 31: 689-694.
11. Fritz, U., Diedrich, P., Wiechmann, D. Lingual technique – patients' characteristics, motivation and acceptance: Interpretation of a retrospective survey. *J Orofac Orthop* 2002; 63: 227-33.
12. Wu, A., McGrath, C., Wong, R.W.K., Wiechmann, D., Rabie, A.B.M. Comparison of oral impacts experienced by patients treated with labial or customised lingual fixed appliances. *Am J Orthod Dentofacial Orthop* 2011; 139: 784-790.
13. Hohoff, A., Seifert, E., Fillion, D., Stamm, T., Heinecke, A., et al. Speech performance in lingual orthodontic patients measured by sonography and auditive analysis. *Am J Orthod Dentofacial Orthop* 2003; 123: 146-152.
14. Hohoff, A., Stamm, T., Ehmer, U. Comparison of the effect on oral discomfort of two positioning techniques with lingual brackets. *Angle Orthod* 2004; 74: 226-233.
15. Sattler, N. Collage et recollage: Un petit problem avec des effets majeurs dans la technique linguale. *International Orthodontics* 2005; 3: 329-337.
16. Wiechmann, D., Rummel, V., Thalheim, A., Simon, J., Wiechmann, L. Customised brackets and archwires for lingual orthodontic treatment. *Am J Orthod Dentofacial Orthop* 2003; 124: 593-599.
17. Rummel, V., Wiechmann, D., Sachdeva, R. Precision finishing in lingual orthodontics. *J Clin Orthod* 1999; 23: 101-113.
18. Demling, A., Dittmer, M., Schwestka-Polly, R. Comparative analysis of slot dimension in lingual bracket systems. *Head Face Med* 2009; 5: 27.
19. Kebert, M., McDonald, F., Sherriff, M., Cash, A. Slot size of lingual orthodontic brackets: are manufacturing standards being met? Abstract. European Society of Lingual Orthodontics London UK. 2012: 13.
20. Stamm, T., Wiechmann, D., Heinecken, A., Ehmer, U. Relation between second and third order problems in lingual orthodontic treatment. *J Ling Orthod* 2000; 3: 5-11.

An *in vitro* scanning electron microscopic study comparing the efficacy of passive ultrasonic and syringe irrigation methods using sodium hypochlorite in removal of debris from the root canal system

Précis

Passive ultrasonic irrigation (PUI) with more biocompatible 1% sodium hypochlorite (NaOCl) was evaluated and compared to syringe irrigation with 2.5% NaOCl, and it was concluded that PUI with 1% NaOCl is more effective in removal of debris from the root canal system than syringe irrigation with a higher concentration of 2.5% NaOCl.

Abstract

Objective: To evaluate and compare the cleaning ability of the more biocompatible 1% sodium hypochlorite (NaOCl) with passive ultrasonic irrigation (PUI) to that of 2.5% NaOCl with syringe method irrigation.

Material and methodology: Thirty-six extracted permanent single-rooted mandibular premolar teeth were decoronated at the cemento-enamel junction and divided randomly into four groups (nine in each group) after biomechanical preparation. Group 1: Control group – normal saline was used as an irrigant solution. Group 2: PUI with 1% NaOCl. Group 3: syringe irrigation with 1% NaOCl. Group 4: syringe irrigation with 2.5% NaOCl. Roots were split and canal walls were examined at the apical third at 1,000X magnification in a scanning electron microscope (SEM). Debris scores were recorded using a scoring scale. Means were tested for significance using nonparametric Mann–Whitney U and chi-square tests.

Results: Group 2 showed the lowest mean score of 0.33 compared to the other groups and Group 1 had the highest mean score. Significant difference was found when PUI with 1% NaOCl (Group 2) was done compared to syringe irrigation with 1% NaOCl (Group 3, $p=0.001$), and syringe irrigation with 2.5% NaOCl (Group 4, $p=0.002$).

Conclusion: PUI with 1% NaOCl is more effective in removal of debris from the root canal system than syringe irrigation with a higher concentration of 2.5% NaOCl.

Journal of the Irish Dental Association 2012; 58 (3): 156-161.

Dr Vineet S Agrawal MDS

Senior Lecturer,
Department of Conservative and
Endodontics,
M.P. Dental College, Hospital and Oral
Research Institute,
Vadodara,
India.

Professor Sonali Kapoor MDS

Department of Conservative and
Endodontics,
M.P. Dental College, Hospital and Oral
Research Institute,
Vadodara,
India.

Address for correspondence

Dr Vineet Agrawal
101 Vinay Complex, Near Dudhdhara
Dairy,
Bholav-Bharuch, Pin-392002,
Gujarat,
India.
T: 09428326511/02642-246076
E: vineetdent@yahoo.co.in

Introduction

Disinfection of the root canal system by using antimicrobial and tissue-dissolving irrigants is considered an essential part of chemomechanical debridement.¹ Residual pulp tissue, bacteria, and dentine debris remain in areas such as the dentinal tubules, accessory canals, canal ramifications, apical deltas, fins, etc., which are routinely left

uninstrumented after root canal preparation.² Irrigation is complementary to instrumentation in facilitating the removal of bacteria, debris and therapeutic materials such as gutta-percha, sealer and medicaments from root canals.

The effectiveness of irrigation relies on both the mechanical flushing action and the ability of irrigants to dissolve tissue. Irrigation

with sodium hypochlorite (NaOCl) has been shown to dissolve organic tissues and to be antibacterial in root canals.^{3,4} The inherent disadvantages of NaOCl are its cytotoxic effect⁵ and its potential to cause corrosion to stainless steel instruments.⁶ Thus, lesser concentrations like 1% NaOCl are more biocompatible.⁷

The flushing action of irrigants helps to remove organic and dentinal debris and microorganisms from the canal. Indeed, it has been suggested that the flushing action may be more important than the ability to dissolve tissue. The flushing action created by syringe irrigation is relatively weak, and dependent not only on the anatomy of the root canal system but also on the depth of placement and the diameter of the needle.⁸ Increase in the volume of irrigant does not significantly improve its flushing action and its efficacy to remove debris.⁹ The flushing action of irrigants may be enhanced by using ultrasound because the directional flow from apical to coronal, and eddies produced through the acoustic streaming created by the vibrating instrument, are more intense in velocity and magnitude around its tip.¹⁰ In a study by Cunningham *et al.*,¹¹ the flushing action of hand syringe irrigation was compared with ultrasound using saline as the irrigant. Ultrasound removed 86% of the bacterial spores from the root canal, while hand syringe irrigation removed 62%.

Passive ultrasonic irrigation (PUI) in combination with NaOCl has been shown to have better efficacy in debris removal.¹² The term passive here means that the ultrasonically driven file is placed in the centre of the root canal system with no cutting action on the dentinal walls.¹³ PUI relies on the transmission of acoustic energy from the oscillating file or smooth wire to an irrigant.¹⁴

Various instruments are used to prepare root canals. Rotary hand preparation techniques and rotary instruments with radial lands tend to produce round preparations. These round preparations may be produced in the centre or at one side of a long oval canal leaving uninstrumented canal extensions.¹⁵ In addition, many posterior teeth have complex isthmuses and other natural irregularities. If the dentine debris is not removed completely from the uninstrumented extensions, two unfavourable outcomes may result. First, calcium hydroxide and other medicaments that function only when in direct contact with the pathogens, cannot be placed in the space occupied by debris, and therefore could not be effective.¹⁶ Secondly, only those areas free of debris can be filled with gutta-percha and sealer; therefore, the debris-filled canal extensions may lead to leakage.¹⁷ Clearly, thorough removal of all debris is an essential part of root canal treatment.

The main objective of this study is to evaluate and compare the cleaning ability of the more biocompatible 1% NaOCl with PUI to that of 2.5% NaOCl with syringe method irrigation.

Materials and methodology

Thirty-six extracted permanent single-rooted mandibular premolar teeth were decoronated at the cemento-enamel junction and stored in distilled water. To facilitate their fracture for the scanning electron microscopic (SEM) examination, two parallel longitudinal grooves that did not penetrate the root canals were made on both external surfaces of the teeth.

The working length was established by deducting 1mm from the actual canal length, which was determined by inserting a size 15 file into the canal until the tip of the file was just visible at the apical foramen. The apical ends of the roots were sealed with wax, to prevent irrigation through the apical foramen during root canal preparation and also to simulate *in vivo* apical counter-pressure.

A pre-test sample size calculation procedure was carried out. It has been reported that the percentages of complete debris removal for sonic and ultrasonic irrigation were 5% and 92.5%, respectively (Rodig *et al.*).¹⁸ Based on the results of the above study the effect size, i.e., removal of debris, was calculated. Type I error was set as 0.05 and type II error at 0.10. Based on these values, the required minimum sample size for each group turned out to be 7. Based on these computations, 36 teeth (n=9 in each group) were selected for the study.

Group 1 – Control group

The coronal aspect of each canal was flared, using Gates Glidden drills (Dentsply; Maillefer, Ballaigues, Switzerland), sizes 2-4, to a depth where resistance was met. The canals were then instrumented with a #40 K-file to the established working length. Step back flaring was accomplished by subtracting 1mm from each successively larger file size up to #60 K-file. Irrigation of the canals was performed with the help of a hypodermic syringe and #27 gauge needle that was placed to 1mm short of the working length. 1ml of saline was used between each instrument change to give a total volume of 10ml. Final rinse of the canals was done with 5ml of saline.

Group 2 – PUI with 1% NaOCl

The same instrumentation sequence was followed as in Group 1. The irrigant used in this group was 1% NaOCl. During instrumentation, 1ml was used between each instrument change to give a total volume of 10ml. The final rinse was done with 5ml of 1% NaOCl using PUI (Piezon Master 400; EMS, Nyon, Switzerland). PUI was done by placing an ultrasonically vibrating #15 K Endosonic file (Endosonore; Maillefer, Ballaigues, Switzerland) to 1mm short of the working length with hypochlorite still in the canal for three minutes. The passive activation meant that there was no attempt made to instrument, plane or contact the canal walls with the file and every attempt was made to keep the file centred in the canal.

Group 3 – Syringe irrigation with 1% NaOCl

The same instrumentation sequence was followed as in Group 1. The irrigant used in this group was 1% NaOCl. During instrumentation 1ml was used between each instrument change giving a total volume of 10ml using a hypodermic syringe and #27 gauge needle that was placed to 1mm short of the working length. Final rinse of the canals was done with 5ml of 1% NaOCl.

Group 4 – Syringe irrigation with 2.5% NaOCl

The same instrumentation sequence was followed as in Group 1. The irrigant used in this group was 2.5% NaOCl. During instrumentation, 1ml was used between each instrument change, giving a total volume

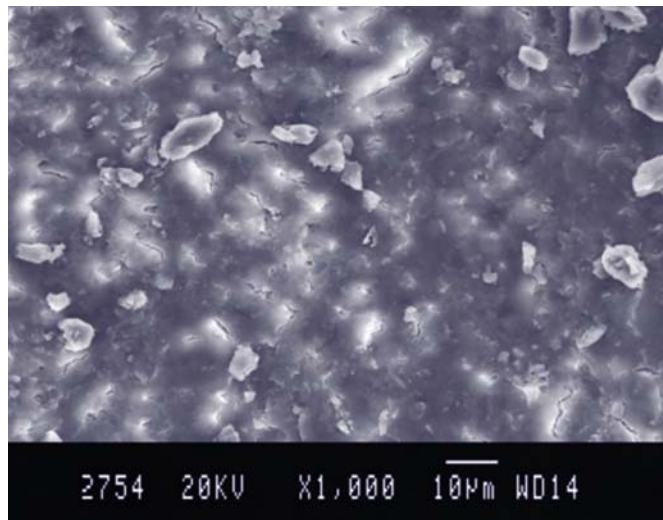


FIGURE 1: SEM picture of samples in Group 1. All dentinal tubules are covered with debris.

of 10ml using a hypodermic syringe and a #27 gauge needle that was placed to 1mm short of the working length. Final rinse of the canals was done with 5ml of 2.5% NaOCl.

After irrigation, all the root canals were dried with absorbent paper points. The canal orifice was sealed with cavit. The roots were split longitudinally and prepared for SEM investigation. The specimens were fixed in 2% glutaraldehyde solution for 12 hours. Then, using graded concentration of ethanol, starting from 30% and progressing to 50%, 70%, 90% and 100%, the specimens were dehydrated.

The specimens were fixed on an aluminium stub for gold ion sputtering (500 Å, Balzers CSD 030; Balzers, Liechtenstein). Then the specimens were viewed under SEM (Cambridge Stereoscan 180; Cambridge, UK) at 10KV accelerating voltage. After the general survey of the entire canal wall, photomicrographs were taken at 1,000X magnification of the apical third of the canal. The SEM photographs were coded and randomly mixed, so that examiners were blinded, and were evaluated by two calibrated evaluators using a standard scoring system as outlined below:

Scoring system

- Score 0 – root canal surface free of debris leaving the openings totally exposed.
- Score 1 – root canal surface covered with debris only at the opening of dentinal tubules.
- Score 2 – root canal surface with a thin covering of residue on the dentinal tubules with visible tubules in few regions.
- Score 3 – surface covered with debris with no dentinal tubule openings visible.

Intraobserver reproducibility and interobserver agreement were calculated. When a disagreement in scoring occurred, an additional analysis was performed with both evaluators together until a consensus was reached.




FIGURE 2: SEM picture of samples in Group 2. All dentinal tubules are free from debris and open.

The score data were subjected to statistical analysis using the SPSS 11.0 program (SPSS Inc; Chicago, IL, USA). A chi-square test was used for multiple group comparisons and Mann–Whitney U test for group wise comparisons at a significance level of $p \leq 0.05$.

Results

Interobserver agreement was 90% ($k=0.9057$; confidence interval = 0.8310–0.9804), and intraobserver reproducibility was 98% ($k=0.9843$; confidence interval = 0.9626–1), with no significant influence of the observer ($p=0.9825$).

Mean scores of debris layer present at the apical third of root canal samples and statistical difference between all four groups are listed in **Table 1**.

Group 2 (PUI with 1% NaOCl) shows the lowest mean score of 0.33 compared to the other groups, and Group 1 (control group) had the highest mean score. There was a highly statistically significant difference between the groups with respect to mean scores ($p<0.001$).

Further, the Mann–Whitney U test was applied to find out the significant difference between two independent groups as shown in **Table 2**. The formula used was as follows:

$$U = n_1 n_2 + \frac{n_1(n_1 - 1)}{2} - \sum R_i$$

Where R = rank order assigned to each value

There was no statistically significant difference ($p=0.059>0.001$) found between Group 1 (control group) and Group 3 (syringe irrigation with 1% NaOCl) ($p=0.190>0.001$), and between Group 3 (syringe irrigation with 1% NaOCl) and Group 4 (syringe irrigation with 2.5% NaOCl). However, a significant difference was found when the passive ultrasonic irrigation with 1% NaOCl (Group 2) was done




FIGURE 3: SEM picture of samples in Group 3. Few dentinal tubules are free from debris and open.

compared to syringe irrigation with 1% NaOCl (Group 3, $p=0.001$) and syringe irrigation with 2.5% NaOCl (Group 4, $p=0.002$).

Figures 1, 2, 3 and 4 show the SEM images of each of the four groups.

Discussion

Dentinal debris is the term for the organic and inorganic remnants in the root canal system. Dentinal debris differs from smear layer in that the latter is found only in areas where there has been mechanical action of endodontic instrumentation. The diversity of the root canal anatomy and the irregularities in the dentine walls make it increasingly difficult to successfully remove all the infected debris and the necrotic pulp tissue.¹⁹

The importance of irrigation as a method of removing debris from the root canal is well recognised. It has been shown that 70% more debris remained in the root canal when instrumentation was carried out without irrigation.²⁰

In the current study, the cleaning ability of different concentrations (1% and 2.5%) of NaOCl with and without passive ultrasonic activation was evaluated at the apical third. The root canal samples were randomly divided into four groups. Group 2, where the final flush of the canals was performed with 1% NaOCl in conjunction with




FIGURE 4: SEM picture of samples in Group 4. Some dentinal tubules are free from debris and open.

passive ultrasonics, showed significantly less debris at the apical third. The canals irrigated with physiological saline by syringe method (Group 1: control group) showed the maximum amount of remnant debris, followed by canals irrigated with 1% NaOCl (Group 3) and 2.5% NaOCl (Group 4) by syringe method. The results showed that the passive ultrasonic agitation of 1% NaOCl improved the debridement of the root canals at the apical third.

The test root canal samples were decoronated prior to instrumentation. This was done to enable ease of placement of the ultrasonically activated file passively in the centre of the root canals, and to prevent variations in the dimensions of the access cavity preparation from interfering in the study methodology. They were then instrumented with hand stainless steel endodontic K-files to the size #40 apically in step back manner. It has been shown that small root canals may restrict the flushing action of irrigants, with the result that such canals should be enhanced to allow effective irrigation. It has been reported that hand irrigation was less effective when the canals were enlarged to less than size 40 at the apex.²¹

The apical areas of the root canals were evaluated for remnant debris, as this is the critical area in root canal preparation, which houses the lateral canal and the apical delta. After instrumentation the debris

TABLE 1: Mean values of debris score at apical third and statistical comparison between all four groups.

		N	Std.			Chi square	'p' value
			Mean	deviation	Min Max		
Debris score	Group 1	9	2.44	0.527	2 3	24.135	<0.001
	Group 2	9	0.33	0.5	0 1		
	Group 3	9	1.89	0.601	1 3		
	Group 4	9	1.44	0.527	1 2		

TABLE 2: Mann-Whitney U test between the two independent groups.

	Between group comparison	Mann-Whitney U	'p' value
Debris score	Group 1 vs. Group 2	0	<0.001
	Group 1 vs. Group 3	22	0.059
	Group 1 vs. Group 4	10	0.003
	Group 2 vs. Group 3	3	0.001
	Group 2 vs. Group 4	7.5	0.002
	Group 3 vs. Group 4	25	0.19

accumulates and is more evident in the apical third of the canals. This could lead to loss of working length, and hindered penetration of the intracanal medicaments and sealants; it also increases the chances of forcing the debris into the periapical region.²²

NaOCl is the most commonly used irrigant in root canal therapy, for its tissue-dissolving capability, microbicidal activity and lubricating properties.²³ The activity of NaOCl is related to the free hypochlorous acid (HOCl) present in the solution, which reacts with organic tissue and microorganisms. NaOCl is used in endodontics in the concentrations of 0.5%-5.25% and is still a matter of debate. The antimicrobial and tissue-dissolving properties of NaOCl are dependent on the concentration.^{23,24} However, at higher concentrations it is cytotoxic – causing caustic burns⁵ – and has a corrosive effect on the endodontic files.⁶

In the present study, 1% and 2.5% NaOCl were used as irrigating solutions for debridement of the canals. While NaOCl at the concentration of 2.5% is most commonly used, concentrations of 1% and below have been shown to be biocompatible.⁷

In the present study, 1% NaOCl agitated with passive ultrasound for three minutes was shown to debride the apical third significantly better than the syringe method, correlating with earlier studies. Passive ultrasonic agitation of 1% NaOCl for one, three and five minutes has been shown to enhance the debridement of root canals at the apical third.²⁴ These results are in accordance with the studies by Sabins *et al.*,²⁶ who reported that passive sonic and ultrasonic activation for 30 and 60 seconds produces significantly cleaner canals than irrigation alone, with PUI producing significantly cleaner canals than passive sonic irrigation. A study by Rodig *et al.*¹⁸ concluded that PUI removed significantly more debris than syringe irrigation or a sonically activated device (Vibringe).

The mechanisms behind ultrasonics are mainly cavitation and acoustic streaming. The concept of acoustic streaming was described as the rapid movement of particles of fluid in a vortex-like motion around a vibrating object. The fluid is transported from the apical to the coronal end, at a rate of a few centimetres per second, resulting in hydrodynamic shear stresses around the file capable of disrupting most biological material.¹³

In the current study, passive ultrasonic agitation of the irrigants was done with a #15 endosonic K-file for three minutes. A smaller file was selected to have an increased streaming velocity to enhance the debridement of the canal. The best effect is obtained when the file is small, as the amplitude displacement is large and the frequency is high.¹⁴ The recommended application time of ultrasonic agitation of the irrigants varies from 30 seconds to five minutes in studies,^{14,25} with a three-minute application being commonly chosen and showing consistent results.¹⁴ The limitation of the study was that, during PUI with a continuous flush, flow rate of the irrigant that enters the apical part of the root canal cannot be standardised. Although irrigant flow rate is considered a highly significant factor determining flow pattern in fluid dynamics, it is unknown whether it influenced the performance of ultrasonic irrigation.

Some studies indicate that debris removal from the coronal part is considered to be easier than from the apical part,²⁶ whereas other authors found no differences among root canal thirds.²⁷ In the present study, the needle employed was a #27 gauge, which corresponds approximately to ISO size #35. The tip of the needle reached the apical third during the delivery of the irrigants in the root canal samples. Therefore, the introduction depth of the needle tip might result in better debris removal from the apical third of the canal in the present study compared to other studies.

The main advantage of SEM is that it allows evaluation of both halves of the canal wall along their entire length. However, only the surface can be examined, and the depth of debris cannot be determined precisely. Moreover, there are practical limitations for grading the root canal surface when a scoring system is used. This considered, it is estimated that a sufficiently representative view of the debridement of the root canal was achieved in the present study.

The study being *in vitro*, it has certain limitations. For example, the *in vitro* design allowed for a more aggressive approach, which increased debridement efficiency as compared to *in vivo* instrumentation. Walton²⁸ and Bolanos and Jensen²⁹ also reported on differences in instrument manipulation, which would increase the effectiveness of *in vitro* instrumentation. Fairbourn *et al.*³⁰ stated that the positive apical pressure present in the mouth is difficult to simulate *in vitro*. They concluded that this difference in apical pressure might alter canal preparation in an *in vivo* situation. In an *in vivo* study, Salzgeber and Brilliant³¹ determined that the presence of vital tissue confined the irrigating solution to the space of instrumentation. In necrotic cases, the solution permeated the canal faster than in vital cases, and extruded into the periapical lesion in a random pattern. Thus, *in vivo* study is further required to directly correlate the results of the present study clinically.

The clinical relevance of the current study indicated that it is suggested to follow the clinical regimen of final flush with 1% NaOCl using PUI in the apical region rather than the higher concentration of 2.5% NaOCl using the syringe method, which is more cytotoxic and corrosive to instruments.

Conclusion

From the results of the present study it can be suggested that PUI with 1% NaOCl is more effective in removal of debris from the root canal system than syringe irrigation with a higher concentration of 2.5% NaOCl. Hence 1% NaOCl, which is more biocompatible, with PUI, should be used rather than using a higher concentration of 2.5% NaOCl, which has cytotoxic properties.

References

1. Haapasalo, M., Endal, U., Zandi, H., Coil, J. Eradication of endodontic infection by instrumentation and irrigation solutions. *Endodontic Topics* 2005; 10: 77-102.
2. Abbott, P.V., Heijkoop, P.S., Cardaci, S.C., Hume, W.R., Heithersay, G.S. An SEM study of the effects of different irrigation sequences and ultrasonics. *Int Endod J* 1991; 24: 308-316.

3. Hand, R.E., Smith, M.L., Harrison, J.W. Analysis of the effect of dilution on the necrotic tissue dissolution property of sodium hypochlorite. *J Endod* 1978; 4: 60-64.
4. Moorer, W.R., Wesselink, P.R. Factors promoting the tissue-dissolving capability of sodium hypochlorite. *Int Endod J* 1982; 15: 187-196.
5. Spangberg, L., Engstrom, B., Langeland, K. Biologic effects of dental materials. 3. Toxicity and antimicrobial effect of endodontic antiseptics *in vitro*. *Oral Surg Oral Med Oral Pathol* 1973; 36: 856-871.
6. Neal, R.G., Craig, R.G., Powers, J.M. Effect of sterilisation and irrigants on the cutting abilities of stainless steel files. *J Endod* 1983; 9: 93-96.
7. Holland, R., Soares, I.J., Soares, I.M. Influence of irrigation and intracanal dressing on the healing process of dog's teeth with apical periodontitis. *Endod Dent Traumatol* 1992; 8: 223-229.
8. Abou-Rass, M., Piccinino, M.V. The effectiveness of four clinical irrigation methods on the removal of root canal debris. *Oral Surg Oral Med Oral Pathol* 1982; 54: 323-328.
9. Walters, M.J., Baumgartner, J.C., Marshall, J.G. Efficacy of irrigation with rotary instrumentation. *J Endod* 2002; 28: 837-839.
10. Stock, C.J.R. Current status of the use of ultrasound in endodontics. *Int Dent J* 1991; 41: 175-182.
11. Cunningham, W.T., Martin, H., Forrest, W.R. Evaluation of root canal debridement by the endosonic ultrasonic synergistic system. *Oral Surg Oral Med Oral Pathol* 1982; 53: 401-404.
12. Lee, S.J., Wu, M.K., Wesselink, P.R. The effectiveness of syringe irrigation and ultrasonics to remove debris from simulated irregularities within prepared root canal walls. *Int Endod J* 2004; 37: 672-678.
13. Van Der Sluis, L.W.M., Versluis, M., Wu, M.K., Wesselink, P.R. Passive ultrasonic irrigation of the root canal: a review of the literature. *Int Endod J* 2007; 40: 415-426.
14. Van Der Sluis, L.W.M., Wu, M.K., Wesselink, P.R. A comparison between a smooth wire and a K-file in removing artificially placed dentine debris from root canals in resin blocks during ultrasonic irrigation. *Int Endod J* 2005; 38: 593-596.
15. Bergmans, L., Van Cleynenbreugel, J., Beullens, M., Wevers, M., Van Meerbeek, B., Lambrechts, P. Progressive versus constant tapered shaft design using NiTi rotary instruments. *Int Endod J* 2003; 36: 288-295.
16. Siqueira, J.F. Jr., Lopes, H.P. Mechanisms of antimicrobial activity of calcium hydroxide: a critical review. *Int Endod J* 1999; 32: 361-369.
17. Wu, M.-K., Wesselink, P.R. A primary observation on the preparation and obturation in oval canals. *Int Endod J* 2001; 34: 137-141.
18. Rodig, T., *et al.* Comparison of the Vibringe system with syringe and passive ultrasonic irrigation in removing debris from simulated root canal irregularities. *J Endod* 2010; 36 (1): 1-4.
19. Guerisoli, D.M.Z., Marchesan, M.A., Walmsley, P.J., Pecora, J.D. Evaluation of smear layer removal by EDTAC and sodium hypochlorite with ultrasonic agitation. *Int Endod J* 2002; 5: 418-421.
20. Baker, N.A., Eleazer, P.D., Auerbach, R.E., Seltzer, S. Scanning electron microscope study of the efficacy of the various irrigating solutions. *J Endod* 1975; 1: 127-135.
21. Wu, M.K., Wesselink, P.R. Efficacy of three techniques in cleaning the apical portion of curved root canals. *Oral Surg Oral Med Oral Path Oral Radio Endod* 1995; 79: 492-496.
22. Fairbourn, D.R., McWalter, G.M., Montgomery, S. The effect of four preparation techniques on the amount of apically extruded debris. *J Endod* 1987; 13 (3): 102-107.
23. Estrela, C., Estrela, C.R.A., Barbin, E.L., Spano, J.C.E., Marchesan, M.A., Pecora, J.D. Mechanism of action of sodium hypochlorite. *Braz Dent J* 2002; 13 (2): 113-117.
24. Radcliffe, C.E., Potouridou, L., Qureshi, R., *et al.* Antimicrobial activity of varying concentrations of sodium hypochlorite on the endodontic microorganisms *Actinomyces israelii*, *A. naeslundii*, *Candida albicans* and *Enterococcus faecalis*. *Int Endod J* 2004; 37: 438-446.
25. Neto, J.G.P., Marchesan, M.A., Ferreira, R.B., Silva, R.G., Sousa, Y.T.C.S., Neto, M.D.S. *In vitro* evaluation of endodontic debris removal as obtained by rotary instrumentation coupled with ultrasonic irrigation. *Aust Endod J* 2006; 32: 123-128.
26. Sabins, R.A., Johnson, J.D., Hellstein, J.W. A comparison of the cleaning efficacy of short-term sonic and ultrasonic passive irrigation after hand instrumentation in molar root canals. *J Endod* 2003; 29 (10): 674-678.
27. Munley, P.J., Goodell, G.G. Comparison of passive ultrasonic debridement between fluted and nonfluted instruments in root canals. *J Endod* 2007; 33: 578-580.
28. Walton, R.E. Histologic evaluation of different methods of enlarging the pulp canal space. *J Endod* 1976; 2: 304-311.
29. Bolanos, O.R., Jensen, J.R. Scanning electron microscopy comparisons of the efficacy of various methods of root canal preparation. *J Endod* 1980; 6: 815-822.
30. Fairbourn, D.R., McWalter, G.M., Montgomery, S. The effect of four preparation techniques on the amount of apically extruded debris. *J Endod* 1987; 13: 102-108.
31. Salzgeber, R.M., Brilliant, J.D. An *in vitro* evaluation of the penetration of an irrigating solution in root canals. *J Endod* 1977; 3: 394-398.

Radiographic evaluation of the technical quality of undergraduate endodontic 'competence' cases in the Dublin Dental University Hospital: an audit

Précis: An audit examining the technical quality of undergraduate endodontic 'competence' cases in the Dublin Dental University Hospital revealed favourable results compared to benchmark studies, but identified areas for improving quality.

Abstract

Purpose: The aim of this audit was to evaluate the technical quality of undergraduate *de novo* endodontic competence cases in the Dublin Dental University Hospital (DDUH) compared to European standards.^{1,2}

Materials and methods: A radiographic analysis of the number of canals in student 'competence' cases (completed 2009-2010) that met the accepted technical criteria for an ideal root canal treatment was carried out. The benchmark was formulated using accepted European guidelines. Several technical factors were analysed including the apical extent of obturation (within 2mm of radiographic apex), the presence of voids, technical errors and the presence of untreated roots. One hundred and nineteen root canals were initially selected in 78 teeth; however, five teeth were excluded from analysis as the postoperative radiograph was either missing or not diagnostic.

Results: Single-rooted teeth demonstrated voids in 36% of root fillings, and 69% were filled to within 2mm of the apex and there were no detectable technical deficiencies. Multi-rooted teeth demonstrated voids in 38% of root fillings; 60% were filled to within 2mm and 94% of canals demonstrated no deviation from the original canal. Combined results demonstrated that 49% of all the single-rooted teeth and 17% of all the multi-rooted teeth were acceptable within the technical parameters identified in the guidelines.

Conclusions: Analysis of individual technical criteria revealed areas in which the quality was acceptable and others in which it could be improved. Although the overall results appeared poor, they were similar to previous studies of the technical quality of undergraduate root canal treatment.²⁻⁵

Journal of the Irish Dental Association 2012; 58 (3): 162-166.

Introduction

The aim of root canal treatment is to chemo-mechanically clean and obturate the root canal system to prevent or cure apical periodontitis.⁶ Root canal treatment is indicated if the pulp has irreversible disease or is necrotic. It is essential to take appropriate radiographs before, during and after the procedure. Every practitioner is

required to retain a record of the completed treatment in the form of a postoperative radiograph. The technical standard of root canal treatment has been demonstrated to be closely related to success² and a 'proxy' assessment of technical success is the postoperative radiograph of the completed root canal treatment.⁷ Technical guidelines related to preparation and obturation

Mohit Kumar

Great Western Hospitals
NHS Foundation Trust
Great Western Hospital
Marlborough Road
Swindon
United Kingdom

Henry F Duncan

Lecturer and Consultant in Endodontics
Division of Restorative Dentistry
and Periodontology
Dublin Dental University Hospital
Trinity College Dublin
Lincoln Place
Dublin
Ireland

Address for correspondence

Henry F Duncan
Dublin Dental University Hospital
T: 01-612 7356
E: Hal.Duncan@dental.tcd.ie

published by Sjögren (1990)² and the European Society of Endodontology (2006)¹ are accepted as European standards.

It is important to make the distinction between audit and research, audit being designed to examine current practice against recognised 'benchmarks' of best practice. It is not intended to be hypothesis-driven or to generate data as part of an original scientific article. After the initial audit is completed an action plan is generated, implemented and, after a designated time period, re-audited to complete the audit 'loop'. The aim of this audit was to establish the technical quality of root canal treatment performed by undergraduate dental students in the Dublin Dental University Hospital (DDUH).

Materials and methods

The audit was carried out in order to assess the technical quality of undergraduate root canal treatment compared to accepted European guidelines. After a suitable audit area was identified, it was discussed, proposed and approved by the DDUH clinical audit committee.

The target sample for the audit was single- and multi-root 'competence' cases treated by undergraduate students. All third-, fourth- and fifth-year undergraduate students in DDUH complete a 'competence' in both single- and multi-root *de novo* endodontic treatments, which they must pass in order to proceed with their studies. Students are given 'permission to proceed' with the competence by a senior member of staff, after successful completion

of two supervised pre-competence cases in single- and multi-root endodontic treatments, respectively. These competence cases are treated under the supervision of a part-time teacher and are approved afterwards by a senior staff member; however, they are designed to be an assessment of the student's endodontic ability and therefore should be essentially unassisted. During the audit all of the 'competence' forms were retrieved for single- and multi-rooted endodontic treatments completed in DDUH in the year 2009-2010. A total of 46 single- and 32 multi-rooted competence cases were identified for the purpose of this audit. The single roots were analysed per tooth, while multi-rooted canals were initially analysed individually and thereafter combined per tooth. Premolar teeth appear in both single- and multi-root categories, depending on the number of roots that the chosen tooth exhibited. It is established within the DDUH guidelines that although premolar teeth are permissible as part of the multi-root competence, molar teeth should be used if available.

The root canal instrumentation (in the observed period) was generally carried out by traditional hand instrumentation using a step back technique; however, hand and rotary nickel titanium (as a result of a new teaching protocol) was employed in selected later cases. The teeth were obturated with International Organisation for Standardisation (ISO) corresponding gutta-percha points using a lateral condensation technique.

A pro forma sheet (**Appendix 1**) was designed to aid analysis using criteria from the European benchmark standards,^{1,2} and the European Society of Endodontology (2006)¹ consensus paper, supplemented by the seminal endodontic outcome study by Sjögren (1990).² From the standards, the relevant technical indicators were identified and the ideal standard defined. The ideal root canal obturation should terminate within 0-2mm of the radiographic apex, have no evidence of voids, should be present in all the root canals, and should be contained within the original canal anatomy with no evidence of apical deviation, canal 'ledging' or straightening.^{1,2}

Postoperative radiographs taken from each 'competence' case, using the paralleling technique, were analysed by two assessors (non-consultant hospital doctors – NCHDs) and the relevant data collected on the pro forma sheet. If there was disagreement between the NCHDs, a third assessor (Consultant) was asked to adjudicate; there was inter-observer disagreement in five cases. All single-rooted and the majority of multi-root postoperative radiographs were available electronically and were assessed using the measuring software in the Dimaxis system (Dimaxis, Planmeca; Helsinki, Finland). Seven of the multi-rooted cases had old style 'paper' charts, which were obtained to access their respective radiographs. From these charts, radiograph films were assessed using an x-ray viewbox and the distance to the apex measured by a conventional metric ruler.

Results

Single-rooted teeth

One of the 46 cases analysed (2%) had no radiograph available and was eliminated from the audit. In one further case the radiograph was deemed to be undiagnostic and was not included in the analysis. Of

Appendix 1: Pro forma sheet for data collection.

Name:			
Patient no.:			
Tooth no.:			
Root:			
	Yes	No	Undiagnostic radiograph(UR)/no radiograph available
Presence of voids			
Within 0-2mm of radiographic apex			
Over-obturated			
Under-obturated (>2mm short of radiographic apex)			
All roots obturated			
Prepared canal contains the original canal			
No extrusion			
Separated instrument			

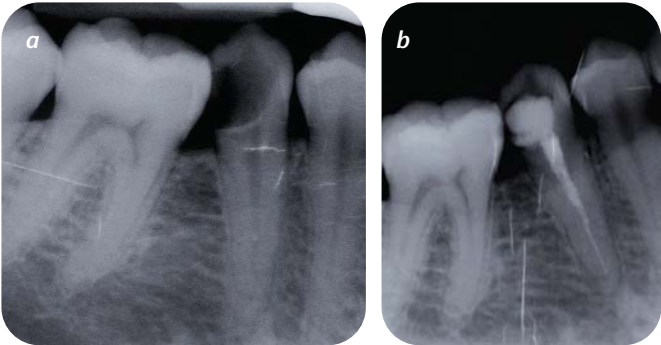
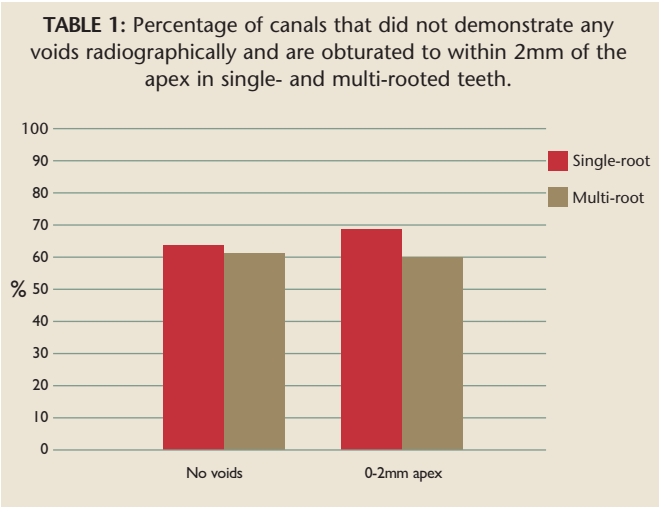


FIGURE 1a: Preoperative periapical radiograph of tooth 45, demonstrating a coronal radiolucency indicative of extensive caries. This premolar had one canal and was considered suitable for the single-root competence test.
FIGURE 1b: Postoperative periapical radiograph of the 45, demonstrating a root canal filling that was under-extended (>2mm from the radiographic apex) and contained voids. The decision was made to re-treat this tooth, before completion of the competence.



the remainder, 64% of the root-filled canals had no detectable voids, while 36% of the radiographs demonstrated voids in the canal (Figures 1a and b). In 69% of cases the root filling was within 2mm of the radiographic apex, in 16% it was over-extended and in 15% it was under-extended (Figure 1b) (Table 1). All of the radiographs analysed revealed that the root canal filling material was contained in the original canal. When the investigated factors (voids, length, procedural errors) were combined, 49% of teeth were considered to meet the technical standard for single-root ‘competence’ cases (Figures 2a and b) (Table 1).

Multi-rooted teeth

A total of 73 canals were assessed from 32 teeth. In one case the radiograph was undiagnostic and in two cases there was no postoperative radiograph available; these were not included in the analysis. A total of 62% of the canals had no detectable voids, while 38% demonstrated voids. In 60% of roots the gutta-percha was

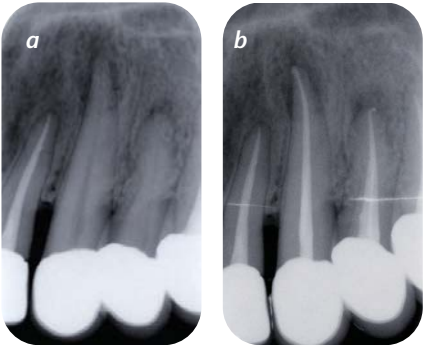


FIGURE 2a: Preoperative periapical radiograph of tooth 23, demonstrating an apical radiolucency indicative of apical periodontitis. This canine was considered suitable for the single-root competence test.
FIGURE 2b: Postoperative periapical radiograph of the 23, demonstrating a root canal filling containing no voids, but evidence of slight overfilling and extrusion of gutta-percha/sealer.

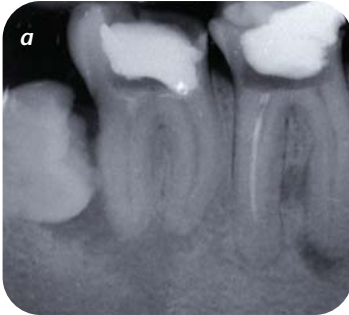

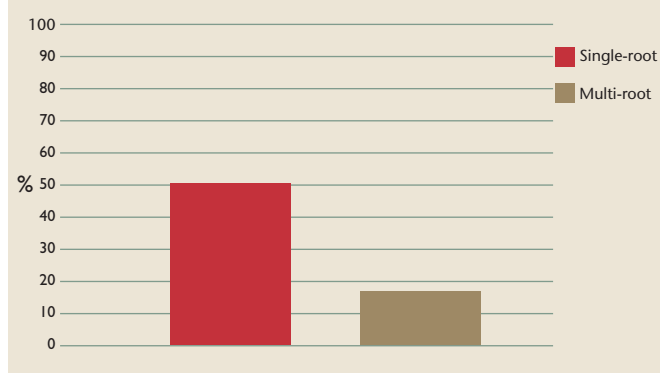
FIGURE 3a: Preoperative periapical radiograph of tooth 47, demonstrating an apical radiolucency indicative of apical periodontitis associated with the 46 and 47. This second molar tooth was considered suitable for the multi-root competence test.

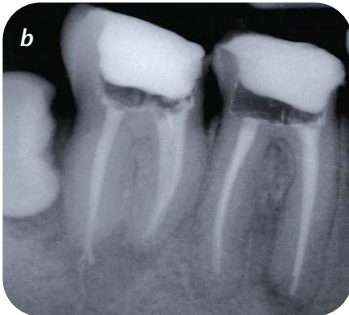

FIGURE 3b: Postoperative periapical radiograph of the 47, demonstrating a root canal filling in the mesial root canals that contained no voids, was obturated to within 0-2mm and was contained within the original canal anatomy. The distal root filling, although not containing any voids, had clear evidence of gutta-percha/sealer extrusion, and was classed as overfilled. This designated tooth 47 as unsatisfactory for the purposes of this technical audit.

within 0-2mm of the radiographic apex, in 9% it was over-extended (Figures 3a and b) and in 31% of the roots it was under-extended (Table 1). A total of 94% of cases demonstrated the prepared canal containing the original canal and 6% of the canals were deviated from the original canal. When the technical factors were combined per canal, 28 of the 73 canals (38%) were considered satisfactory. When the individual canals of multi-rooted teeth were collated, 45% of teeth had no detectable voids. A total of 95% of teeth had all roots obturated on postoperative radiographs; 5% of teeth had one or more roots that had been ‘missed’. When technical indicators were combined as multi-rooted teeth, five teeth from 29 teeth (17.5%) were considered satisfactory (Figures 3a and b) (Table 2).

TABLE 2: Percentage of single- and multi-rooted teeth that satisfy all technical parameters.



Finally, when premolars (single- and multi-root) are analysed separately, 10 root canals were treated from eight teeth. A total of 80% had no detectable voids, while 20% demonstrated voids. In 80% of roots the root filling was within 0-2mm of the radiographic apex; in 20% it was short. There were no premolar cases demonstrating deviation of the prepared canal.

Discussion

The aim of this audit was to investigate the technical quality of root canal filling by evaluation of postoperative intra-oral radiographs. Current European guidelines were used as a benchmark for the assessment.¹ This audit was not designed to measure the success of root canal treatment as that would require extensive clinical examination and follow-up. However, technical quality is generally considered to be a 'proxy' marker as there is a positive correlation between high technical quality and endodontic outcome.⁷

Undergraduate 'competence' cases were selected as they reflect by regulation, a student's own work. It is also implicit that the cases were deemed acceptable to pass the competence, as only successful cases were analysed within the audit. Therefore, it is possible that this standard of treatment may not be representative of 'non-competence' cases. Therefore, this audit does not represent accurately the technical standards of all undergraduate root canal treatment in the DDUH.

The quality of root canal treatment was assessed in a classic Swedish university-based study in which the treatment was similarly carried out by undergraduate students under supervision.² The purpose of their study was to determine the factors that affect the long-term success of endodontic treatment. When assessing the apical level of obturating material in 204 cases, 62% were within 0-2mm of the radiographic apex. A total of 11% of all the teeth were under-obtured, and 27% were over-obtured.² The presence or absence of voids was not assessed in the study. The cases that were obturated to within 0-2mm of the radiographic apex were associated with a significantly better outcome than cases that were either under- or over-obtured. The conclusions stressed the importance of good length control and obturation to within 2mm of the apex for long-term success. The results from Sjögren's classic study were similar to

the results for extent of root canal filling obtained in this audit. In this current audit, 67% of the single-rooted teeth and 60% of the roots in multi-rooted teeth were obturated to within 0-2mm of the radiographic apex. Possible reasons for under-obturation include preparation errors or obliteration of the canal preventing instrumentation of the entire canal, while possible reasons for over-obturation include over-instrumentation, poor length control or excessive pressure during obturation.⁷

Other studies examining the technical quality of undergraduate root canal treatment have been published.^{3-5,8-11} Within Ireland, a similar study investigated the technical quality of undergraduate treatment on single-rooted teeth in Cork University School and Hospital;³ the results of that study compare closely with this audit as 70% (69%) of the teeth were obturated to within 0-2mm. The overall number of teeth that were considered 'acceptable' was higher in the Cork study,³ principally because of a smaller number of canals containing voids (10%) than in the current study (36%). It is not clear what accounts for this difference; perhaps it is due to stricter evaluation criteria in the current study or reflects a difference in pre-clinical/clinical teaching between the two schools.

An audit of undergraduate root canal treatment within the UK revealed that only 13% of cases were deemed satisfactory in terms of radiographic quality of the root filling and the distance from the radiographic apex.⁴ The authors concluded that the technical quality of undergraduate student root canal treatment was poor.⁴ Although our study compares favourably with the UK audit, the criteria Hayes *et al.* (2001) used for radiographic assessment were slightly different and could account for at least some of the difference.

Studies from other countries reveal a range in the quality of technical root canal fillings performed by undergraduate students.^{5,8-11} A Greek study reported satisfactory root fillings in 71% of anterior teeth and 39% of molar teeth; however, the multi-rooted teeth were judged per canal and not per tooth, which inflates the reported results.⁵ A study from Turkey revealed 33% of teeth to be technically adequate,⁸ a separate Greek study reported 55% of teeth technically adequate,⁹ and a study from Jordan reported 47% of root canal fillings to be satisfactory,¹⁰ while a Saudi Arabian study reported just 23% of cases to be satisfactory.¹¹ Several findings are common to these studies, with the technical quality of undergraduate root canal treatment being generally poor and single-rooted teeth being completed satisfactorily more often than multi-rooted teeth.^{5,9,10} These features are also evident in the current audit.

The European Society of Endodontology (2006)¹ consensus report states that the postoperative radiograph should reveal a root that is completely filled, with no spaces between the filling and the canal wall. For single-rooted and multi-rooted teeth per canal in the current study, 64% and 62% of cases did not contain voids, respectively. When assessing per tooth in multi-rooted cases, there was a marked decrease to 45% of teeth containing no voids. It can be speculated that there is an increased likelihood of obtaining voids in the roots of multi-rooted teeth due to the undergraduate challenge of the lateral condensation obturation technique in posterior teeth.

All single-rooted teeth and 94% of the roots of multi-rooted teeth had their prepared canals contained within the original canals. This deviation of prepared canals from original canals, only in multi-rooted teeth, would be expected because of the presence of curved canals in molar teeth, which are recognised to be more challenging to instrument effectively. When technical factors were combined, 49% of single-rooted teeth and 17% of multi-rooted teeth were considered satisfactory. This appears low but can be rationalised, particularly in multi-rooted teeth where three to four canals are combined into one tooth. As the presence of voids was relatively high in this audit this 'skews' the data, increasing the number of teeth that are technically unacceptable. Interestingly, voids and obturation within 0-2mm results were very similar for single- and multi-rooted teeth. Unfortunately, although the presented results are poor, they compare or are superior to other results in similar studies in the literature.^{3,4,10,11}

A drawback when assessing mandibular molars was visualising all the root canals on the radiograph, as many overlapped, making effective separation impossible. This was a limitation in assessing these canals, so for the purpose of this audit the mesial canals were considered as one canal. Radiographic parallax methods and altered horizontal angulation of the x-ray tube head could assist in separating the mesial canals in these cases, which reveals an important area for future student teaching. It is interesting to highlight the unavailability of two postoperative radiographs, one electronic for single-rooted and one traditional film for multi-rooted teeth. It is possible that the 'wet' film was misplaced, while this is unlikely with the electronic version. It is hoped that the introduction of the phosphor plate system will reduce the incidence of 'missing' radiographs in the DDUH.

Finally, anecdotally the most frequent tooth chosen for 'competence' for single-rooted teeth was the upper central incisor, which perhaps implies that trauma is a major source of patients for 'competences' within a teaching hospital. A wide range of multi-rooted teeth were used as 'competence', with lower first molars being the most commonly treated teeth.

Conclusions and action plan

This audit demonstrates favourable results for termination of root canal filling when compared to the benchmark standard. The desired aim to achieve obturation to within 2mm of the radiographic apex can be achieved by careful instrumentation and perhaps improved by the continued introduction of new technologies. A specialist's opinion (if available) should be sought without delay if the canal appears to be obliterated during instrumentation to avoid blockage and potential under-obturation. However, in terms of other technical markers, there is a need to highlight deficiencies that can be improved, as the overall result for technically acceptable root canal treatment was poor. A total of 63% of single-rooted cases and 60% of multi-rooted cases were considered acceptable in terms of no voids; this was considered too low. There is a need to improve obturation techniques to have the root "completely filled with no spaces between the filling and the canal wall".¹ As a result of the findings, the following action plan was decided at the DDUH audit committee:

1. Voids can be reduced by the introduction of use of greater tapered gutta-percha points and the need for lateral condensation should be minimised. These gutta-percha points have been introduced to the undergraduate curriculum recently and should reduce the risk of void formation.
2. The use of nickel titanium instruments should be considered in all undergraduate cases for improved length preparation, reduced likelihood of blockage and obturation to within 0-2mm of the radiographic apex. These instruments are thought to improve preparation and prevent the loss of length during preparation.
3. Apex locators should generally be used for accurate working length determination and confirmed with a radiograph. These are to be used routinely within the clinics to improve the length of instrumentation and obturation.
4. Use of an electronic radiograph database in the DDUH should minimise the risk of radiographs that should be retained being misplaced.
5. This audit should be repeated after two years when the integration of the action plan resulting from this audit has come into function.

References

1. **European Society of Endodontology.** Quality guidelines for endodontic treatment: consensus report of the European Society of Endodontology. *Int Endod J* 2006; 39: 921-930.
2. **Sjögren, U., Hagglund, B., Sundqvist, G., Wing, K.** Factors affecting the long-term results of endodontic treatment. *J Endod* 1990; 16: 498-504.
3. **Lynch, C.D., Burke, F.M.** Quality of root canal fillings performed by undergraduate dental students on single-rooted teeth. *Eur J Dent Educ* 2006; 10: 67-72.
4. **Hayes, S.J., Gibson, M., Hammond, M., Bryant, S.T., Dummer, P.M.H.** An audit of root canal treatment performed by undergraduate students. *Int Endod J* 2001; 34: 501-505.
5. **Khabbaz, M.G., Protogerou, E., Douka, E.** Radiographic quality of root fillings performed by undergraduate students. *Int Endod J* 2010; 43: 499-508.
6. **Nair, P.N.** On the causes of persistent apical periodontitis: a review. *Int Endod J* 2006; 39: 249-281.
7. **Whitworth, J.** Methods of filling root canals: principles and practices. *Endod Topics* 2005; 12: 2-34.
8. **Er, O., Sagsen, B., Maden, M., Cinar, S., Kahraman, Y.** Radiographic technical quality of root fillings performed by dental students in Turkey. *Int Endod J* 2006; 39: 867-872.
9. **Eleftheriadis, G.I., Lambrianidis, T.P.** Technical quality of root canal treatment and detection of iatrogenic errors in an undergraduate dental clinic. *Int Endod J* 2005; 38: 725-734.
10. **Barrieshi-Nusair, K.M., Al-Omari, M.A., Al-Hiyasat, A.S.** Radiographic technical quality of root canal treatment performed by dental students at the Dental Teaching Center in Jordan. *J Dent* 2004; 32: 301-307.
11. **Balto, H., Al Khalifah, S., Al Mugairin, S., Al Deeb, M., Al-Madi, E.** Technical quality of root fillings performed by undergraduate students in Saudi Arabia. *Int Endod J* 2010; 43: 292-300.

TG Medical (Ireland)



Dr. Paul A. Tipton

B.D.S., M.S.c., D.G.D.P., R.C.S.
Specialist in Prosthodontics



Presents a 10 days (5 weekends) Practical Restorative Dentistry Course

Commencing: September 2012

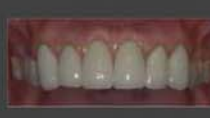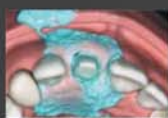
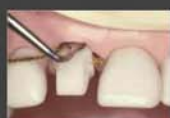Locations: Dublin and Belfast

Course takes place over five weekends

Minimum Referrals = Maximum Profits

The Restorative Dental training course is ideal for perfecting your knowledge and techniques in a field where dentistry is advancing at a rapid rate.

This course will give you a competitive edge in the market place.



Course Content

- Composites
- Bridge Design
- Implant Prosthetics
- Fee Planning
- Laboratory Techniques
- Marketing Strategies
- Smile Design
- Occlusion
- Adhesion
- Occlusal Splints
- Porcelain Veneers and Crowns
- Posts and Cores
- Tooth Preparation Techniques
- Private Practice Conversion
- Selling Techniques
- TMJ Treatment
- Tooth Wear
- Treatment Planning
- P.F.M. Crowns

Bookings

For further details please contact
Ralf Sander, TG Medical (Ireland)
Telephone: 01-9013194
Email: ralf@tgmedical.net.

The course contributes 70 (55 hours)
verifiable points for CPD.

"Having completed Paul Tipton's 1 year Restorative Course I can say that I found it extremely useful for general practice. I would recommend it to dentists looking to update or refresh their knowledge at a clinical and theoretical level. I found the occlusion aspect of the course brilliant and have applied them nearly every day since in practice. The variety of topics covered is broad and dips into all areas of dentistry"

Dr. Annette O'Donovan,
Limerick

"I found Paul to be an excellent lecturer and team motivator. His practical tips are especially useful in everyday practice"

Dr. Brian Byrne
Sligo

Classified advert procedure

Please read these instructions prior to sending an advertisement. Below are the charges for placing an advertisement for both members and non-members. Advertisements will only be accepted in writing via fax (01- 295 0092), letter or email (fionnuala@irishdentalassoc.ie). Non-members must pre-pay for advertisements, which must arrive no later than Friday, July 13, 2012, by cheque made payable to the Irish Dental Association. If a box number is required, please indicate this at the end of the ad (replies to box number X). Classified ads placed in the *Journal* are also published on our website www.dentist.ie for 12 weeks.

Advert size	Members	Non-members
up to 25 words	€75	€150
26 to 40 words	€90	€180

Non-members must send in a cheque in advance with their advert. The maximum number of words for classified ads is 40.

Only if the advert is in excess of 40 words, then please contact: **Think Media** The Malthouse, 537 North Circular Road, Dublin 1. Tel: 01-856 1166 Fax: 01-856 1169 Email: paul@thinkmedia.ie

Please note that all classified adverts **MUST** come under one of the following headings:

- ▶ Positions Wanted
- ▶ Positions Vacant
- ▶ Practices for Sale/To Let
- ▶ Practices Wanted
- ▶ Unwanted/Second Hand Equipment for Sale

Classified adverts must not be of a commercial nature. All commercial adverts must be display advertisements, and these can be arranged by contacting Paul O'Grady at Think Media, Tel: 01 856 1166.

POSITIONS WANTED

Experienced, conscientious dentist seeks full/part-time position in Co. Galway or nearby counties. Available to work late evenings and Saturdays. CV available on request. Please Email: perfecthealth345@gmail.com.

Experienced dentist with expertise in restorative and implant dentistry seeks part/full-time position in an established general or multidisciplinary practice, commencing July 2012. Email: rk dental@hotmail.com.

Locum dentist available from May 15 to June 30 in Munster region. Please contact Sue, Tel: 086-356 1042, or Email: creansusan@yahoo.co.uk.

Locum practice manager, qualified DSA, available immediately for part-time, holiday, maternity and emergency cover. Experienced and reliable. Implant and sedation qualifications. Tel: 087-678 1908, or Email: toothbrush@live.ie.

POSITIONS VACANT

Part-time dental associate required for busy Galway city centre dental practice. Will include evening and weekend work. Email: dental.practice@hotmail.com.

Part-time associate required to work two days at modern practice in North East. Tel: 042-933 7033.

Cork. Principal planning retirement seeks associate with view to sale in three to five years. Two very modern surgeries, third plumbed. Fully computerised, digital imaging, cart system, hydrocolloid, sterilisation room, laboratory. Please Email CV to: tangomikedelta@gmail.com.

Opportunity for enthusiastic associate to join progressive team in Navan, Co. Meath. A minimum of three years' experience is required for two to three days per week. Immediate start. Please respond with CV, by Email, to: boyndental@gmail.com.

Associate dentist required to work in Erbil. F/T, 140k net+. Paid vacation, accommodation plus travel included. Insurance. All candidates welcome. For details, Tel: 086-775 4402, or Email: danecanning@live.ie.

Dental associate with minimum of five years' experience required for state-of-the-art dental clinic in Dublin 2. Closing date: June 30, 2012. Email: carol.moroney@redmondmolloy.ie.

Gentle and friendly dentist wanted with general practice experience. Good communicator, enthusiastic and interested in working with a great team to provide great patient care, South Dublin City. Email CV and cover letter to: info@elitedental.ie.

Locum dentist required to cover maternity leave July to January, two to four days a week. Modern practice 20 minutes ex-Galway City. Computerised, digital radiography, including OPG. Excellent support staff, including hygienists. Email: reception@abbeytrinitydental.ie.

Dentist wanted for modern Dublin 4 practice. Exciting opportunity. Full book. Excellent package. Immediate start. Email: emmet@smiles.ie.

Enthusiastic dentist required to replace departing colleague. Busy practice; great staff and patients. Three-and-a-half days currently. Hygienist, OPG, etc. Email CV to: killorglindentist@gmail.com.

Experienced dentist required for part-time position in very busy computerised practice – Navan Dental Centre, Co. Meath. Kavo chair/fibre-optics, OPT and competent staff. Email: don@navandental.com.

Full-time dentist required for East Galway practice to treat private patients and PRSI. Must also be registered for medical card. Reply by Email with CV to: parkhousedental@gmail.com.

Excellent opportunity for experienced, caring and motivated dentist to join family dental practice. Initially part-time, 15 mins from Galway City. To start autumn 2012. Please Email CV to: phewatal@eircom.net.

Locum dentist required, Midlands area. Busy practice (fully computerised, digital imaging) to cover July 2-13 inclusive, also for sessional Saturday work. Replies by Email: jessopstreetdental@hotmail.com.

Locum dentist required for maternity leave from July to November 2012 in Athlone area. Please Email: campbelldental@yahoo.ie.

Dublin 7. Locum dentist required to cover holiday June 28 to July 6 inclusive. Busy practice, good support staff. Reply by Email to: rodcrichon@live.ie.

Periodontist, Norwich, UK. Full-time periodontist required to carry out implants and perio treatments. Specialist practice, clinical and administrative support. Tel: 0044-79-79594030, Email: hamedkarimi@yahoo.com, or log on to: www.perionorfolk.com.

Part-time dental surgeon required for sessional work. Saturday morning included. Busy multiple surgery practice outside Dublin. Experience essential. Immediate start. Apply with CV to: ghanly@centrichealth.ie.

Visiting orthodontist required for busy multiple practice outside Dublin. Apply with CV to: ghanly@centrichealth.ie.

Paediatric dentist Australia. We seek a paediatric dentist for our private specialist practice in subtropical Brisbane, Australia. An all-encompassing role, providing comprehensive management of the full

spectrum of paediatric cases. A great position, excellent remuneration, fabulous lifestyle. Email: info@pdgdental.com.au or log on to: www.pdgdental.com.au.

Dental nurse required for full-time position. Dental nurse with minimum of two years' experience required for city centre practice. Good terms and conditions. Permanent contract. For further information, Tel: 01-874 5418/874 9859, Mobile: 087-364 7875, or Email: surgerydental@hotmail.com.

Dental nurse required to cover leave in Kilkenny City orthodontic practice. Email CV or queries to: reception@kylemoreclinic.ie.

Qualified DSA required, full-time, for Dublin 18 dental practice. Email: am@cdpractice.com.

PRACTICES FOR SALE/TO LET

For sale: busy dental practice in Waterford City. 40 years established. Dentist retiring. Quick sale preferred. Tel: 051-382401, or Email: gilesraff@gmail.com.

For sale. Unique opportunity, exclusive dental practice and house, premium rural location in Western Australia. For more information, Email: badgie@wn.com.au.

SybronEndo

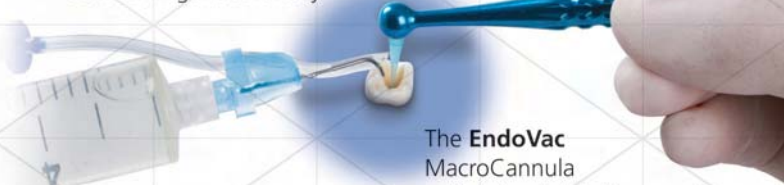EndoVac2

Apical Negative Pressure Irrigation System

SybronEndo is proud to offer the latest and safest technology in endodontic irrigation – the EndoVac system. This true apical negative pressure irrigation system presents a unique and safe new way to irrigate during root canal treatments.

Unlike positive pressure systems which use cannulas or side-port needles, the EndoVac is a true apical negative pressure system that draws fluid apically by way of evacuation. Irrigation solution and debris are sucked away from the apical foramen, providing exceptional cleaning while virtually eliminating the risk of irrigation accidents.

The EndoVac MDT delivers irrigant coronally.



The EndoVac MacroCannula pulls irrigant into the canal and evacuates gross debris.

EndoVac Starter Kit
€299*
*plus VAT of 19%



Learn more about the EndoVac, please contact Graham Parkin

Graham Parkin, Mobile: 00 44 (0) 797 004 5907, Email: Graham.Parkin@sybrondental.com

Diary of events

JOURNAL OF THE IRISH DENTAL ASSOCIATION

JUNE

Irish Academy of Aesthetic Dentistry – Meeting

June 22 *Fota Island House, Cork*
For further information, log on to www.iaad.ie.

Irish Society for Disability and Oral Health – Conference

June 22 *Dublin Conference Centre*

SEPTEMBER

Mouth Cancer Awareness Day

September 19 *Nationwide*
For further information, log on to www.mouthcancerawareness.ie.

South Eastern Branch IDA – Meeting: Interdisciplinary dentistry with long-term results

September 27 *Faithlegg House Hotel, Faithlegg, Co. Waterford*
Speaker is Dr Kenneth Lee from Canada. For more information or to RSVP, Email: traelacht@yahoo.co.uk, or info@waterfordperio.com.

IDA
MEMBERS
ONLY



ucc

Coláiste na hOllscoile Corcaigh, Éire
University College Cork, Ireland

Masters Degree in Dental Public Health – MDPH 2012-2013

Applications are invited for this 12-month Taught Masters degree programme, commencing September 2012. The course is designed to facilitate health professionals in current employment with contact teaching hours Thursday evenings and Friday all day. The curriculum prepares experienced health professionals to assume leadership roles as members of multidisciplinary teams and to be able to develop, implement and evaluate programmes which have an impact on the health of the population. Subject areas to be covered include Public Health, Decision Analysis in Healthcare and Healthcare Financing, Applied Social Studies, Health Promotion, Preventive Dentistry, Health Service Structures and Management.

For informal discussion, please contact:
Dr Máiréad Harding, Tel: (+353) 21 4901210
Email: m.harding@ucc.ie

Applicants are required to have a BDS degree of the NUI or equivalent degree. (Note: Health care professionals holding relevant degrees may also be considered).

Closing date for EU applicants is: Wednesday, June 29, 2012.
Applications should be made online at <http://www.pac.ie/ucc>

Fees for EU Students: €5,850

Application queries should be directed to the Graduate Studies Office,
University College Cork, Tel: (+353) 21 4902876
Fax: (+353) 21 4901897 Email: graduatestudies@ucc.ie

BDA Seminar Series – Crown and bridgework: improve your skills, update your knowledge and get the best results

September 28 *Belfast*
To view the full programme and to book, contact Rebecca Hancock, Tel: 020-7563 4590, or Email: events@bda.org. CPD verifiable.

Irish Academy of American Graduate Dental Specialists (IAAGDS) – Annual Scientific Conference

September 29 *Radisson Blu Hotel, Golden Lane, Dublin 2*
9.00am-1.00pm (short lectures). Free to attend for all dentists. Please contact Dr Traelach Tuohy for more information, Email: traelacht@yahoo.co.uk.

OCTOBER

The European Society of Microscope Dentistry (ESMD) Congress: 'Open Eyes, Open Mind'

October 4-6 *Berlin, Germany*
For further information, log on to www.esmd.info.



HSE Group of the IDA – Annual Seminar

October 10-12 *The Galway Bay Hotel, Galway*
For further information, contact IDA House, Tel: 01-295 0072.

4th World Implant Orthodontic Conference

October 10-13 *Hilton Hotel, Sydney, Australia*
For further information, log on to info@wioc2012.com.

Faculty of Dentistry of the Royal College of Surgeons in Ireland – 2012 Annual Scientific Meeting: 'An Overview of Aesthetic Dentistry'

October 26-27 *RCSI, St Stephen's Green, Dublin 2*
Further information to follow when available.

21st Congress – International Association for Disability and Oral Health

October 28-31 *Melbourne, Australia*
For further information, log on to www.iadh2012.com.

NOVEMBER

Orthodontic Society of Ireland – Meeting

November 23-24 *K Club, Co. Kildare.*
Speakers are Drs Marco Rosa, Renato Colconi and Mirco Raffaini, on 'The face and occlusion in the diagnostic process: new strategies for treatment from mixed dentition to surgery'.

The Asia Pacific Orthodontic Conference

November 29 to December 2 *New Delhi, India*
For further information, log on to www.8thapoc-47thioc.in.


NEW



INTRODUCING **LISTERINE®** **TOTAL CARE ZERO**

Highly effective yet alcohol-free for a less intense taste

LISTERINE® TOTAL CARE ZERO is alcohol-free yet retains the LISTERINE® brand's 4 essential oils. So it has a soft taste¹ but it kills up to 99% of plaque bacteria in vitro, more than the leading alcohol-free daily use mouthwash brand.² In addition, TOTAL CARE ZERO contains 220 ppm (0.05%) fluoride



**POWERED BY
4 ESSENTIAL
OILS**

**CONTAINS
220 ppm
FLUORIDE**

**CONTAINS
ZINC
CHLORIDE**

with high uptake³ for extra enamel protection, and zinc chloride to reduce calculus formation⁴ and help keep teeth white. So when patients want a less intense, alcohol-free mouthwash, why not add LISTERINE® TOTAL CARE ZERO to their oral care routine?

LISTERINE® **TOTAL CARE ZERO**

Adds zero alcohol to the LISTERINE® TOTAL CARE range

Suitable for patients 6+.

References: 1. Data on file 45348, McNEIL-PPC, Inc. 2. Data on file, microbiology dossier, McNEIL-PPC, Inc. 3. Data on file 103-0214, McNEIL-PPC, Inc. 4. Le Geros RZ et al. *Am J Dent* 1999; 12(2): 65-71.

LIS/012/00

Two ingredients that make Colgate Total one of a kind.



Colgate Total provides 12 hour clinically proven antibacterial protection and is approved by the Irish Dental Association

www.colgateprofessional.ie