

Volume 62 Number 2
April/May 2016

JIDA

Journal of the Irish Dental Association
Iris Cumainn Déadach na hÉireann



irish dental association

INSIDE TRACK

Three case reports demonstrating treatment of relatively complex orthodontic cases using a completely customised lingual appliance

Introducing LASERS

Laser
Discovery
Courses

Dublin: 28th June 2016

Cork: 13th July 2016

FREE to attend

Call for more
details



**Attend one of the Laser Discovery Events
to avail of special offers on the Laser range**

For more details on our laser range please call your local equipment specialists:
Jim Way 086 835 3812 or Richard Kenny 086 606 9628

Taking care of everything dental.

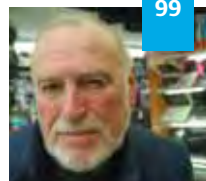
henryschein.ie



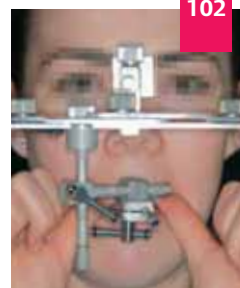
82



93



99



102



126

- 73 **EDITORIAL**
- 75 **PRESIDENT'S NEWS**
- 76 **NEWS**
IDENTEX 2016; a 1916 story; and, HSE Annual Seminar
- 78 **QUIZ**
- 82 **INTERVIEW**
Chief Scientific Adviser and former dentist Prof. Mark Ferguson
- 87 **PRACTICE MANAGEMENT**
There's no such thing as a quick fix
- 90 **BUSINESS NEWS**
The latest on new products and services
- 93 **CONFERENCE PREVIEW**
What to expect in Galway this year

97 MEMBERS ONLY | MEMBERS ONLY | MEMBERS ONLY

- Supreme Court judgement; pensions; and, maintaining records
- 102 **CLINICAL FEATURE**
Articulators, face bows and interocclusal records
- 106 **PEER-REVIEWED**
Three case reports demonstrating treatment of relatively complex orthodontic cases using a completely customised lingual appliance
J Buckley
- 114 The path of least resistance in oral surgery
L Fee
- 121 **ABSTRACTS**
- 123 **CLASSIFIED**
- 126 **MY IDA**
Dr Mairéad Browne



DON'T MISS
Conference lecture
Friday April 22
Mary Aiken

EDITOR **Professor Leo F.A. Stassen**
FRCS (J), FDSRCS, MA, FTCD, FFSEM, FFDRCSI, FICD

DEPUTY EDITOR **Dr Dermot Canavan** BDentSc, MGDS(Edin), MS(UCalif)

EDITORIAL BOARD
Dr Iseult Bouarroudj BDS NUI
Dr Michael Crowe BSc BDentSc DPDS (Bristol)
Dr Peter Harrison BDentSc MFD DChDent
Dr Mark Kelly BA BDentSc
Professor Christopher D. Lynch BDS PhD MFDRCSI
 FDS (RestDent) RCSI FACD FHEA
Ruth Moore RDN, BSc Management & Law,
 MIA Dip Journalism
Donna Paton RDH
Dr Ioannis Polyzois DMD, PhD, MDentCh, MMedSc
Dr Ciara Scott BDS MFD MDentCh MOrth FFD (RCSI)
Dr Seamus Sharkey BDS NUI FRACDS (Syd) MFDRCSI
 DChDent (Prosthodontics) FFDRCSI
Dr Simon Wolstencroft BDS FDSRCS MScD MOrth FDSOrth

IDA PRESIDENT **Dr Anne Twomey**
IDA CHIEF EXECUTIVE **Fintan Hourihan**
CO-ORDINATOR **Fionnuala O'Brien**

The *Journal of the Irish Dental Association* is the official publication of the Irish Dental Association. The opinions expressed in the *Journal* are, however, those of the authors and cannot be construed as reflecting the Association's views. The editor reserves the right to edit all copy submitted to the *Journal*. Publication of an advertisement does not necessarily imply that the IDA agrees with or supports the claims therein.

For advice to authors, please see: www.dentist.ie/resources/jida/authors.jsp
 Published on behalf of the IDA by Think Media, 537 NCR, Dublin 1
 T: +353 1 856 1166 www.thinkmedia.ie

EDITORIAL **Ann-Marie Hardiman, Paul O'Grady**
DESIGN/LAYOUT **Tony Byrne, Tom Cullen, Ruth O'Sullivan**
ADVERTISING **Paul O'Grady** paul@thinkmedia.ie

Irish Dental Association Unit 2 Leopardstown Office Park, Sandyford, Dublin 18.
 Tel: +353 1 295 0072 Fax: +353 1 295 0092 www.dentist.ie
 Follow us on Facebook (Irish Dental Association) and Twitter (IrishDentists).



Total average net circulation 01/01/15 to 31/12/15: **3,180 copies** per issue.
 Circulated to all registered dentists in the Republic of Ireland and Northern Ireland.

Colgate®

COLGATE TOTAL®
PROVIDES WHOLE
MOUTH PROTECTION*
AGAINST PLAQUE²

✓ **TEETH**

✓ **GUMS**

✓ **CHEEKS**

✓ **TONGUE**

- Daily toothbrushing with a fluoride toothpaste† removes dental plaque and delivers fluoride to protect hard tissues
- The rest of the mouth can provide a reservoir for plaque recolonisation

**OFFER YOUR PATIENTS WHOLE-MOUTH
PROTECTION AGAINST PLAQUE***

For further information, visit www.colgateprofessional.co.uk

*In addition to containing 1450ppm fluoride for cavity protection, Colgate® Total® contains triclosan/copolymer to provide 12-hour antibacterial protection for teeth, gums, cheeks, and tongue.

†Defined as non-antibacterial fluoride toothpaste.

References: 1. Fine DH, Sreenivasan PK, McKiernan M, et al. *J Clin Periodontol.* 2012;39:1056-1064.

Clinically proven protection, Irish Dental Association approved



Colgate®

YOUR PARTNER IN ORAL HEALTH

www.colgateprofessional.ie



Prof. Leo F. A. Stassen
Honorary Editor

Articulating our views

The Chief Scientific Adviser, the Supreme Court, the Annual Conference and terrific clinical and scientific papers feature in this edition.

The Supreme Court has decided that the HSE is entitled to take whatever steps are necessary to live within its budget, even though that budget might be unclear, and external healthcare providers are partners in the provision of services using that budget. Therefore, even though we feel strongly that the treatment of dentists and our patients was reprehensible, it was legal. Our President Dr Twomey comments on the judgement in her President's Message. It is, however, notable that it was the Association that was willing to fight on behalf of oral healthcare in Ireland.

Chief Scientific Officer

Professor Mark Ferguson is a distinguished scientist who is the Director General of Science Foundation Ireland and Chief Scientific Adviser to the Government. It is a matter of pride to our profession that he is a dentist and a matter of satisfaction that he spoke to our *Journal*. His thoughts on Ireland's scientific community and his perspective on dentistry make for fascinating reading.

Awards expanded

We are pleased to note the expansion of the Sensodyne Sensitive Dentist of the Year competition to include the dental team of the year. The dental profession has never before had a formal channel of communication for patients to express their appreciation of dentistry to a third party. The *Journal* together with GSK, the makers of Sensodyne, has given patients that new means of communication. Our patients have provided the most wonderful testament to the value of the work we do every day. This year's Awards will be launched at the Annual Conference and will be open to entries from May 1. I urge all of you to register for the pack for the Awards (use the reply-paid postcard from around this edition).

Packed conference

And speaking of the Annual Conference, this year's event takes place in Galway with the theme 'Dentistry into the future'. There is a terrific pre-conference programme, and a packed programme of lectures including clinical workshops, the Dr Joe Moloney Award, and the Dr Tony Costello Memorial Medal. Our *Journal* lecture is being given by Mary Aiken on the psychology of cyberspace, and the social programme gives everyone a chance to catch up.

There is a superb trade show presenting new products and developments in dental technology. And once again, the Editorial Board expresses its gratitude for the excellent advertising support we receive from the trade. We also urge you to support those companies that advertise in the *Journal* – making it possible for us to continue to improve the *Journal* – the only Irish-produced publication for Irish dentists.



Importance of articulation

Dr Paul Quinlan has provided an excellent clinical feature on management of articulation in the dentition. It is one of the most important aspects of modern dentistry, with failures resulting in problems for patients. Dr Quinlan outlines the proper use of articulators, face bows and interocclusal records.

We also publish a scientific paper from Dr John Buckley reporting three complex orthodontic cases where a completely customised lingual appliance was used. The context for the paper is research from 2014, which revealed that 51% of GDPs believe that only "simple cases" can be treated with lingual appliances. The paper demonstrates that when properly applied lingual appliances can achieve a high standard of result.

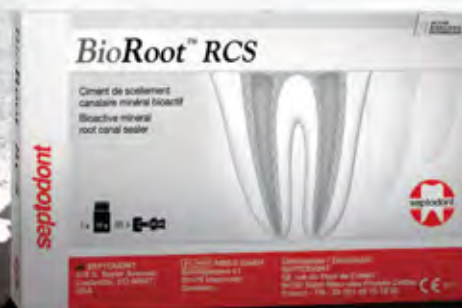In our other scientific paper, Dr Laura Fee encourages the dental profession to prescribe to optimise the use of antibiotics in oral surgery. Antibiotic stewardship programmes are recommended to help reduce the emergence of infections that are multidrug resistant.

OBTURATION
INNOVATION

BioRoot™ RCS

Root Canal Sealer

Superior seal and so much more



We know that failure of a root canal treatment can have severe consequences for you and your patients.

With BioRoot™ RCS, move to a new generation of mineral obturation offering you an innovative combination of features:

- Outstanding Seal
- Antimicrobial properties
- Promotes peri-apical healing
- Easy obturations and follow-up

**ACTIVE
BIOSILICATE
TECHNOLOGY**

BioRoot™ RCS. Succeed.

For more information contact:

information@septodont.co.uk

+44 (0)1622 695520/+44 (0)7836 255274

www.septodont.ie





Dr Anne Twomey
IDA President



Bitter judgement doesn't sweeten any pill

President on advocating for better oral health for all, even with almost no State support.

In my final President's Message it is opportune to review a number of significant recent developments, which will play an important role in setting the agenda for the Association and the Union in the years ahead. The decision of the Supreme Court to reject the appeal lodged by Drs Martin Reid and James Turner was, of course, bitterly disappointing. The Court has decided that the HSE is entitled to take whatever steps are necessary to live within budget though there is no clearly defined budget in place. This is clearly a matter of grave concern for our members and their patients.

For any scheme to prosper the HSE will need to take steps to remedy the damage done by the initial decision taken in 2010 to slash the benefits available to medical card holders and the implications this has had for the income of our members. And while many of our members clearly do not want to see a return to the scheme as it operated in 2010, it is important also that any replacement of this clearly unfit scheme is agreed with the IDA and is operated in a fair and transparent manner, and with reasonable opportunities for dentists to communicate any changes in entitlements to patients in an orderly fashion. There also need to be clear pathways in cases where general practitioners cannot treat patients on the terms on offer by the HSE.

Promoting oral health

The publication of the judgement came in the same week as we saw publication by the Irish National Teachers Organisation (INTO) of an article I prepared on the dangers of hidden sugars in food and drinks, and also setting out good oral health practices. This was a very significant advance in our advocacy efforts and I wish to thank the INTO for its assistance.

In a similar vein we are engaged in joint advocacy initiatives with a number of other professional organisations outside of dentistry and this is an approach which I have no doubt will find favour and greater impetus in the years ahead. It is also noteworthy that the report of the Food Safety Authority only serves to highlight the issue of hidden sugars. The damage they cause is moving steadily up the agenda here in Ireland. It is important that as expert health professionals we ensure that dentistry is front and centre in this discussion.

Government policy

With the current uncertainty on the establishment of a new Government, we are waiting to see what signals emerge as to the direction a new Minister for Health might take in reviewing oral health. The protracted delays in completing the oral health review serve to frustrate the efforts many of us have made.

The Association has advocated with other professional representative bodies for a significantly different approach to maintaining and promoting good oral health. At the very least we hope to see the publication of the Oral Health Policy by the end of this year. Likewise, we hope that with a new Government in place we will see priority given to publication of a new Dental Bill. This is long overdue and can only be of assistance in promoting the highest standards in dentistry.

At our recent Council meeting the Association nominated Ms Linda O'Shea Farren as a candidate for the NUI Cultural & Educational Panel, and I encourage all of our members with a vote in the NUI elections to offer the highest preference to her. She made a heartfelt and captivating presentation to the Council recently. We were left in no doubt as to her willingness to promote the standards of care that the Association endeavours to promote.

The Conference

Finally, I wish to thank sincerely all who have helped me in the Presidency over the past 12 months. Time truly has flown by and it will be with a great sense of relief and satisfaction that I hand over to Dr PJ Byrne. It really will be with great excitement and anticipation that we head down to Galway for what promises to be an outstanding Conference. Once again, I look forward to meeting many of my friends and colleagues in April and to looking back in the years ahead to what has been undoubtedly one of the most interesting periods of my time in professional practice. I would strongly encourage all branches, and indeed members, to seriously consider getting involved in the Association in the years ahead. It has been a truly educational experience, and while there is plenty of hard work, there is lots of fun to be had too!

With best wishes, I look forward to seeing you all in Galway.




Fun Run 2015

Get the runners on and the shorts and t-shirts out for our Fun Run 2015 at the Annual Conference. This year, runners will take to the roads of beautiful Galway City for a 5km run on Saturday April 23, starting at 8.30am. Walk, jog or run it – it's up to you! All proceeds to St Vincent de Paul.

HSE Seminar 2016

The Annual HSE Seminar will head back Shannonside this year to the beautiful town of Athlone. The event will take place on Thursday and Friday, October 6 and 7, at the Sheraton Hotel in the town. A wide range of speakers will present on various topics over the two days, with a full trade show present on Friday. This is a must attend event for any dentist employed by the HSE. Put the dates in your diary now!



IDENTEX 2016

For the third year running, the Irish Dental Association will partner with the IDTA (Irish Dental Trade Association) and will run hands-on courses, workshops and lectures as part of IDENTEX 2016. IDENTEX will host over 60 trade stands on Friday and Saturday, September 17 and 18, and members of the dental profession can visit free of charge.

To register for the IDENTEX trade show, log on to www.idta.eu. More details and a booking form for courses will be available shortly.

Sensitive Dentist of the Year 2016

Will you be Ireland's Sensitive Dentist of the Year 2016? The Gala Awards Ceremony will take place at the glamorous Concert Hall at Dublin's RDS on Saturday, December 3 next. Make sure you are nominated!

Any patient can nominate their dentist for the Award, either online or on the postcards available from GSK at their stand in Galway at the Annual Conference.

This year, we are delighted to announce that we will have a new award for Sensitive Dental Team of the Year.

Wrigley's grants programme

The Irish Dental Association, in conjunction with the Wrigley Company Foundation, is delighted to announce a range of dental support grants to fund worthwhile oral healthcare projects around the country. Applications have been submitted and the winning applicants will be announced over the next few weeks.

Dental support grants are available to help fund specific community service projects with a focus on improving oral health and educating participants in this area. Up to seven projects across the country will be funded, with one project receiving funding of €15,000, three receiving €5,000 and three receiving €2,500.

The scheme was open to all IDA members to apply.

Dentists cycle in aid of cancer research



Dr Peter Casey and colleagues from Beechwood Dental in Ranelagh will be cycling from Paris to Nice in France in September to raise funds for the ARC Cancer Support Centre in Dublin. Peter's brother and partner in their dental practice, David (left), died from cancer last year. Peter will be joined by Beechwood colleagues, Alex and Greg Creavin, on the 750km tribute cycle.

You can support the cyclists and the centre by donating by card, cash or cheque at Beechwood

Dental's reception desk. Alternatively, you can make your donation online at www.justgiving.com/DavidCasey9.

The ARC Cancer Support Centre offers support and counselling to people with cancer and those around them. Anyone diagnosed with cancer, no matter where they live, is welcome at ARC. Their aim is: "To offer support, complementary therapies and counselling services in a warm and welcoming environment to people with cancer and those who care for them".

Peter and his colleagues would be most grateful for any support from their friends in dentistry.

South Eastern Branch

The South Eastern Branch recently had a very successful Annual Scientific Day at the Ormonde Hotel, Kilkenny. A full trade show was present and over 50 delegates were in attendance. There were some very interesting topics discussed on the day, including surgical extractions, managing patient expectations, and contemporary orthodontics.


Annual Conference 2017

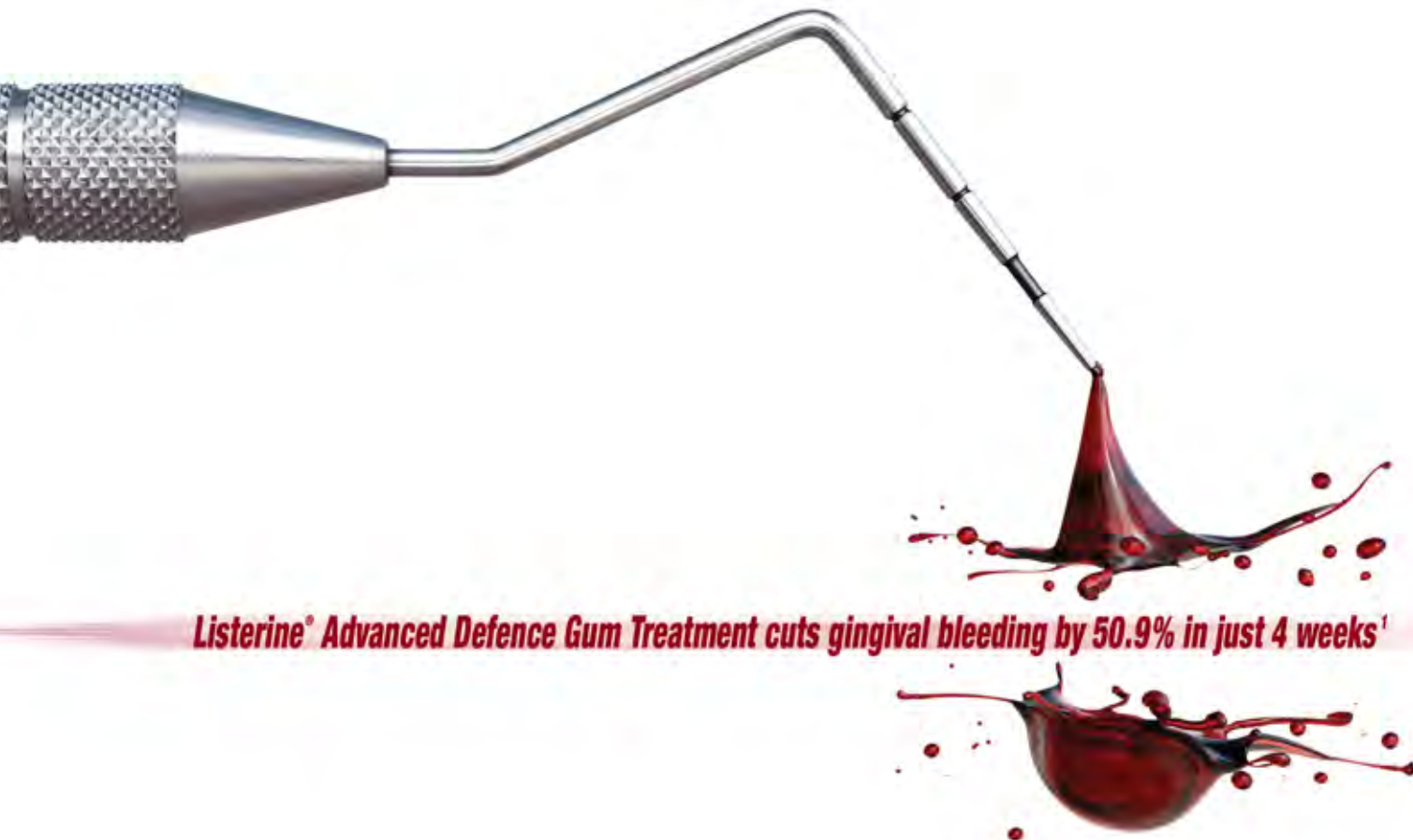The Annual Conference returns to the Marble City, Kilkenny, and the stunning Lyrath Estate Hotel in May 2017. The event takes place from May 11-13.

So long, farewell to Colm Hayes of 3M

Colm Hayes, whom most of you will know, is moving on from his role with 3M Oral Care. Colm has worked with 3M Oral Care for eight years, covering Munster/Southern counties and based in Cork. The Annual Conference will be his last official dental event. Colm is moving to another role in a new business development with 3M in the Medical Materials & Technologies Division.

Thanks Colm and best of luck with the new position!





Listerine® Advanced Defence Gum Treatment cuts gingival bleeding by 50.9% in just 4 weeks¹

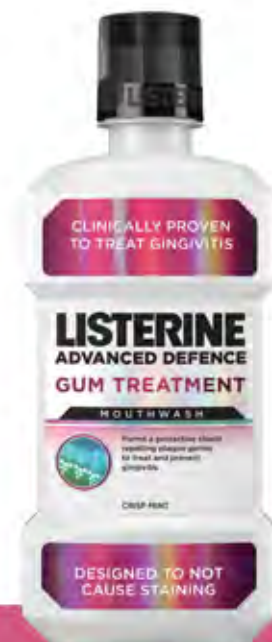Introducing the latest in the professional range from LISTERINE® – a twice-daily mouthwash **clinically proven to treat gum disease as an adjunct to mechanical cleaning.**

Advanced Defence Gum Treatment is an alternative to chlorhexidine-based remedies. It's formulated with unique LAE (Ethyl Lauroyl Arginate) technology that forms a physical coating on the pellicle to prevent bacteria attaching, and so interrupts biofilm formation.

When used after brushing it treats gum disease by reducing bleeding; 50.9% ($p < 0.001$) in only 4 weeks.¹

In addition, Advanced Defence Gum Treatment is **designed to not cause staining.**²

PART OF THE
LISTERINE®
ADVANCED DEFENCE RANGE



References:

1. Bleeding Index Reduction DOF 1 – 2013 (LAEBRA0001), 50.9% reduction in whole-mouth mean Bleeding Index at 4 weeks.
2. DOF 2 – 2013 (LANKPL0006).

IRE/LI/15-1170

Advanced Defence against gum disease

DDUH students organise CPD fundraiser

The fourth-year students of the Dublin Dental University Hospital (DDUH) have come up with a fantastic initiative to raise funds for their charitable work abroad.

DDUH students will host a CPD event on May 17 in the Hospital to raise funds for DOVE (Dental Overseas Voluntary Elective).

Through DOVE, fourth-year Dublin dental students undertake dental voluntary programmes in developing countries, and perform free dental care for people in need of these services. The students travel during the summer of their fourth academic year to take part in this programme.

The speakers on the night will be Dr Kirsten Fitzgerald, who will discuss the fundamentals of paediatric dentistry for the GDP, and Drs Michael Freedman and Una Lally, who will give a lecture on the placement and restoration of zygomatic implants.

The night will commence at 6.30pm in the Common Room in the DDUH with a drinks reception, canapés and some great raffle prizes up for grabs. Lectures will commence at 7.00pm and finish at 8.00pm/8.30pm.

The cost of the evening is €50 for dental professionals and €10 for students. The event is CPD verifiable, with two CPD points awarded by the Dental Council for attendance. So come along and gain some valuable CPD points, while supporting a fantastic cause! For further information, please contact Harriet Byrne at harriet.byrne@dental.tcd.ie.



IDA nominates candidate in Seanad election

Linda O'Shea Farren has been nominated by the Irish Dental Association as a candidate seeking election to the Seanad. If elected, Linda says that she will be happy to highlight the many issues currently facing the dental profession in Ireland. We wish Linda well in her campaign.

Reaching out to teachers

IDA President Dr Anne Twomey recently published an article in *InTouch*, the magazine of the Irish National Teachers Organisation (INTO), on the dangers of hidden sugars and the importance of oral health for our children.

The article points out that tooth decay can impact a child's performance at school, as pain and exhaustion (from lack of sleep) are certain consequences of severe decay. Time absent from school to attend dental visits is another issue. The article contains advice for primary school teachers on encouraging pupils to learn about the dangers of hidden sugars, and to drink water or milk rather than fizzy drinks and juices.

This article is part of the IDA's ongoing efforts to work with relevant organisations to raise the profile of oral health in general, and the dangers of sugar in the diet in particular.

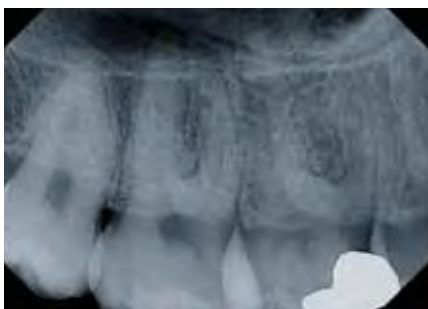

FIGURE 1: Pre-operative radiograph.

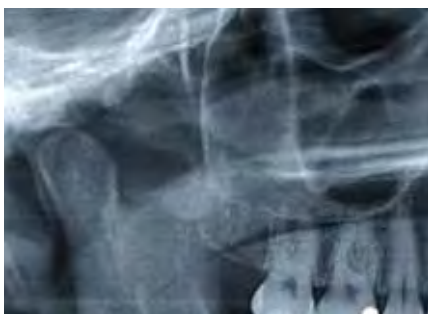

FIGURE 3: OPG at seven days.

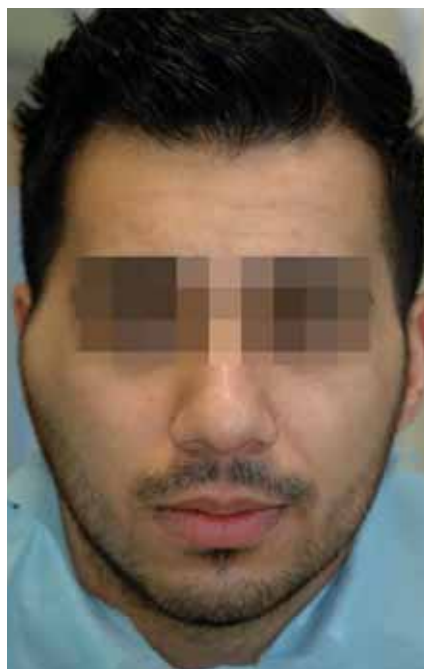

FIGURE 2: Clinical presentation at seven days.

Quiz

Submitted by Dr Mark Kelly

A fit and healthy 25-year-old male attends the surgery complaining of moderate pain in his upper right wisdom tooth region. He has pain without swelling in his right TMJ, and moderate pericoronitis relating to his fully erupted UR8 (Figure 1). A simple extraction of UR8 was carried out – the tooth elevated out uneventfully.

Seven days later the patient returned complaining of a hard swelling and pain around his right TMJ and ascending ramus. He now has limited opening of 17mm, with the opening becoming progressively worse since the extraction. The extraction site at UR8 was healing well and was clean (Figure 2).

Questions

1. What is this painful swelling and what causes it?
2. What treatment should be carried out?

Answers on page 122



SENSODYNE



journal of the irish dental association
Iris Cumainn Déadach na hÉireann



WILL YOU BE IRELAND'S MOST SENSITIVE DENTIST OR DENTAL TEAM IN 2016?

The search for the
2016 Sensodyne Sensitive Dentist and Dental Team of the Year
has commenced.

This awards programme showcases the marvellous work of Irish dentists and
dental teams – and all through the words that mean most: those of your patients.

Please note the closing date is September 30 and that the Gala Awards Ball is on December 3.
Send back the postcard from the wrap around this *Journal* and you will receive your
Sensodyne Sensitive Dentist and Dental Team of the Year nomination pack.



For more information and for full terms and conditions
visit www.sensodynesensitivedentist.ie



Changes at Dental Protection



Dr Raj Rattan



Dr John Tiernan

Dr Raj Rattan has been appointed as the new Dental Director of Dental Protection to succeed Dr Kevin Lewis who is stepping down, while Irish dentist Dr John Tiernan, Executive Director of Member Engagement at MPS, will also retire shortly.

Dr Rattan said: "Having

been in practice for over 30 years, I understand our members' fears, aspirations and the issues they are facing. We are here to support and educate members, and protect them from risk throughout their career. I look forward to working closely with my colleagues in helping to shape a better future for our dental members and for the profession. I believe that by helping dentists in their professional careers, we are also creating a happier and safer environment for patients."

Dr John Tiernan, Executive Director of Member Engagement at MPS, will retire


in July 2016, after 23 years supporting doctors and dentists in dentolegal and medicolegal issues. Prior to working at MPS John qualified in dentistry at Trinity College Dublin, and spent 15 years in full-time practice. He joined MPS in 1993 and his career has spanned numerous roles. As Executive Director of Member Engagement for the MPS group, he has been pivotal in changing MPS's education programme and helping over 10,000 members improve their interactions with patients. John currently leads MPS's educational services, communications and commercial departments, with a team of over 130 staff, overseeing the delivery of support and education services for more than 300,000 members around the world.

Dr Tiernan said: "It has been a great pleasure to have spent a significant part of my career supporting colleagues in Ireland, which is particularly special as I was born and educated there. In retirement I will continue to push for change to the Irish healthcare system to make it fairer for both healthcare professionals and patients alike". Simon Kayll, Chief Executive at MPS said: "John is well known amongst our members for his passion for education and commitment to supporting medical and dental members around the world. Perhaps what members are less aware of is the respect he commands among his colleagues and his drive for continuous improvement in the service we provide to our members. For more than 20 years John has been a respected leader, colleague, friend and mentor to many at MPS and he will be missed by us all".

Dentanet Ltd.

DENTAL LABORATORY SERVICE

Probably the best Quality
Crowns and Bridges
available in Ireland



22 Tralee Road Castleisland
Co. Kerry

Tel : 066 7143964 Mob:087 3324779

Email/: dentanet@eircom.net
www.dentanet.ie



Reporting to members

The Annual Reports for 2015 for both the Association and the Union have been sent to members via email. They include the motions to be discussed at the Annual General Meetings on April 21 next.

The Union Annual Report includes reference to €500m of income lost by dentists since 2010, and the fact that 80% of members favour renegotiation of the Dental Treatment Services Scheme contract. In relation to the Dental Treatment Benefits Scheme, 82% of members surveyed would not favour a return of scale and polish at the fee that previously applied.

The Association's Annual Report includes reports from all the officers, branches and committees, and notes that 10,000 children (under 15) are hospitalised for extractions under general anaesthetic each year. It also records the need for a new foundation training scheme, and the need to prioritise dental care for under sixes.

A casualty of the Rising

Dr Conor McAlister recalls the story of a dentist who was killed during the Easter Rising, with thanks to Maedbh Murphy and Fionnuala Jervis of RCSI for their assistance.

“Poor young Hyland, our dentist, was killed in his garden by a stray bullet.”
Letter to Emily Winifred Dickson, Fellow of RCSI, from her aunt who lived on Northumberland Road.


It is estimated that 485 people were killed during the Easter Rising of 1916. Of those who died, 262 were civilians. One of these civilians was a 29-year-old dentist from Dublin called Charles Hyland.

Charles Hachette Hyland was born in 1887, the eldest of five children. The Hyland family lived in number 5 Percy Place, close to Mount Street Bridge. His father, also Charles, was manager of the Gaiety Theatre. Young Charles was educated at Catholic University School in Leeson Street. He graduated in dentistry from the Royal College of Surgeons in Ireland in 1907. As a dental student at the Incorporated Dental Hospital of Ireland, Charles won the senior prizes in dental mechanics and in dental surgery. On graduation, Charles set up practice at 3 Percy Place, next door to his family home and also joined the assistant staff of the Dental Hospital. At the Dental Hospital, his efficiency, modesty and courtesy gained the admiration and goodwill of all who were brought in contact with him (*British Dental Journal* obituary 1916).

Charles married Kathleen Slyne of Slyne Couturiers, 71 Grafton Street. They had one son, another Charles, in 1915. At the outbreak of the Rising, Hyland sent his wife and their young son to safety in Blackrock.

Heavy casualties

On Easter Monday 1916, a small detachment of the third battalion of the Irish Volunteers took up strategic ambush positions around Mount Street, Northumberland Road and Haddington Road. On Tuesday night and Wednesday morning, British reinforcement troops began arriving at Dun Laoghaire, then Kingstown. On Wednesday morning, April 26, two battalions of the Sherwood Foresters marched, in glorious sunshine, towards the city centre. Some 300 yards from Mount Street Bridge, the troops came under fire from 25 Northumberland Road initially and then other locations. The British suffered heavy casualties against the small number of well positioned insurgents. On the evening of Wednesday April 26, when the battle was at its fiercest, Charles Hyland donned his white coat and joined a number of nurses and other staff from Sir Patrick Dun’s Hospital as they tried to help the wounded soldiers. Showing immense bravery, Charles moved from one wounded man to another, rendering what emergency aid he could. They used quilts as stretchers and, at one stage, Hyland enlisted the help of a young man with a cart to transport the injured men to hospital. Both sides withheld fire while the wounded were attended and assisted to safety and then the battle began again. In the course of the hours the battle raged, Hyland and the nurses intervened, again and again, to aid the wounded.



Charles Hyland emerged unscathed from this frightening ordeal. At 3.00am the next morning, Thursday April 27, it appears the military took possession of his house and ordered everyone in it to the lower rooms. Charles, who was anxious to join his wife and child in Blackrock, opened his back door at 4.30am. He was immediately shot by a

single bullet from across the street. He was one of several civilians killed at the battle of Mount Street Bridge. His loss was mourned by his colleagues and ‘the host of friends he had gathered around him by his happy disposition.’

His gravestone in Glasnevin Cemetery and a memorial in St. Mary’s Church, Haddington Road read as follows: “Charles Hachette Hyland L.D.S. RCSI Accidentally killed during the Dublin Rebellion, April 27, 1916. May he rest in peace.”

...and was active in Gaelic and Irish Volunteer circles in London. Before the rising he was engaged in the drapery trade in Dublin. He was wounded at Church street, and died in the Richmond Hospital.

HYLAND, C. Hachette, L.D.S., R.C.S.I., was shot dead while looking out of his back garden door at 3 Percy place, Northumberland road, on the morning of Thursday, 27th April. The deceased gentleman, who was the son of Mr. Charles Hyland, manager of the Gaiety Theatre, Dublin, was aged 29 years and two months. He had been engaged in the practice of his profession for eight years, and had established a reputation that secured his recognition as one of the representative leaders of the younger generation of dental surgeons in Ireland. He was a member of the staff of the Incorporated Dental Hospital of Ireland. On the evening of Wednesday, 26th April, when the battle at Mount street Bridge was at its fiercest, and the Sherwood Foresters had sustained heavy losses, Mr. Hyland donned his white coat and went into the firing line, where he worked gallantly for several hours, rendered valuable aid to the wounded men, and assisted the unfortunate victims of the battle into a place of safety. From this ordeal he emerged unscathed, and next morning, while looking out of his garden gate, he had the great misfortune to be shot. His loss was deeply deplored by his professional brethren and the host of friends he had gathered around him by his happy disposition.

JOZE, Thomas Moran, a well-known chemist, having places of business in Dame street and Arran quay, was shot dead by the rebels when he was going to his private residence at Arran quay. Mr. Joze was afflicted with deafness, and it is supposed that he did not hear the challenge of the rebel sentry, who fired upon him.

KELLY, John, who assisted Francis Macken in the conduct of the Irish class at Rathfarnham, was educated at the Christian Brothers' schools, Kingstown. He was shot dead



Science of the times

A dentist, Professor Mark Ferguson, is the Chief Scientific Adviser to the Government. He has pushed for a strong focus on the impact of research and believes this is a fantastic time to be a scientist.

"I always wanted to be a dentist. Always. It was the combination of engineering and being a doctor, of treating people and using precise construction that appealed to me." So says Professor Mark Ferguson, now Director General of Science Foundation Ireland (SFI) and Chief Scientific Adviser to the Government of Ireland. And so he became a dentist, gaining a first class honours BDS from Queen's University Belfast in 1978. Along the way he took an intercalated BSc in 1976, and discovered a love for research. In his case, research into cleft lip and palate conditions, using alligators and crocodiles because they develop in the egg and have a palate. Doing his PhD, he discovered that alligators and crocodiles have temperature-dependent sex development. Eggs that are kept at 30°C develop into females, while those kept at 33°C develop into males. At temperatures in between, you get a mix of males and females. In Queen's, a Winston Churchill Fellowship allowed him to spend six months in the USA collecting eggs and doing his research. On his return, while still doing his PhD, he became a lecturer in anatomy, embryology and histology. He gained his doctorate in 1982 and two years later was appointed Professor of Basic Dental Sciences at the University of Manchester. He believes he was, at the time, the youngest professor in Britain. As soon as he arrived, he became involved in the reorganisation of 16 life science departments into four and in 1986 became head of one of those departments – Cell and Structural Biology, going on to become Dean of Life Sciences in 1994. In 1995, he founded the Manchester Biosciences Incubator, organising the funding and the building for a business innovation unit for the science emerging from the University.

During his own research, he became aware that wounds inflicted while in an embryonic state healed without scarring. With his wife, Dr Sharon O'Kane, he formed a biotech company called Renovo to try to develop drugs to prevent scarring in humans. He raised £30m from venture capitalists and eventually a further £100m from the Stock Exchange (London). There was some success with a lead drug being licensed to Shire Pharmaceuticals along the way.

However, a critical phase three trial failed, ultimately leading to the demise of Renovo of which he had been Chief Executive and his wife had been the Chief Scientific Officer. The company was left with a bank balance and no debt, so it transformed into Intuitive Capital, which lent money to developing businesses in the UK. Mark was a major shareholder but played no executive role in the company. At that point, in December 2011, an opportunity arose for his current role and as he was free to do so, he gained the appointment. He was appointed Director General of SFI in January 2012 and became Chief Scientific Adviser in October of that year as well.

Up the rankings

"There was work to be done and I felt I could help," he says of the job. He says that science is a global game and that his aim was simple, to add the factor of the impact of research to the necessity for excellence in assessing proposals for funding. He points out that SFI has done a very good job. Before SFI was founded 14 years ago, Ireland ranked 44th in the world for its scientific research; now it is 14th. He says that was achieved by careful investment and a focus on excellence. "What we do now is equivalent to what the great research institutions do. All funding is competitive and proposals are reviewed by international panels only. Excellence is required, but may not be sufficient in itself; the proposal must also demonstrate the impacts the research will have."

Professor Ferguson says that when he arrived there was no formal legal structure for private companies to fund research. "We now have €190m in private funding, matched by €355m in funding from SFI." That's great for the taxpayer, he says, but it doesn't end there. Typically, those receiving some of those funds will be told to gain more funding, usually from the Horizon 2020 EU programme.

He is enormously impressed by the presence in Ireland of so many of the world's major companies. "Nine of the top 10 pharmaceutical companies

SFI Research Centres

- 12 cutting-edge research centres of scale, excellence and impact
- 200 industry partners
- €190m funding from industry
- €355m SFI funding

"We're trying to build centres of scale. The Insight Centre for Data Analytics is a good example. It has 300 people working on big data and related themes and is the biggest centre of its kind in Europe. As with all of the centres we support, a minimum of 30% of funding must come from the private sector."

Dental development

As a student, Mark's greatest satisfaction arose when he made a very thin stainless steel upper denture for a patient. He had to get special permission to form it by explosion. The patient, a politician who had to do a lot of public speaking, loved it and Mark found it hugely satisfying. He wasn't such a fan of bending wires to removable orthodontics though – he felt it was unscientific because you couldn't measure the pressure.

The three things that he feels have made most impact in dentistry in his time are: tooth-coloured fillings; fluoridation of water (he's a big fan); and, fixed appliance orthodontics, especially for adults.



Cultural differences

Pushed specifically on things that we might not be good at, he observed that it is more difficult to take hard decisions in a small country. People can find it hard to accept a 'no'.

Elsewhere, a failure to gain funding usually results in a 'why not' – a process to find out what wasn't good enough in the proposal with a view to getting it right the next time. Here, he has observed that no can mean it's no until I talk to your boss. And when the answer remains no, as it always does, there is still sometimes a reluctance to accept that a proposal wasn't strong enough to gain the funds sought. It can be more "How dare they refuse me?" than "Why not?"

operate in Ireland; nine of the top 10 software companies are here; 13 of the top 15 medical technology companies; and, nine of the top 10 ICT companies are here too. They employ so many people and their impact is huge. Of all the medicines that are used in the world, 50% have some component made in Ireland. And there's a brilliant indigenous sector as well with companies like Kerry Group and Glanbia. Kerry recently opened a research centre employing 800 people in Naas. Did you know that all of the botox in medical use in the world comes from Ireland? It's from the Allergan plant in Westport in Mayo. Over years of good policy and shrewd decisions, Ireland has attracted and developed these companies. Science needs to relate to those companies."

The boy from Ballykelly

Mark Ferguson is the only child of a former primary school headmaster and his wife (also a teacher in that school) in Ballykelly, Co. Derry. He grew up with a natural curiosity and always wanted to be a dentist. That led him to a life in academia, research with alligators and crocodiles, a company that succeeded then failed, then succeeded again; and ultimately to be the Chief Scientific Adviser to the Government of Ireland.

He has lived in Ballykelly, Belfast, the United States, Manchester and Dublin. He says he has always enjoyed his work and wherever he lived. He and his wife, Dr Sharon O'Kane, have three daughters: one is a chemist working at Harvard; another works in marketing in London; and the third is at school in Dublin.

For relaxation, he enjoys reading, classical music and gardening (and especially making stone walls at home, when he can).

Prioritising research

How can a small country like Ireland do that? How can they serve those companies? "Small countries can't be scaled down versions of big countries – we can't do everything well. We have to prioritise in a way that is relevant to our society." He makes the point that one of the best ways to prioritise is to assess the various impacts that science and research can have – economic, societal and reputational. And that is his big message as Director General of SFI – he has tried to bring the world's most targeted focus on the impact of research. "So when we get applications for funding for research, we get the best international minds to review the proposals. We ask them which proposals we should not fund, and then we ask them to rank the proposals that we should fund." That has caused academics to take a close look at impacts so that when SFI asks if the researchers are trying to bring all the players in Ireland together in order to have a greater impact, it expects a positive answer. Out of such collaboration, 12 SFI-funded research centres have been born. This allows the best expertise from all seven universities and the relevant industry companies to work together in one structure.

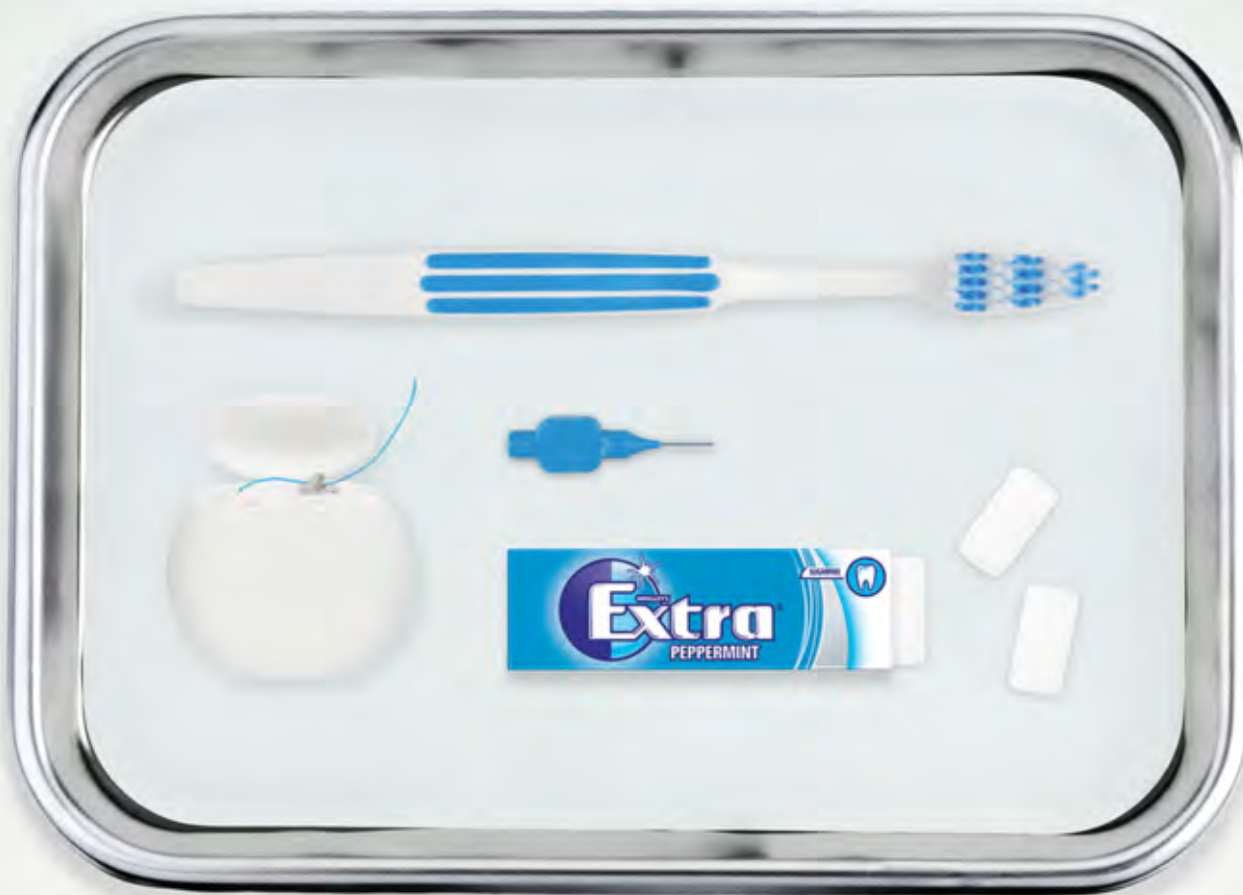Professor Ferguson is dismissive of the view that 'pure' research is necessary to prime applied research. "In my view, there is no such thing as pure or applied research: there is only good or bad research. If you look for a gene connected to the development of oral cancer, that's pure research until the moment you find it: then it's applied research."

Great time to be a scientist



Professor Ferguson thinks that this is a wonderful time to be a scientist. "The pace of change is huge; the rate of scientific discovery is fantastic; and the time from discovery to application is shortening. It's an incredibly interesting time to be alive."

Wrigley's Extra.

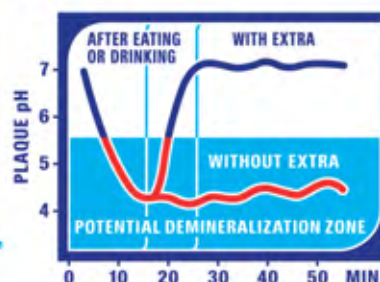
Another way to improve your patients' oral health



Significant changes in lifestyle mean that traditional eating habits have altered, and people are now eating on the go more than ever before. The more we snack, the more our teeth come under attack.

- 
 Independent clinical research proves that chewing sugarfree gum for 20 minutes after eating or drinking helps neutralise the plaque acid attacks that can cause tooth decayⁱ and contributes to removing food remainsⁱⁱ
- 
 Increased flow of saliva also promotes the remineralisation of tooth enamel,ⁱⁱⁱ thus reducing one risk factor for developing tooth decay^{iv,v}

Chewing sugarfree gum after eating and drinking helps neutralise plaque acids, assisting in keeping teeth clean and healthy.^{i,ii,iv,v}



Help your patients improve their oral health through one extra simple and enjoyable step – recommend Wrigley's Extra®.

To learn more about the science behind the benefits of sugarfree gum visit www.wrigleyoralhealthcare.ie



ⁱAlbrighton E., Lewis G., McMillan K., Zhai S. Benefits of Chewing Gum. Oral Health and Hygiene, Hoboken, India, Volume 43, Number 2, March/April 2010. ⁱⁱLeach SA, et al. Remineralisation of artificial caries-like lesions in human enamel in vivo by drinking sugarfree gum. J Dent Res 1989;68:1384-6. ⁱⁱⁱCreever SL, et al. The effect of chewing gum on oral pH and saliva flow on dental caries remineralisation. J Dent Res 1982;71:1489-900. ^{iv}Flisberg JG, et al. The effect of chewing sugarfree gum after meals on dental caries incidence. J Am Dent Assoc 1988;125:1679. ^vStadel J, et al. Effect of alcohol-free xylitol chewing gum on dental caries. J Dent Res 2001;80:1705-9. ^{vi}Chew sugarfree gum is beneficial for dental health as it helps neutralise plaque acids.



True evolution

Take advantage
of current offers!*

Now also
as a Flow!

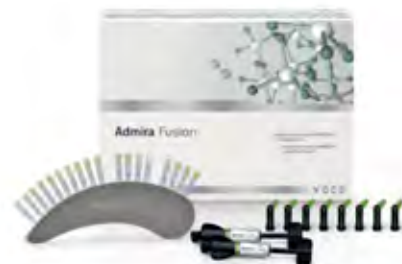

THE FIRST CERAMIC FOR DIRECT FILLINGS

- The worldwide first purely ceramic-based restorative material
- Lowest polymerisation shrinkage (1.25 % by volume) and particularly low level of shrinkage stress**
- Inert, so highly biocompatible and extremely resistant to discolouration
- Meeting highest demands in anterior and posterior regions
- Excellent handling, simple high-lustre polishing procedure coupled with high surface hardness guarantee first-class long-term results
- Compatible with all conventional bonding agents

*Find all current offers on www.voco.com or contact your local VOCO dental consultant. **in comparison to all conventional restorative composites
For more information please contact: Tel. 085 725 6078 · info@voco.com

Admira Fusion



VOCO
THE DENTALISTS

There's no such thing as a quick fix

There are a number of issues involved when responding to a request for a quick orthodontic fix for an older patient.

Adult patients who are prepared to commit themselves to orthodontics will generally not do so lightly. They are mostly compliant and co-operative, and want to be heavily involved in their treatment, often scrutinising every tooth movement. This could be a cue to reassess the level of the patient's expectations.

During the course of treatment, the clinician may come under pressure from the patient to adapt the original treatment plan. Unless the clinician has sufficient experience, there is a temptation to undertake tooth movements that are clinically contra-indicated, in an attempt to appease the patient.

Unmet expectations

Undergoing orthodontic treatment as an adult can be costly and time-consuming. Anyone making these sacrifices may have unrealistic expectations, not only of the outcome but also of the impact that straighter teeth will have on other aspects of their life; the stakes can be high. If you are not sure, now is the time to check that the patient's understanding of the proposed treatment is realistic, and make a note of the conversation in your records.

Clear aligner techniques

The concept of using removable tooth-positioning devices for minor localised tooth movements is not new. Arguably, developments in data technology have facilitated novel techniques for the movement of teeth. These systems can be particularly attractive to a clinician who has little experience in orthodontics, because the treatment plan and a series of aligners are formulated for them by the system provider.

Additional risks are introduced when the clinician is reliant on the computer software and the remote technician who designs and constructs the aligners – effectively taking over the diagnosis and treatment plan without ever seeing the patient. If that service originates outside your own country the risks associated with teledentistry should be considered.

Dentists with little experience in orthodontics are particularly vulnerable, as they may not have the expertise to recognise a treatment plan that is not in the patient's best interests, or that will require modification. Although the providers of such planning services inform practitioners that they can reject the treatment plan if it is unsuitable, the dentist may not have the knowledge or

confidence to question the computer-generated treatment plan. In such circumstances it would be wise to discuss your concerns with a more experienced colleague. Before providing any treatment, always ask yourself: "Am I confident I have the expertise to carry this out?"

Compliance

Aligner systems rely on patients wearing their aligners for a prescribed number of hours each day. Patients frequently fail to achieve this target, and so discrepancies can develop between the predicted and actual tooth movements that each aligner is expected to produce. An experienced clinician will notice the discrepancy and amend the treatment plan; a less experienced clinician may not.

Having to backtrack through the aligner sequence can be embarrassing for the clinician and frustrating for the patient. Sometimes a fixed appliance is required towards the end of the treatment to obtain the final outcome. If the clinician has not predicted this and discussed it with the patient, there can be disappointment when the patient learns they will have to wear a fixed appliance after all.

All in the name

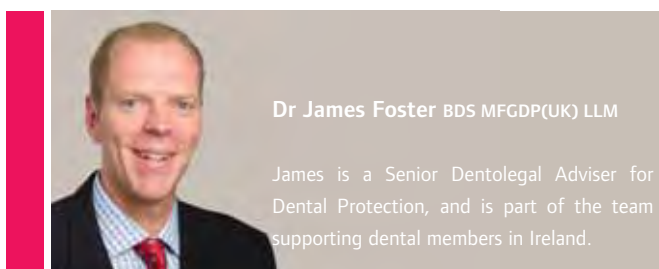
Using a system with a finite time span in the brand name, for example 'six month smiles', can influence patient expectations about treatment time. If consent forms supplied by providers of such systems state that treatment will take between four and nine months, it is easy to see how patients could make assumptions and feel upset if treatment takes longer.

Providers of various orthodontic systems often encourage practitioners to use the consent forms and information leaflets provided. But these forms, while often being helpful as general information leaflets, do not serve as evidence of the consent process. In order to demonstrate validity at a later date, it is essential that the consent process is appropriately documented in the patient's records, with evidence of the relevant information provided to the patient, including treatment options, the risks and benefits, and any limitations associated with the treatment options. The record should also detail the discussions regarding the patient's expectations, and whether or not these are likely to be met by the agreed treatment plan, a copy of the treatment plan, and compliance advice provided to the patient, including appliance wear and attendance at appropriate appointments.

Short-term orthodontic appliances have the capacity to apply forces to both the roots and the crowns of the teeth. In some patients there is a possible risk of root resorption. The clinician needs to understand how to assess the risk, which should be discussed separately and recorded in the clinical notes.

Relapse

As with any type of orthodontic treatment, retention is often required. This



needs to be identified, discussed with the patient and factored into the treatment plan from the outset. A less experienced clinician may not recognise the risk of relapse in the original treatment plan, and may fail to obtain patient consent for extended retention. When such information is presented to the patient at the end of treatment, unsurprisingly it can sometimes result in a complaint.

So how can I reduce my risk?

Over the last eight years, Dental Protection has seen an increase in claims and complaints arising from orthodontics. Our advice to aid patient satisfaction and avoid complaints is:

- ▶ carry out a thorough diagnosis;
- ▶ discuss all the treatment options;
- ▶ ascertain and manage the patient’s expectations in relation to the treatment, its outcome and retention; and,
- ▶ review the treatment as it proceeds and, where necessary, revise the treatment plan and/or seek advice from a more experienced colleague.

Embarking on orthodontic treatment without developing a proper depth of knowledge and understanding of orthodontics could invite problems. There are ever-present dangers when something is a lot easier to ‘sell’ than to do.

Top tips

Ask yourself:

- ▶ Have I considered all the treatment options?
- ▶ Am I confident to provide this treatment?
- ▶ Do I have access to a mentor or back-up if required?
- ▶ If I need to alter the treatment plan mid treatment, how will I discuss this with the patient? Do I need to prepare them for this from the outset?

Ask the patient:

- ▶ What does the patient want from the treatment? A slight improvement, perfectly straight teeth, or a particular tooth movement, e.g., de-rotation?
- ▶ Why do they want it now? Is it for a wedding, or other significant event?
- ▶ What are they prepared to accept by way of treatment, e.g., removable appliance, fixed appliance?
- ▶ How often can they attend? A patient who works away may be less able to attend regularly.
- ▶ Are there limitations to the outcome and, if so, does the patient understand this and accept the limitations?

The advertisement features a woman in a white dental uniform holding a blue folder. The folder text reads: "with DAY ONE INCOME PROTECTION". The IDA logo is in the top right corner. To the right, the headline asks: "Without an Income, could you manage all of your costs?". Below this are icons for Car, Mortgage, Pension, Nurse, and Surgery. The Omega Financial Management logo and name are at the bottom, along with contact information: "Request A Quote / Find Out More: 1850 260 261 • info@omegafinancial.ie" and the website "www.omegafinancial.ie".



Southern
Cross Dental

CELEBRATING DIGITAL 10% OFF* your first digital case

WE'RE DIGITAL READY

At Southern Cross Dental we can receive and process scans from 3Shape TRIOS®, Sirona CEREC®, Planmecca Planscan™ and Cadent iTero™ intraoral scanners.


Offering superior workflow solutions with minimised chair time and greater accuracy, digital scanners guarantee increased patient satisfaction, ease of use and improved turnaround times.

Connect with us today, visit us at scdlab.co.uk/digital or call us today on 048 8772 7100 (ROI) or 028 8772 7100 (NI)

*For a limited time only. Offer applies to price at the time of purchase on orders invoiced from 1 April 2016 to 31st May 2016 inclusive and cannot be used in conjunction with any other offer. Excludes implant bundles. Semi or high precious alloy extra.

Zirkonzahn's M1 Compact Line Milling Unit

The M1 Compact Line Milling Unit from Zirkonzahn is available in several models. It is, Zirkonzahn states, designed to match the needs and budget of dental laboratories of any size looking to take advantage of computer-aided manufacture. According to the company, the M1 Wet Heavy Metal Milling Unit is provided with intelligent 5+1 axes simultaneous milling and orbit technology to deliver the ultimate in versatility. This means that milling is possible in any conceivable plane – even undercuts and diverging abutments can be processed in a simple and fast way. The top of the range M1 Wet Heavy Metal Milling Unit offers complete versatility with both wet and dry processing functions for all soft materials and glass ceramics, as well as hard materials, including titanium and chrome-cobalt.



The M1 Compact Line Milling Unit combines in an optimal way with the Zirkonzahn S600 ARTI Scanner and the user-friendly software to provide a complete solution for your CAD/CAM needs. Visit Zirkonzahn on stand 10 at the IDA Annual Conference to see the unit.

Sirona Discovery Day at Schein

On Thursday April 14, Henry Schein and Sirona will host the Sirona Discovery Day at Henry Schein's Dublin showroom. Equipment specialists will be on hand to demonstrate dental chairs, digital 2D OPGs/Cephs, Sirona 3D CBCTs, Sirona CAD/CAM solutions and Sirona NEW CEREC Firespeed (furnace), which can help dentists to work more efficiently and to deliver quality patient care. Furthermore, Irish dentists will present their experiences with Sirona

technology and will be available to discuss any clinical questions. According to the company, restorations completed with the CEREC set high standards for results and the recent addition of CEREC orthodontic software encompasses traditional and clear aligners. The company says that Sirona 3D technology allows accurate implant planning and the seamless integration between imagery, production of drill guides, and implant restorations with CEREC Guide 2 ensuring a truly remarkable result for the patient.

Significant savings on NSK products

NSK has announced substantial savings on its range of oral hygiene solutions. Staff will be on hand to answer questions about these and anything else related to the company at their stand at the IDA Annual Scientific Conference in Galway in April.

The savings can be availed of when NSK's Varios 970 ultrasonic unit, Prophy-Mate neo and Perio-Mate are purchased together. NSK says that the Prophy-Mate neo is a proven and easy-to-use air-driven tooth polishing system. According to the company, the NSK Varios 970 benefits from the high-powered NSK iPiezo engine and provides a more effective and comfortable treatment. They state that the Perio-mate is ideal for cleaning delicate periodontal pockets and around implants.



Anne Marie Taylor, hygienist at Saracen Street Dental in Glasgow, Scotland, said: "Although we only charge a relatively small additional amount per treatment, the units have quickly paid for themselves, as patients love the results".

Now available in application capsules

Voco has announced that two of its products in the world of restorative dentistry, Ionolux and IonoSelect, are both now available in Voco application capsules. The company says Ionolux, a light-curing glass ionomer restorative material, combines the advantages of glass ionomer materials with those of composites. IonoSelect is a universal glass ionomer material and, according to Voco, is the first product in the world suitable for use in the four main GIC indications: luting; restorations; core build-up; and, cavity lining.

Voco says that the application of Ionolux is quick and can be modelled without the hassle of it sticking to the instrument. It contends that the product adapts nicely to cavity walls and

makes conditioning of dental hard tissue unnecessary. Ionoselect features high compressive strength, good adhesion, high levels of biocompatibility and fluoride release. Possible uses include luting of metal-based crowns, bridges, inlays and outlays.





Visit DMI at the IDA Annual Conference



Stand 4

21st - 23rd April 2016

Welcome to the future of dentistry

DMI is delighted to support the IDA Annual Conference 2016. Visit us at stand 4 to explore all your surgery possibilities and discover the latest innovations in dentistry.

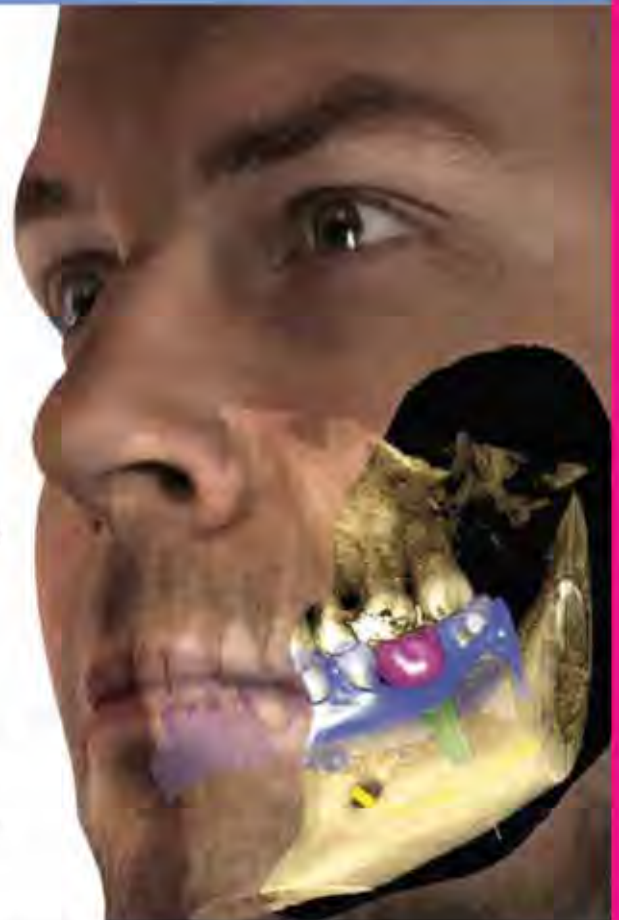Planmecca produces world-class imaging devices for all purposes- 3D imaging, 2D imaging, Intraoral imaging and Cephalometry. Demo the Planmecca PlanScan and see how quickly you can create and design 3D digital impression models.

View cutting edge digital systems such as the Carestream 81003D. Blending advanced technologies in an ultra-compact design, the system provides everything you need to capture high-quality, crystal-clear 3D images in seconds.

COINCIDENTAL has produced a new state-of-the-art Practice Management System, based on the latest Microsoft technologies, that offers benefits no other existing system can provide.

Experience first-hand the latest products in our range of consumables and small equipment.

Join us at stand 4 and talk to our experts about turning your vision into reality.



PLANMECCA
Connecting you to a world of
Digital Dentistry

COINCIDENTAL
OUR SYSTEM YOUR PRACTICE
WORKING TOGETHER

Carestream
DENTAL
Authorized Dealer

Lo call: 1890 400 405

Web: www.dmi.ie

Email: info@dmi.ie



INNOVATION IN DENTISTRY

GUMS

INTENSIVE CARE:

KINGINGIVAL 0.12% Chlorhexidine DG + Alpantha
PERIOKIN 0.20% Chlorhexidine DG



Anti plaque effect and gum protection

Anti plaque effect for localised and intensive care of gums

MAINTENANCE:

KIN: B5

Daily control of biofilm and gum protection



SENSITIVE TEETH



Protects sensitive teeth

ORAL MUCOSA

KINCARE

Care of delicate mucosa



TRANEXAMIC ACID GEL

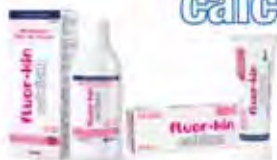KINexogel



Bioadhesive astringent gel with tranexamic acid. Suitable for use in dental procedures.

CHILDREN'S ORAL CARE

fluor·kin
calcium



Fluoride + Calcium for enamel protection

ORTHODONTIC

ORTHO KIN

Strawberry Mint

Specific oral hygiene for wearers of orthodontic braces



ENZYMATIC DENTAL BLEACHING

NEW!

Exclusive and patented bleaching formulation with carbamide peroxide activated by lactoperoxidase



WHITE KIN

WHITENING

KIN
WHITENING
TOOTHPASTE
PROGRESSIVE



To whiten and protect enamel

The future is now

This year the IDA Annual Conference is at the Radisson Hotel in Galway. The theme is 'Dentistry into the Future' and IDA President Elect Dr PJ Byrne is delighted to be welcoming delegates to an exciting event.

The conference takes place from April 21-23 and will feature a range of talks on new dentistry procedures such as future trends in restorative dentistry and 3D imaging in orthodontics. Along with the lectures and workshops, there will of course be a big social programme, including the golf competition, annual dinner and trade show opening party.

As always, there will be an array of topics covered by many speakers in different workshops and lectures across the three days. The AGM of the IDA and IDU will take place on Thursday, April 21 at 6.00pm in the Inis Mór Suite.

Sessions have been approved for CPD points. Instead of holding separate sessions for nurses and hygienists, dental team members are welcome to attend all sessions on Friday and Saturday.

Pre-conference programme

The pre-conference programme on Thursday will feature lectures and courses

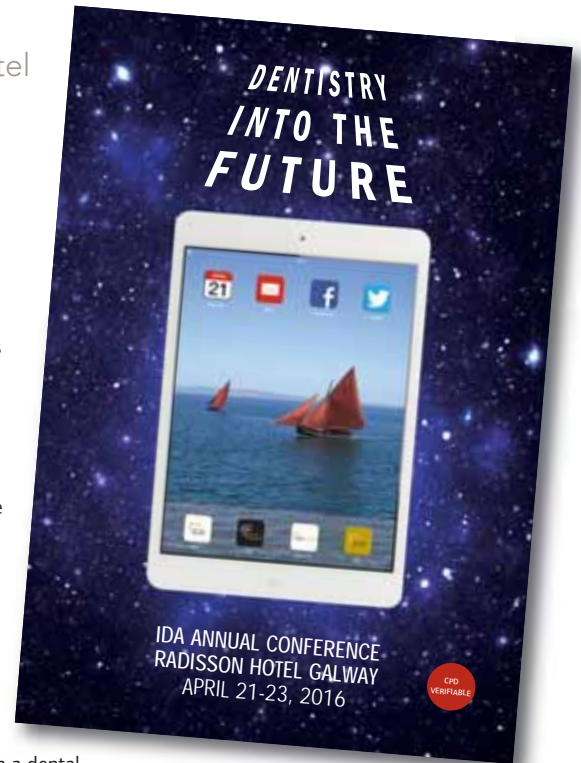on topics such as anterior composites and endodontic canal preparation. Dr Charles Goodacre will discuss in a full-day lecture whether a tooth should be saved through root canal treatment or extracted and replaced with a dental implant or denture.

Delegates can attend a compliance workshop in infection prevention and control on either the morning or the afternoon hosted by Dr Nick Armstrong, Dr Jane Renehan and Ms Siobhan Carrigan.

A second workshop will focus on medical emergencies and is also available in either the morning or afternoon. This workshop will show dental professionals how to manage patients suffering from a medical/cardiac emergency while awaiting paramedics.

Lecture programme

The conference will have two halls with lectures running from morning to evening in both. On Friday in Hall 1, Dr Patrick Palacci will give his insights into precision in implant placement. Professor Tara Renton will look at third molar surgery in practice and Dr Pat Cleary will give his five keys to clinical success.



Don't miss...

Friday April 22

Mary Aiken

This year's *Journal of the Irish Dental Association* lecture will be given by Mary Aiken of the Cyber Psychology Research Centre. Cyberpsychology is the study of the impact of emerging technologies on human behaviour. Mary will discuss topics such as cyberchondria, cyber crime and the virtual treatment of PTSD.

JOURNAL OF THE IDA LECTURE



PJ Byrne
President Elect



Gerry Cleary
Chairman of the Organising Committee



Jane Renehan
Organising Committee



Mark Kelly
Organising Committee



Elaine Hughes
Organising Committee

LIST OF EXHIBITORS

GOLD

- 1 Colgate
- 2 GSK
- 4 DMI
- 9 Henry Schein

SILVER

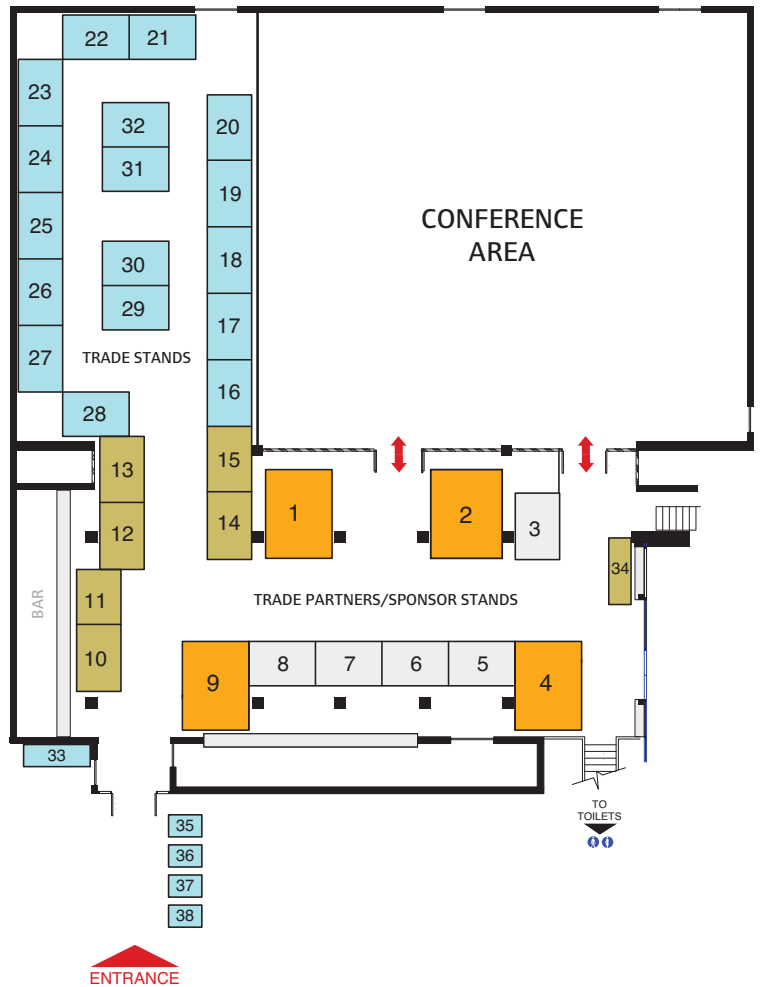
- 3 NSK
- 5 Johnson & Johnson
- 6 Southern Cross Dental
- 7 Dentsply
- 8 Wrigley

BRONZE

- 10 Zirkozahn
- 11 Pamex Limited
- 12 Swordfish Medical
- 13 Swordfish Medical
- 14 Septodont
- 15 Southern Implants
- 34 Coltene

TRADE

- 16 Ascherl Ceramics
- 17 IDT Ireland
- 18 QSIP Ltd
- 19 Dentech
- 20 Karma Sales & Services Ltd
- 21 3M Ireland Ltd
- 22 Promed
- 23 TePe
- 24 Optident Ltd
- 25 Heraeus Kulzer Ltd
- 26 MedAccount Services
- 27 Handpiece Harry
- 28 McDowell + Service
- 29 Omega
- 30 Biomet 3i UK Ltd
- 31 VOCO GmbH
- 32 Nobel Biocare
- 33 EPA-RPII
- 35 Initial Medical Services
- 36 Irish Dental Health Foundation
- 37 Irish Dental Hygienists Association
- 38 Irish Dental Nurses Association



TePe

It's all about the space

Angled or straight brush head, long or short handle, original or extra-soft filaments, TePe's range of interdental brushes have an option for everyone. No wonder 94% of dental hygienists recommend them*.

New! TePe EasyPick™ – Use every day, anytime, anywhere, endorsing the interdental cleaning habit! Each pack contains a FREE travel case encouraging frequent on-the-go use. 36 EasyPicks per pack.

*Source: A survey of dental hygienists in the UK, Eaton et al. (2012).

To receive your free TePe EasyPick sample, visit:
tepe.com/uk/samplerrequest and use code IDA04a.

www.tepe.co.uk

FREE!
 TePe
 EasyPick
 Whilst stocks last.

TePe EasyPick interdental brushes and travel case.

@TePeUK #TePeFamily

Don't miss...

Pre-conference programme Thursday April 21
Dr Paddy Crotty

Dr Crotty will deliver a full-day course on anterior composites. The course will teach a predictable technique for restoring anterior teeth. At the end of the course delegates will understand the background science behind the technique, the concept of colour and colour generation, and how to generate a sound, durable restoration.



Dr Brendan Fanning

Get expert insights into oral radiography from Dr Fanning. He will look at the correct use of film/sensor holder with paralleling technique for inter-oral dental radiography, dose reduction with rectangular collimation and use of thyroid protection.

Professor Brian O'Connell will look at some ground-breaking techniques in restorative dentistry.

In Hall 2, Dr Marielle Blake will kick off Friday's proceedings with a look at interceptive orthodontics. Later on, Dr James Mah gives us an overview of 3D imaging in orthodontics, and the *Journal of the Irish Dental Association* lecture, on the psychology of cyberspace, will be given by Mary Aiken.

The events continue on Saturday in both halls. Dr Michael O'Sullivan explains how to manage a hypodontia patient for optimum results. Composites: how do we get the best results in practice? This is the question Dr Paddy Crotty will answer in his lecture. Dr Conor Barry closes the day's proceedings in Hall 1 with

a look at oral cancer diagnosis and treatment. In Hall 2, emerging issues in local anaesthesia and pain control in dentistry will be explored by Dr Dermot Canavan. Drs James Mah and Bob Genco deliver lectures in new concepts in the management of bruxism and the periodical systemic link, respectively. Dr Garry Fleming will advise delegates on dental materials for the present and future.

Clinical workshop

As always, delegates can attend sessions for continuing professional development (CPD) points. Forms will be available for the morning or afternoon sessions at the accreditation desk in the conference registration area.



M1 WET HEAVY METAL MILLING UNIT

- 5+1 axes simultaneous milling and orbit technology
- For processing zirconia, resin, wax, wood, sinter metal, cobalt-chrome, titanium, glass ceramics, composite as well as Raw-Abutments® and Bridge-Rods depending on equipment
- Tool Changer function with 8-fold Tool Magazine
- CAD/CAM Milling Bur 6 mm for more stability during milling
- Individual extension options, e.g. Raw-Abutment® Holder, Bridge-Rod Holder
- Wet processing

Zirkonzahn Worldwide – South Tyrol (Italy) – T +39 0474 066 680 – www.zirkonzahn.com – info@zirkonzahn.com

Don't miss...

Saturday April 23

Dr Kevin Lewis

Kevin will give an insight into what is coming down the legal road for dentists. He will advise dentists on what to do and what not to do.



For each session you attend, a separate form must be signed and your accreditation number included.

Social programme

The conference offers the opportunity to develop your skills and knowledge, but also to relax.

Our social events kick off on Thursday with the President's golf competition at Galway Bay Golf Club. Tee time will be at 2.30pm and green fees cost €35. Anyone busy with pre-conference events on Thursday has the option to play on the Wednesday instead. Accompanying persons and trade delegates are also welcome to play but only registered delegates are eligible for the President's Prize.

On Thursday night the trade show opening party will take place directly after

the AGM in the trade show area. Association President Dr PJ Byrne will be on hand to open the Dentistry into the Future trade show at around 8.00pm. All delegates and trade show sponsors are welcome to attend and enjoy the music and drinks provided.

The black tie annual dinner takes place on Friday evening. The evening will begin with a drinks reception at 7.30pm with dinner and dancing afterwards. Tickets cost €85 and are available from IDA House. The music will be provided by Brass and Co. and all delegates, trade members and friends are welcome.

On Saturday morning the 5k dental team fun run will take place around the historic streets of Galway. Entire dental teams are encouraged to get involved with prizes for the best team. All proceeds go to St Vincent de Paul.

Finally, the Annual Past Presidents' Lunch will be held in Raw at 1.00pm.

Dr Joe Moloney Award

The Dr Joe Moloney Award is given to an outstanding Irish presenter/lecturer at the Conference and is chosen by the delegates. Sponsored by the Dental Health Foundation, the award will be given on the final day of the Conference when all delegates will have the chance to nominate their favourite lecturer of the Conference for the award.

Dr Tony Costello Memorial Medal

Dental students from across the country get the chance to show what they have to offer general dental practice. Each of our three dental schools can enter a team of two people to give a table demonstration or poster presentation.


Five Reasons to Visit our Stand

1. Here since 1977 and into the future.
2. Continually working with all health professionals.
3. Promoting Excellence with the Moloney Award.
4. Empowering people to improve their oral health.
5. Free oral health promotion resources.

See you at Stand 36, the IDA Conference, Galway, April 2016!


It's not all work...!

Thursday April 21: The President's Golf Competition will take place from 2.00pm. There is also the option to play on Wednesday, April 20, in the afternoon instead.



The 'Dentistry into the Future' Trade Show will be officially opened by the newly inaugurated IDA President, Dr PJ Byrne, at 8.00pm.

All delegates and Trade Show sponsors are invited to attend. Come along and enjoy the party!



Friday April 22: The Annual Dinner will take place on Friday evening. A drinks reception will take place at 7.30pm followed by dinner and dancing. Dress code is black tie.



Tickets (€85) available from IDA House. Dancing to Brass and Co. All dental team members, trade members and friends are welcome.

Saturday April 23: Our annual 5K fun run will take place at 8.30am and you can walk or run around lovely Galway. Prizes for the best team on the day. All proceeds go to St. Vincent de Paul.



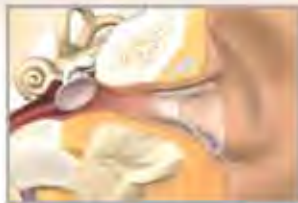The Annual Past Presidents' Lunch will take place in Raw at 1.00pm.



Removable Hollow Ear Canal Inserts

A Breakthrough in TMJD Treatment

Now you can offer your patients the latest technology in Temporomandibular Joint Disorder treatment. The Cerezen™ device is a safe and effective aid in reducing TMJD pain and associated symptoms such as grinding of teeth and headaches.

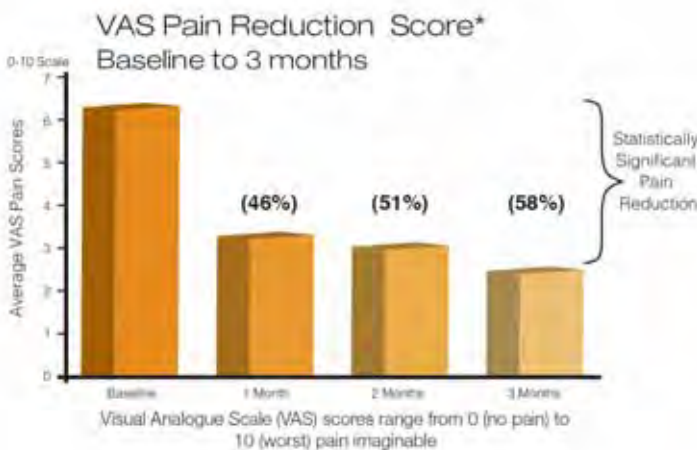


A New Approach

The Cerezen™ devices are custom ear canal inserts that support the temporomandibular joint and reduce pain. They also provide a "cognitive awareness" to the patient that discourages grinding, clenching and other para-functional behaviour.

Patient Outcomes

In a clinical trial, subjects experienced statistically significant pain reduction while using Cerezen™ devices. Visual Analogue Scale scores showed a 58 percent pain reduction after three months of use. At the end of the trial, 100 percent of subjects reported good to excellent results.*



Benefits of the Cerezen™ Device

	Cerezen™ Device
• Designed to be worn comfortably 24/7	✓
• No interference with eating or talking	✓
• Barely visible	✓
• No night-time discomfort	✓
• No negative effect on the bite	✓

info@Cerezen.eu • www.cerezen.eu
Freephone: +800 19431965

Articulators, face bows and interocclusal records

Articulation has been defined as the static and dynamic relationship between the occlusal surfaces of the teeth during function. Management of articulation in the dentition is one of the most important aspects of modern dentistry. Failure to manage articulation can result in problems for the patient and for the restorations placed by the dentist.




FIGURE 1: Class I articulator.



FIGURE 2: Class II articulator.



FIGURE 3: Class III articulator. This is a Whipmix® 2240 model.



FIGURE 4: Class IV articulator. This is a TMJ highly adjustable articulator.

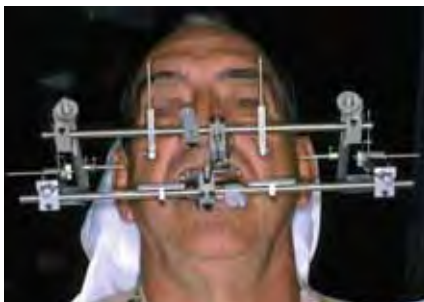

FIGURE 5: A pantograph used to trace the true hinge axis of the mandibular condyles.

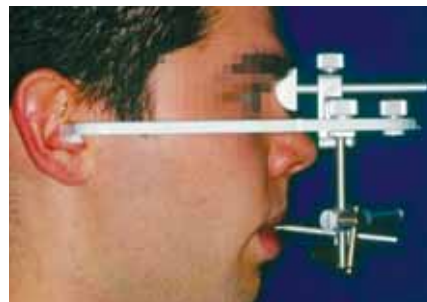


FIGURE 6: A Whipmix® facebow. The external acoustic meatus is used to support the bow posteriorly and position the arm over the hinge axis. The third point anteriorly is located 23mm below the nasion.

The articulator is an often-neglected tool at the dentist's disposal. An articulator is any mechanical instrument that represents the temporomandibular joints and jaws, to which maxillary and mandibular casts can be attached to simulate some or all mandibular movements. With over a century of development, the modern dental articulator is a very useful tool in the dentist's armamentarium. The articulator has three basic functions:

1. To study the static and dynamic relationships of the patient's teeth, allowing the dentist to diagnose problems not readily apparent clinically.

2. To plan treatment that involves the interrelationship of the teeth.
3. To fabricate a prosthesis, extra-orally in the dental laboratory, in harmony with the patient's dentition.

There are four basic articulator types available to the dentist. These have been classified as:¹

1. Class I: A simple holding instrument capable of accepting a single static registration – vertical motion is possible (Figure 1).
2. Class II: An instrument that permits horizontal and vertical motion but does not orient the motion to the temporomandibular joints (Figure 2).
3. Class III: An instrument that simulates condylar pathways by using averages or mechanical equivalents for all or part of the motion, often referred to as 'semi' adjustable articulators. These instruments allow for orientation of the casts relative to the joints (Figure 3).
4. Class IV: An instrument that will accept three-dimensional dynamic registrations, often referred to as 'fully' or 'highly' adjustable articulators. These instruments allow orientation of the casts to the temporomandibular joints and simulate mandibular movements (Figure 4).

Dr Paul Quinlan

Specialist practice limited to prosthodontics and periodontics, Quinlan Dental Care, Dublin. www.quinlandentalcare.com



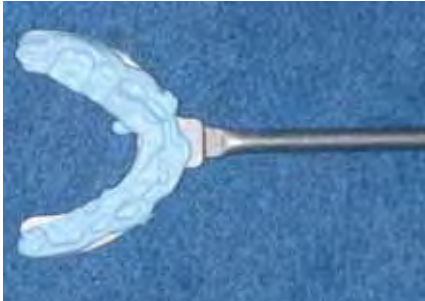

FIGURE 7: Facebow fork indexed to the patient's maxillary teeth with a polyvinylsiloxane jaw record material.

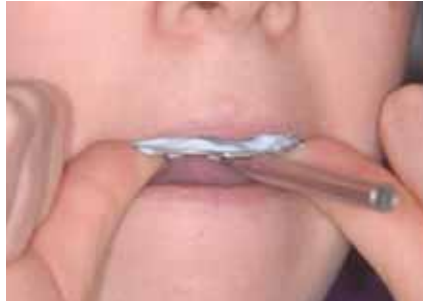

FIGURE 8: The facebow fork is held against the maxillary teeth by the patient.

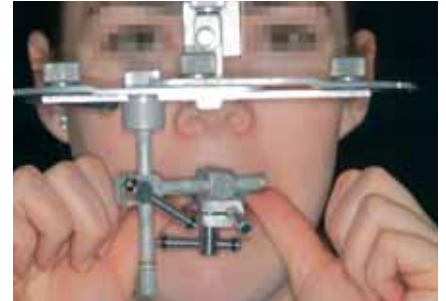


FIGURE 9: The earpieces of the facebow are placed into the patient's external auditory meatuses, the nasion relator is positioned and the upright member is connected to the fork. The toggles are then tightened and the facebow removed from the patient.



FIGURE 10: The facebow attached to the articulator to allow mounting of the maxillary cast.



FIGURE 11: Whipmix® mounting jig used to secure the facebow upright in the correct orientation when mounting the maxillary cast. Utilisation of the mounting jig eliminates the need to send the complete facebow to the laboratory; it is only necessary to forward the smaller upright.



FIGURE 12: Mounting jig attached to the lower member of the articulator. Utilisation of a mounting jig requires only the upright member portion of the facebow to be sent to the laboratory, allowing for easier shipping.

In dental practice, the articulator classes that are most often used are the Class II for simple restorations such as a single crown, and the Class III, which can be used for more complex reconstructions, up to and including complete dentures or full mouth fixed reconstruction. Examples of common situations where a Class III articulator can be of value are: 1) where canine guidance is lacking; and, 2) fixed restorations that involve the most distal teeth in an arch. A Class III instrument is not as programmable as the Class IV; however, if its limitations are acknowledged and it is accepted that a degree of adjustment may be required when the prosthesis is placed, then its use is acceptable for all but the most complex cases.

Use of the facebow

For Class III, semi-adjustable articulators, positioning of the maxillary cast on the upper member is the first step in programming the articulator. This is done with the aid of a facebow. A facebow is a caliper-like instrument that records the spatial relationship of the maxilla to anatomic reference points and transfers this relationship to the articulator. The anatomic reference points are usually the mandibular condyles' transverse horizontal axis and one other selected anterior point, usually referred to as the third point of reference.² In many facebows this point is infra-orbital. There are two types of facebow: 1) a kinematic facebow, which uses the previously located transverse horizontal axis or the 'true axis' (Figure 5); and, 2) an average axis facebow, which uses an estimated position, based on prior, researched measurements, of the true horizontal hinge axis of the mandible (Figure 6). Average axis facebows are normally used with Class III articulators.

While not as accurate as kinematic facebows, research has indicated that average axis facebows are sufficiently accurate for most clinical purposes. For example, Schalhorn³ noted that a facebow with an arbitrary axis was within 5mm of the true kinematic value in 98% of the population. A 5mm error in the location of the hinge axis results in a 0.2mm error at the second molar. An error of this magnitude can be easily adjusted intra-orally.⁴

Modern facebows allow for quick and easy recording and transfer to the laboratory. Figures 7, 8 and 9 illustrate the sequence for making a record with a Whipmix® facebow. This facebow is designed to be used by a single operator, but utilisation of the dental assistant to position the earpieces can make the process extremely efficient. Utilisation of a mounting jig ensures that only a portion of the facebow, not the cumbersome earpieces, need to be sent to the laboratory (Figures 10, 11 and 12).

Attaching the mandibular cast

Once the maxillary cast is placed, the second step is to attach the mandibular cast to the lower member of the articulator. The mandibular cast may be mounted in centric relation (CR) or maximum intercuspation (MIP) depending on the specifics of the case. A jaw relation record must be made. Mounting in CR requires that the condyles articulate with the thinnest avascular portion of their respective disks, with the complex in the anterior-superior position against the shapes of the articular eminencies. This position is independent of tooth contact.¹ A variety of techniques is available to position the condyles correctly. Once the condyles have been placed correctly, the interocclusal record is made

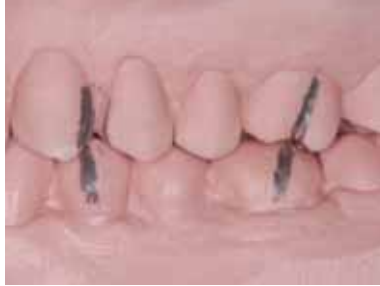
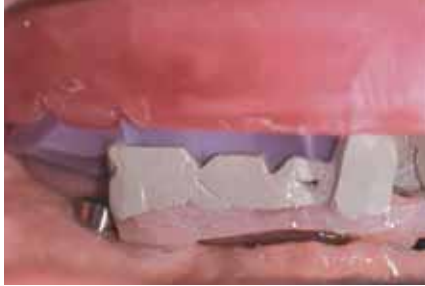
FIGURE 13 (FAR LEFT): A centric relation record made with record bases and polyvinylsiloxane interocclusal record material.

FIGURE 14 (LEFT): Witness lines made to aid positioning of the mandibular cast when mounting in the articulator. At least three contact areas between maxillary and mandibular teeth are noted intraorally. These areas are deemed to be in contact when the mandibular cast is being secured with mounting plaster to the lower member of the articulator.

at the correct vertical dimension (Figure 13). For most cases where the new restoration is being fabricated to conform to the current occlusion scheme, a maximum intercuspation record is made. One of the most accurate methods to do this is to locate occluding reference points intraorally, mark these on the models and use these reference points when mounting (Figure 14).

To complete the mounting, the third and last step is to use check bites to program the adjustable components of the articulator. This is done using protrusive and lateral records made intraorally.

Conclusion

Accurately mounted casts in an articulator provide the dentist and dental

technician with an excellent tool to analyse, plan and fabricate dental restorations. Articulator utilisation can help to avoid problems and allow for minimal adjustment, saving chairtime and preserving thickness of restorative material when a new prosthesis is placed.

References

1. The glossary of prosthodontic terms. *J Prosthet Dent* 2005; 94: 10-92.
2. **Wiens, J.** *Fundamentals of Occlusion*. American College of Prosthodontists, 2015: 73.
3. **Schalhorn, R.G.** A study of the arbitrary center and kinematic center of rotation for facebow mounting. *J Prosthet Dent* 1957; 7: 162-169.
4. **Weinberg, L.A.** Evaluation of the face-bow mounting. *J Prosthet Dent* 1961; 11: 32-42.



Irish Dental Credit Union Ltd

A Credit Union run by dentists for dentists since 1978
A member of the Irish League of Credit Unions

Loans of
up to €39,000

Interest rate on
new loans 5.9%

For more information go to

www.irishdentalcreditunion.ie

Terms and conditions apply

Colgate®

**The only† sensitivity toothpaste
that delivers...**



Instant relief*

Long-lasting relief

**Recommended cavity
protection** (1450ppm F)**

Bring it on!

Now you can treat dentine hypersensitivity without compromise. Colgate® Sensitive Pro-Relief™ toothpaste works instantly for on the spot relief;* delivers long-lasting results for ongoing sensitivity relief and contains 1450ppm fluoride for maintaining healthy teeth.

Three benefits all at once

Clinically proven protection,
Irish Dental Association approved



Colgate®

YOUR PARTNER IN ORAL HEALTH

www.colgateprofessional.ie

† Available in the UK and Ireland. * When toothpaste is applied to each affected tooth for one minute.

Three case reports demonstrating treatment of relatively complex orthodontic cases using a completely customised lingual appliance

Abstract

It is a commonly held misconception among Irish dentists that only minor malocclusions can be treated with lingual appliances. This article demonstrates the use of contemporary completely customised lingual orthodontic appliances to treat a diverse range of malocclusions, to a satisfactory level, and thereby may disabuse clinicians of the belief that only minor malocclusions can be treated with lingual appliances.

Journal of the Irish Dental Association 2015; 62 (2): 106-113

Introduction

Research conducted by Perry in 2014 in the Republic of Ireland revealed that 51% of general dental practitioners believe that only “simple cases” can be treated with lingual appliances, whereas 49% believe that all types of malocclusions – “crooked teeth” – can be treated (Figure 1).¹ This deficit in knowledge of some practitioners may result in inappropriate advice being given to patients.

Research has shown that a significant number of adult patients find “commonly used” labial appliances to be unattractive and unacceptable,² and that between 33% and 62% of adults would reject treatment with a visible appliance.^{3,4} It also reveals that adults are prepared to pay more money for appliances that they deem to be more aesthetic.⁶ If practitioners are not aware of the scope of lingual orthodontic treatment, this may result in some patients being incorrectly advised that lingual orthodontic treatment is not possible in their case. Of the patients

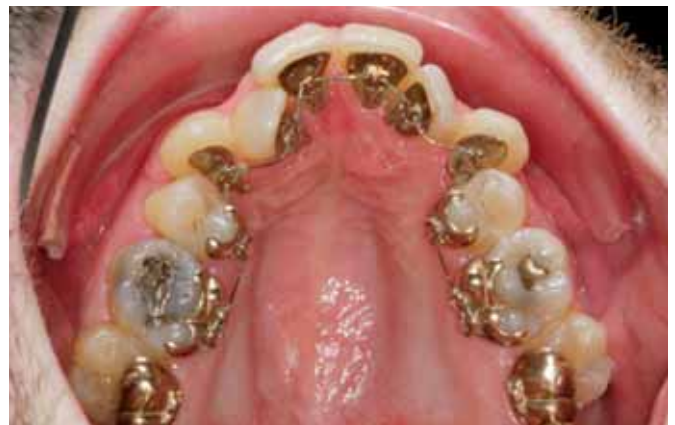

FIGURE 2: Completely customised lingual appliance (CCLA).

described here, patients one and two were simply not prepared to wear labial orthodontic appliances. They might have remained untreated if they had received inappropriate advice from their general dental practitioner.

The objective of this article is to demonstrate the use of contemporary, completely customised lingual orthodontic appliances to treat a diverse range

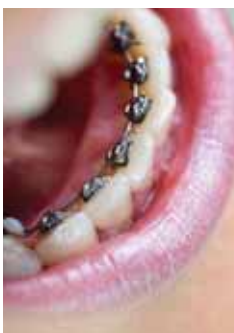49%

Yes, all types of malocclusions

51%

No, only simple cases

FIGURE 1: Replies to the question “Do you think that all types of malocclusions – “crooked teeth” – can be treated successfully with lingual orthodontic therapy? (Figure courtesy Dr R. Perry).¹



Dr John Buckley BDS FDS MOrth MScD MDO FFD

Correspondence

Dr John Buckley, Riverhouse Orthodontic Practice,
Riverhouse, New Quay, Clonmel, Co. Tipperary
T: 052-612 9299 E: admin@clonmelorthodontist.ie



of malocclusions, to a satisfactory level, and to thereby hopefully disabuse clinicians of the belief that only minor malocclusions can be treated with lingual appliances. Points of interest specific to lingual appliances, which arose in the management of these patients, will be referred to where appropriate.

The design and fabrication of one type of completely customised lingual appliance (CCLA) – Incognito™ (TOP service 3m Unitek, Bad Essen, Germany; **Figure 2**) – has been described previously in this journal and elsewhere.^{6,7}

The increase in the number of adults seeking orthodontic treatment can at least partly be explained both by the advent of more aesthetic orthodontic appliances, and by the intensive marketing campaigns, which the manufacturers of various removable clear aligner systems have run.

However, clear aligner systems, because of their inherent biomechanical limitations, can only accomplish certain types of tooth movement. The available research would suggest that the mean accuracy of tooth movement with Invisalign™ (San Jose, CA, USA) is only 41%.⁸ However, it is possible that, as some aligners are now used in combination with bonded composite attachments on the labial surface of the teeth, and also because of possible improvements in the aligner material itself, certain types of tooth movement maybe be achieved more effectively.⁹ Despite these possible improvements,

their role remains limited to the correction of specific malocclusions. By contrast, research would suggest that the CCLA is an effective appliance, which can achieve the objectives of the orthodontic treatment plan when used by an experienced orthodontist.^{10,11,12} The current design and correct clinical management of the CCLA will minimise the difficulties that patients experience in adapting to the appliance.¹³

Orthodontics continues to evolve towards an evidence-based specialty. It is well recognised that there is a hierarchy of evidence. Case reports are low down in the hierarchy of evidence, and have significant limitations. They only demonstrate the results achieved by a given clinician under a certain set of circumstances. Case reports do not tell the clinician what to expect for any given patient, they rather tell the clinician what is possible under some partially known set of conditions. Case reports should not be permitted to govern treatment for ostensibly similar clinical situations.¹⁴ However, given these important limitations, case reports are frequently used in peer-reviewed journals as a very valuable means of introducing and illustrating the possibilities and limitations of a new treatment methodology.^{9,15-20}

The following three non-consecutive cases were chosen to illustrate some of the diversity of malocclusions that it is possible to treat with the CCLA.

CASE 1

Case 1 is that of a 30-year-old male with a class I type malocclusion with severe mal-alignment of the upper and lower arches. The upper first premolars were extracted when he was a child. Treatment involved the extraction of both lower first premolars, and he was treated with upper and lower CCLA incognito appliances (**Figures 3-8**). Retention consisted of upper and lower bonded retainers, and removable Essix™-type retainers (Dentsply, Raintree Essix, Sarasota FL, USA), which are worn at night. Treatment time was 25 months.

Points of clinical interest – case 1

(a) When setting up the case, a Bolton discrepancy²¹ was noted by the

technician and it was necessary for minor interproximal reduction to be carried out to achieve an optimal occlusion. This information was communicated to the clinician by the laboratory (**Figure 9**) and was subsequently performed on the patient.

- (b) Due to the lingual inclination of the lower right second premolar ($\bar{5}/$), it was necessary to section the lower indirect bonding tray in the lower right first premolar ($\bar{4}/$) region. The two sections of the lower tray were then bonded separately. This was to avoid the conflicting paths of insertion, which would arise if one attempted to bond the lower arch with an un-sectioned tray.
- (c) It was not possible to bond the lower right central incisor ($\bar{1}/$) from the beginning as there was insufficient space available on its lingual surface.

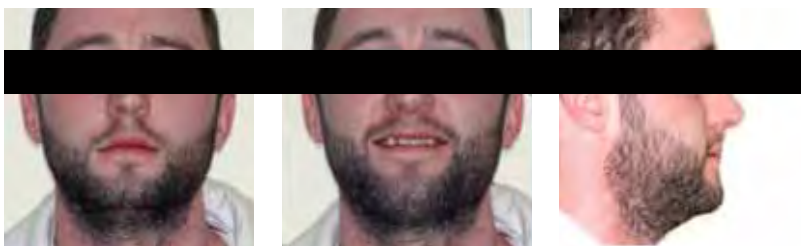

FIGURE 3: Case 1 – pre-treatment facial views.

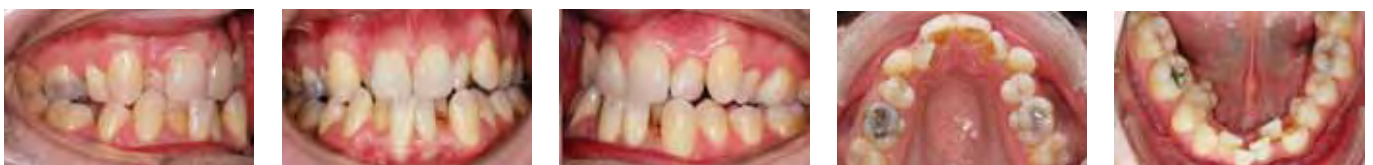

FIGURE 4: Case 1, pre treatment.

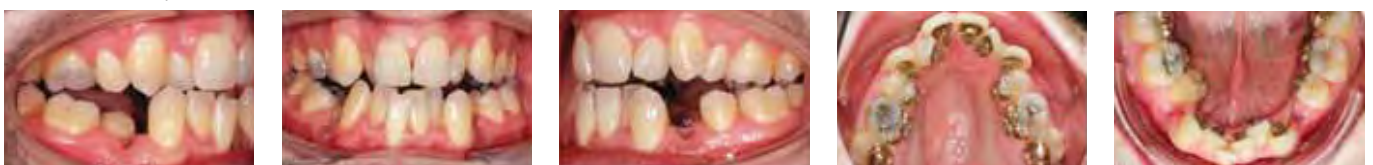

FIGURE 5: Case 1 in treatment with upper and lower CCLA in situ.



FIGURE 6: Case 1 – facial views post treatment.

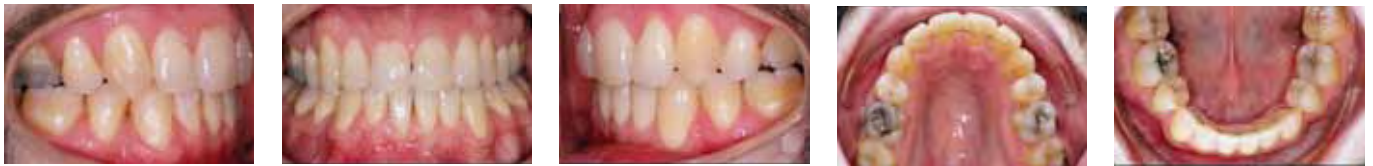

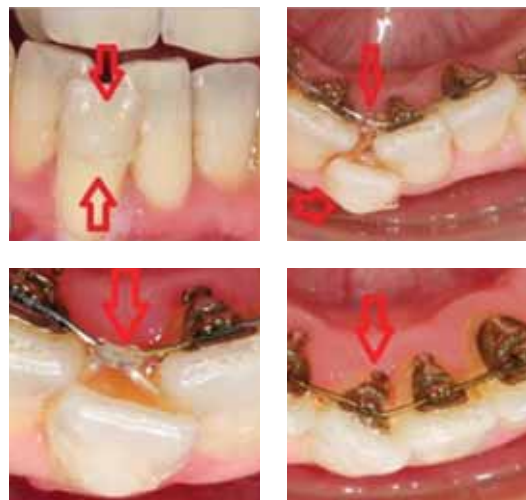
FIGURE 7: Case 1 post treatment.



FIGURE 8: Case 1 – target set-up.

	0.5	0.5	0.5	0.5
	0.5	0.5	0.5	0.5
	0.5	0.5	0.5	0.5
	0.5	0.5	0.5	0.5

FIGURE 9: Details of interproximal reduction as performed by the laboratory.



FIGURES 10 and 11: Composite button and power chain lasso to align the lower right central incisor ($\bar{1}/\bar{1}$).

FIGURES 12 and 13: As the elastomeric aligned the lower right central incisor ($\bar{1}/\bar{1}$), it created sufficient space to bond the lingual bracket.

TABLE 1: Summary of cephalometric changes in Case 1

Measurement	Normal (SD)	Pre-treatment	Post-treatment
SNA	81 ± 3°	75°	75°
SNB	78 ± 3°	74°	74°
ANB	3 ± 2°	1°	1°
SN/Mx PA	8 ± 3°	9°	9°
M.M. PA	27 ± 3°	27°	27°
LFH %	55 ± 2%	57%	56°
$\bar{1}/\bar{1}$ -Max P	108 ± 6°	110°	111°
$\bar{1}/\bar{1}$ -Mdb P	93 ± 6°	86°	85°
$\bar{1}/\bar{1}$ A Pog	0-2mm ± 2mm	+1mm	0mm
$\bar{1}/\bar{1}$	133° ± 10°	153°	142°

This tooth was attached to the arch wire using elastomeric power chain as a lasso, which was placed at the initial bond up (Figures 10 and 11). A small composite build-up was placed on the labial surface to prevent the elastic chain slipping off the tooth. As the other bonded teeth in the lower labial segment aligned, this provided sufficient space on the lingual surface of the lower right central incisor ($\bar{1}/\bar{1}$) for the bracket to be bonded directly (Figures 12 and 13).

(d) At the completion of space closure, it was felt that the lower right canine and the lower left central and lateral incisors and canine ($\bar{3}/\bar{1}\bar{2}\bar{3}$) all exhibited excessive distal crown tip (Figure 14) when compared to the target set-up ($\bar{3}/\bar{1}\bar{2}\bar{3}$) (Figure 8).

An additional finishing TMA wire was ordered, with 15° of mesial tip in the canines, and 12° of mesial tip in the left central and lateral incisors, with the bends inserted by the “wire bending robot” (Figures 15 and 16). This improved the tip of $\bar{3}/\bar{1}\bar{2}\bar{3}$ (Figure 7).

(e) To correct the lateral open bites, the patient was asked to wear “inverted V” elastics 3/2oz by 1/8” attached to buccal composite buttons at night for three months (Figure 17).

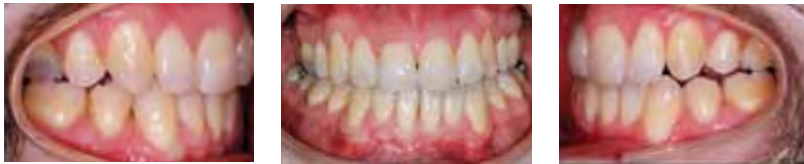

FIGURE 14: The lower right canine and the lower left central and lateral incisors and canine exhibit excessive distal crown tip at the completion of space closure.

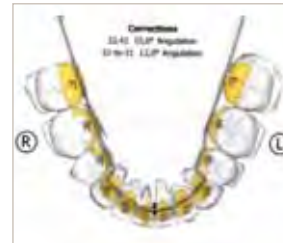

FIGURE 15: Finishing arch wire on template.



FIGURE 16: Finishing arch wire with second order bends highlighted.

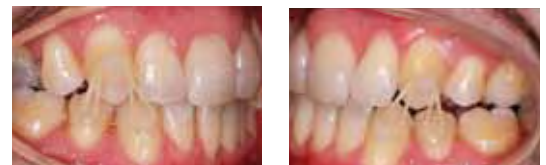

FIGURE 17: Inverted V elastics.

CASE 2

Case 2 is that of a 28-year-old male with a class III type malocclusion on a skeletal III base relationship with maxillary retrusion (Figures 18 and 19). He was treated with a combination of orthodontics and orthognathic surgery. The orthodontic treatment was accomplished with upper and lower CCLA Win™ appliances (DW lingual systems, Bad Essen, Germany). The surgery involved a Le Fort 1 maxillary advancement. Retention consisted of upper and lower bonded retainers, and removable Essix-type retainers, which are worn at night. Treatment time was 26 months.

As part of the initial informed consent process for patients who are to have orthognathic surgery with lingual orthodontic appliances, it is important that they are informed from the outset that they will have to wear labial composite buttons in the labial segments and buccal stainless steel buttons in the buccal

segments immediately before surgery and possibly for a week or more after surgery until it is possible for the attachments to be removed. This is necessary to facilitate intra-operative inter-maxillary fixation. It is important that the attachments are secure and tied together, as they can become loose during surgery.

TABLE 2: Summary of cephalometric changes

Measurement	Normal (SD)	Pre-treatment	Post-treatment
SNA	81 ± 3°	74°	80°
SNB	78 ± 3°	77°	75°
ANB	3 ± 2°	-3°	5°
SN/Mx PA	8 ± 3°	5°	5°
MM PA	27 ± 3°	36°	36°
LFH %	55 ± 2%	58%	59%
∠-Max P	108 ± 6°	110°	109°
∠-Mdb P	93 ± 6°	83°	91°
∠/A Pog	0-2mm ± 2mm	+2mm	0mm
∠∠	133° ± 10°	144°	136°

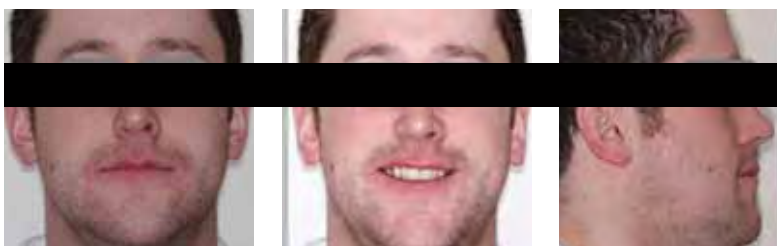

FIGURE 18: Case 2 – pre-treatment facial views.

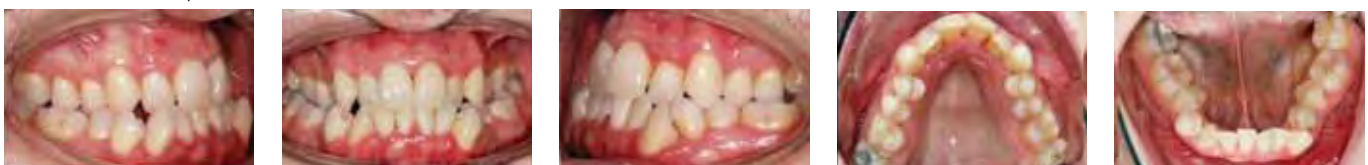

FIGURE 19: Case 2 pre treatment.

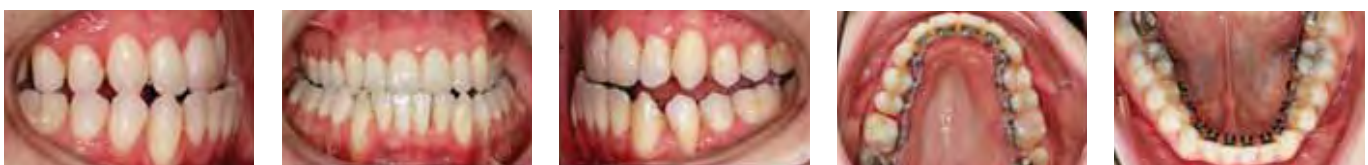

FIGURE 20: Case 2 in treatment with upper and lower CCLA before surgery.

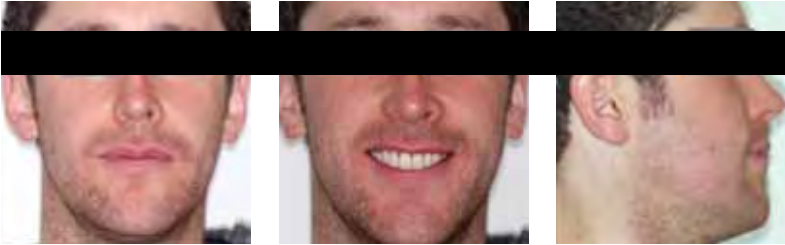


FIGURE 21: Case 2 – post-treatment facial views.

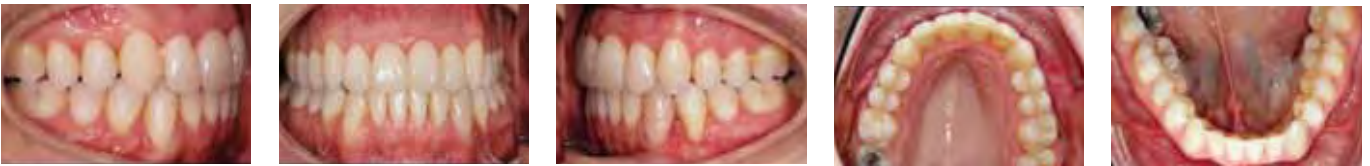

FIGURE 22: Case 2 post treatment.



FIGURE 23: Case 2 target set-up.



FIGURES 24 and 25: Expanded arch wire on template and set up model.

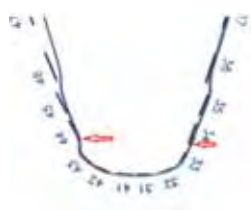

FIGURE 26: Red arrows indicate stops placed on the arch wire in the lower first premolar bracket positions as denoted on the wire template.

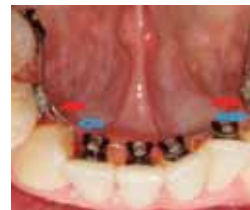

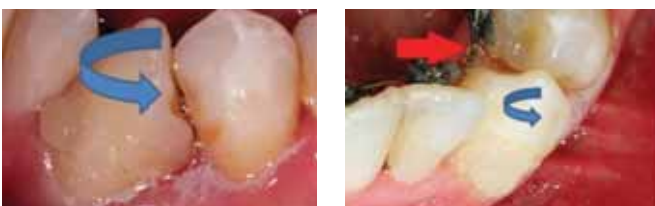
FIGURE 27: Compressed lower arch wire in place. Red arrows indicate stops on wire. Blue arrows indicate compressed wire loops.

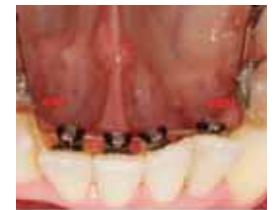

FIGURE 28: Lower arch wire has provided sufficient space to align both lower canines.

Points of clinical interest – case 2

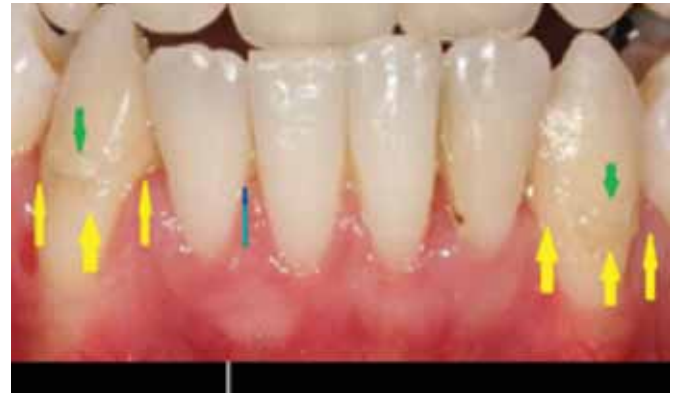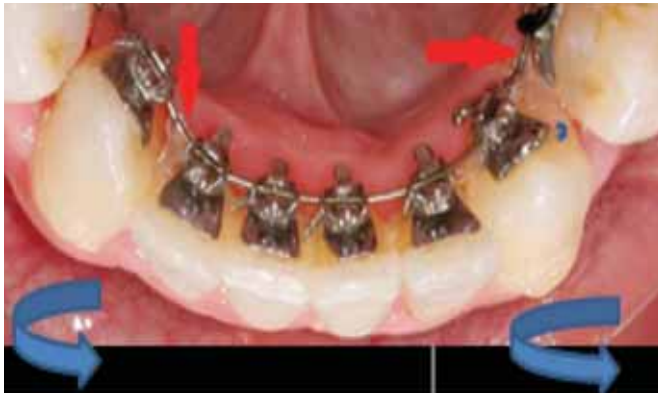- (a) The laboratory was asked to remove 0.25mm from the interproximal surfaces of the teeth in both arches from the mesial interproximal surface of the first permanent molar around to the mesial interproximal surface of the other first permanent molar, i.e., 5.5mm per arch. This was to avoid excessive proclination and expansion of the lower arch. This interproximal reduction was subsequently performed on the patient.
- (b) The technician was asked to respect the buccal limits of the maxillary bone when setting up the upper arch. If it had not proved possible to achieve a



FIGURES 29 and 30: Blue arrows denote direction of de-rotation. Red arrows denote where elastomeric is looped around arch wire.

Table 3: Pre-treatment cephalometric analysis (post-treatment cephalometric analysis is not available as patient did not wish to have further radiographs).

Measurement	Normal (SD)	Pre-treatment
SNA	81 ± 3°	85°
SNB	78 ± 3°	78°
ANB	3 ± 2°	7°
SN/Mx PA	8 ± 3°	5°
MM PA	27 ± 3°	25°
LFH %	55 ± 2%	56%
∟/-Max P	108 ± 6°	94°
∟/-Mdb P	93 ± 6°	90°
∟/A Pog	0-2mm ± 2mm	-5mm
∟/∟	133° ± 10°	155°



FIGURES 31 and 32: Blue arrows denote direction of de-rotation. Red arrows denote where elastomeric is looped around arch wire. Green arrows denote composite ledge. Yellow arrows denote elastomeric chain.

satisfactory transverse buccal occlusion, then surgical transverse expansion of the maxilla may have been required.

- (c) A .018" * .025" stainless steel arch wire (the largest dimension stainless steel arch wire available with the CCLA appliance) with added expansion was used to achieve the desired upper arch expansion expeditiously (Figures 24 and 25).
- (d) To create space in the lower arch, stops were placed on the arch wire in the lower first premolar positions as indicated on the template (Figures 26, 27 and 28). It was not possible to bond the lower left canine from the start as its lingual surface was not accessible. To facilitate its de-rotation, a composite button was bonded on the labial surface of the tooth; an elastomeric chain was then extended from the composite button to the arch wire on the distal aspect of the tooth (Figures 29 and 30). Once the tooth had de-rotated sufficiently, the lingual bracket was bonded (Figures 31 and 32).
- (e) Due to the reduced inter-bracket distance in lingual orthodontics, in the labial segments it is necessary to use brackets with a narrow width to maintain a sufficient inter-bracket span so that the arch wire has sufficient springiness and range of action. However, narrow brackets generate a lower de-rotating moment. Rotated canines in particular, because of their large root surface area, benefit from the use of elastomeric lassos to facilitate their de-rotation (Figures 31 and 32). The elastomeric chain is attached to the arch wire on the side of the tooth to which you wish the labial surface of the tooth to move. The power chain is stretched tightly around the labial surface of the tooth from the arch wire to the lingual bracket on the same tooth. A composite ledge is placed on the labial surface of the tooth to prevent the power chain from slipping up incisally. The elastomeric lassos achieved satisfactory de-rotation of the mandibular canines in this case.
- (f) Areas of labial gingival recession were noted in the lower arch at the completion of treatment. The patient was encouraged to adopt meticulous oral hygiene procedures with an atraumatic brushing technique. These lesions will be monitored and should further recession arise the patient will be referred to a periodontist.

Increasing the scope of the CCLA

It is obvious that the most that any fixed appliance (labial or lingual) in a single arch can achieve is to align and level the arch, close any spacing present, and adjust the arch form. Similarly, upper and lower fixed appliances can merely do

this in both arches. However, to achieve a satisfactory occlusion it is commonly necessary to adjust the position of the arches relative to each other, in the antero-posterior, vertical or transverse planes of space. There are numerous ways to do this, including intermaxillary elastics, flexible bite jumpers, the Herbst appliance, and orthognathic surgery as described above, or to use a removable type of functional appliance like a twin block prior to fitting fixed appliances when the patient's age allows. Essentially, all of these techniques can be employed with lingual appliances as readily as they can with labial appliances to establish an occlusion. Employing these techniques expands the role of lingual appliances to that of potentially treating every malocclusion that can be treated with a labial appliance. It is obviously important that the visual impact of these accessories and appliances is discussed with the patient as part of the informed consent process, and that they are shown photographs of them before treatment commences.

One means of adjusting the antero-posterior relationship of the arches is to employ intermaxillary elastics. The use of class II elastics in combination with a lingual appliance to correct a mild antero-posterior discrepancy has been described and illustrated previously in this journal.⁶

However, when the antero-posterior discrepancy is more severe (generally greater than a half unit II of postnormality), either a fixed flexible bite jumper²² or the rigid type Herbst²³ appliance can be used. The use of the Herbst appliance in combination with the CCLA for treating class II malocclusions has been described elsewhere,^{24,25} including its use specifically for class II division 2 type malocclusions.²⁶ The Herbst appliance consists of a bilateral telescopic mechanism connecting the maxillary and mandibular dental arches so as to maintain the mandible in a continuous protruded position. Each telescope consists of a tube, a plunger, two pivots and two screws. With the pivots, the tube is attached to the maxillary first molar and the plunger to the mandibular canines. The screws prevent the tube and the plunger from slipping off the pivots. The length of the tube determines the amount of anterior positioning of the mandible, whereas the length of the plunger ensures the connection to the tube during mouth opening.²⁴ The author confines its use to patients who are considered to be too old for removable functional appliances. The predominant effect of the Herbst appliance, when used at this stage, is that of dento-alveolar camouflage. When the Herbst appliance is used with labial orthodontic appliances, it is not always possible to wear both appliances simultaneously, whereas its simultaneous use with the CCLA confers an advantage for a treatment plan that can often be prolonged.



FIGURE 33: Case 3 – pre-treatment facial views.

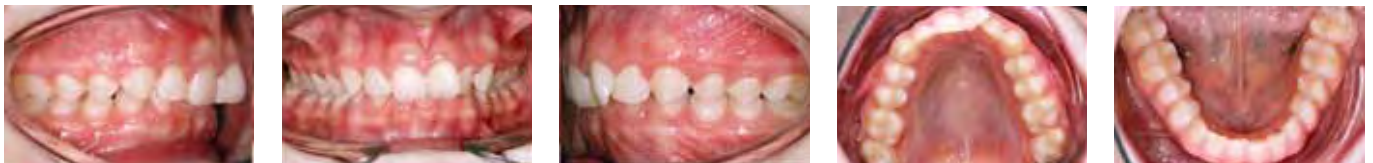

FIGURE 34: Case 3 pre treatment.

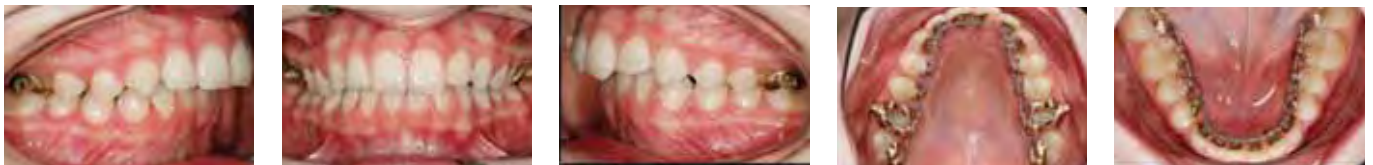
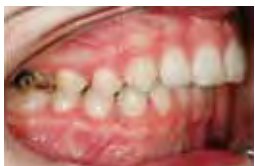
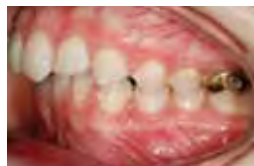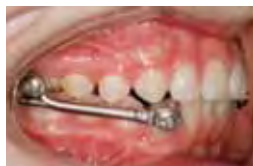FIGURE 35: Case 3 in treatment.



FIGURES 36 and 37: Case 3 (right buccal view) prior to and with Herbst advancement.



FIGURES 38 and 39: Case 3 (left buccal view) prior to and with Herbst advancement.

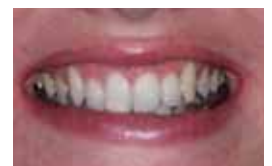
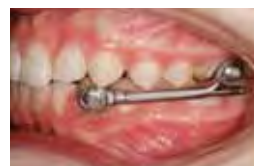
FIGURE 40: View of Herbst appliance in normal expression (in a different patient).

CASE 3

Case 3 describes the use of the Herbst appliance in combination with the CCLA appliance to correct a class II division 2 type malocclusion (Figures 33-43). The patient was a 16-year-old male with a skeletal II base relationship with mandibular retrusion. The patient was felt to be too old for treatment with a removable type of functional appliance. As part of the pre-treatment consent process, the appearance of the Herbst appliance was shown to the patient, and its use to posture the mandible forward was described and illustrated, as in Figures 36-39. It is important that it is appreciated, as illustrated in Figure 40 (of a different patient wearing a Herbst appliance in combination with a CCLA), the extent to which the Herbst appliance is visible in normal expression when the lips and cheeks are not retracted. The Herbst appliance is normally fitted four to six months after the CCLA. In this case the Herbst appliance was worn for nearly 14 months. The treatment duration was 24 months. Retention consisted of upper and lower bonded retainers and an upper Essix-type retainer.

Points of clinical interest – Case 3

The bracket on the upper left central incisor /1 was constructed as an off-centre bracket, as the distal surface of this tooth was not accessible from the

start (Figures 34 and 35). This meant that this tooth could be bonded as part of the initial bond up, and consequently saved clinical time. The off-centre bracket is designed to be passive on the finished arch wire when the tooth is aligned. Despite this, the off-centre bracket (because it is off centre) is still at a biomechanical disadvantage when it comes to developing a sufficient de-rotating moment. Elastomeric de-rotating lassos, as described in Case 2 (Figures 31 and 32), can be used with off-centre brackets to achieve sufficient de-rotation more expeditiously.

Conclusion

It is a commonly held misconception¹ that lingual orthodontics is only capable of treating “simple malocclusions”; it can, however, achieve a high standard of orthodontic result comparable to labial orthodontics when treating more complex malocclusions, when properly applied.^{10,11,12} By combining the CCLA with other treatment modalities, its scope is greatly increased.

The author has no financial interest in the appliances described.

The author wishes to thank Dr Larry Levens, St Louis, Missouri, USA, Dr Gema Olmos, Murcia, Spain, and Drs Miriam and Niall McCarthy, Ennis, Co. Clare, for reviewing this article prior to its resubmission.



FIGURE 41: Case 3 – post-treatment facial views.

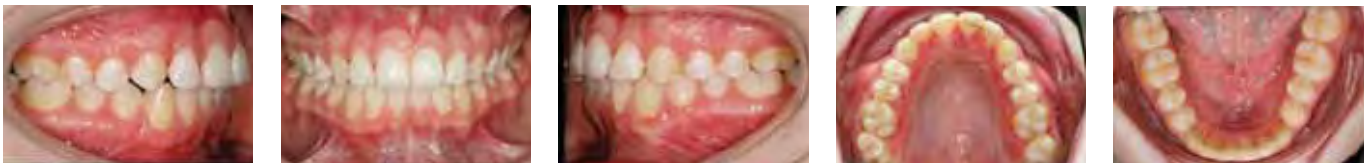

FIGURE 42: Case 3 post treatment.



FIGURE 43: Case 3 target set-up.

References

- Perry, R. An evaluation of the opinions of dentists in the Republic of Ireland to lingual orthodontics in 2014. Master's Thesis Lingual Orthodontics, Department of Orthodontics, Hannover Medical School, Germany.
- Ziuchkovski, J., Fields, H., Johnston W., Lindsey, W. Assessment of perceived orthodontic appliance attractiveness. *Am J Orthod Dentofacial Orthop* 2008; 133 (Suppl.): 568-78.
- Bergstrom, K., Halling, A., Wilde, B. Orthodontic care from the patients' perspective: perceptions of 27-year-olds. *Eur J Orthod* 1998; 20: 319-329.
- Meier, B., Wiemer, K., Miethke, R. Invisalign patient profiling. *J Orofac Orthop* 2003; 64: 352-358.
- Rosvall, M., Fields, H., Ziuchkovski, J., Rosenstiel, S., Johnston, W. Attractiveness, acceptability, and value of orthodontic appliances. *Am J Orthod Dentofacial Orthop* 2009; 135: 276, e1-e12.
- Buckley, J. Lingual orthodontics: an illustrated review with the incognito fully customised lingual appliance. *Journal of the Irish Dental Association* 2012; 58: 149-155.
- George, R., Hirani, S. Fully-customised lingual appliances: how lingual orthodontics became a viable treatment option. *Journal of Orthodontics* 2013; 40: S8-S13.
- Kravitz, N., Kusnoto, B., BeGole, E., Obrez, A., Agrane B. How well does Invisalign work? A prospective clinical study evaluating the efficacy of tooth movement with Invisalign. *Am J Orthod Dentofacial Orthop* 2009; 135: 27-35.
- Giancotti, A., Garino, F., Mampieri, G. Lower incisor extraction treatment with the Invisalign technique: three case reports. *Journal of Orthodontics* 2015; 42: 33-44.
- Grauer, D., Proffit, W. Accuracy in tooth positioning with a fully customised lingual orthodontic appliance. *Am J Orthod Dentofacial Orthop* 2011; 140: 433-443.
- Pauls, A. Therapeutic accuracy of individualised brackets in lingual orthodontics. *J Orofac Orthop* 2010; 71: 348-361.
- Thalheim, A., Schwestka-Polly, R. Klinische Umsetzbarkeit eines setups in der lingualen orthodontie. *Inf Orthod Kieferorthop* 2008; 40: 277-282.
- Fillion, D. Improving patient comfort with lingual brackets. *J Clin Orthod* 1997; 31: 689-694.
- Isacson, R. Evidence based orthodontics. *Angle Orthod* 2002; 72: iv.
- Spary, D., Little, R. The simple class II and class III corrector: three case reports. *Journal of Orthodontics* 2015; 42: 69-75.
- Berglund, L., Kurol, J., Kvint, S. Orthodontic pre-treatment prior to autotransplantation of palatally impacted maxillary canines: case reports on a new approach. *Eur J Orthod* 1996; 18: 449-456.
- Collins, S., Poulton, D. Orthodontic and orthognathic surgical correction of class III malocclusion. An American Board of Orthodontics case report. *Am J Orthod Dentofacial Orthop* 1986; 89: 216-222.
- Chandoke, T., Agarwal, S., Feldman, J., Shah, R., Upadhyay, M., Nanda, R. An efficient biomechanical approach for the management of an impacted maxillary central incisor. *Am J Orthod Dentofacial Orthop* 2014; 146: 249-254.
- Kim, S., Kim, J., Choi, T., Lee, K. Case report: combined use of miniscrews and continuous arch for intrusive root movement of incisors in Class II division 2 with gummy smile. *Angle Orthod* 2014; 84: 910-918.
- Lawson, R. Extraction treatment in lingual orthodontics. *Journal of Orthodontics* 2013; 40: S38-S48.
- Bolton, W. The clinical application of a tooth-size analysis. *Am J Orthod Dentofacial Orthop* 1962; 48: 504-529.
- O'Keeffe, C., O'Keeffe, M. Class II therapy with a combination of customised lingual appliances and the Forsus device. *J Clin Orthod* 2013; 47: 464-470.
- Pancherz, H. The Herbst appliance: its biologic effects and clinical use. *Am J Orthod Dentofacial Orthop* 1985; 87: 1-20.
- Wiechmann, D., Schwestka-Polly, R., Hohoff, A. Herbst appliance in lingual orthodontics. *Am J Orthod Dentofacial Orthop* 2008; 134: 439-446.
- Wiechmann, D., Schwestka-Polly, R., Pancherz, H., Hohoff, A. Control of mandibular incisors with the combined Herbst and completely customized lingual appliance – a pilot study. *Head Face Med* 2010; 11: 1-11.
- Vu, J., Pancherz, H., Schwestka-Polly, R., Wiechmann, D. Correction of Class II, Division 2 malocclusions using a completely customized lingual appliance and the Herbst device. *J Orofac Orthop* 2012; 73: 225-235.

The path of least resistance in oral surgery

Abstract

Statement of the problem: Antibiotic resistance is an imminent threat to worldwide public health. Dental professionals must demonstrate judicious use of antibiotics and educate their patients about the risks associated with their overuse.

Purpose of the paper: To encourage the dental profession to prescribe responsibly in order to optimise the use of antibiotics in oral surgery. Antibiotic stewardship programmes are recommended to help reduce the emergence of infections that are multidrug-resistant. Clinical practice audits are encouraged to help dentists ensure conservative prescribing patterns.

Conclusions: The dental profession has a duty of care to prescribe antibiotics in adherence with current best practice oral surgery guidelines. The dental profession must show leadership in slowing antibiotic resistance by pledging to safeguard their appropriate use.

Journal of the Irish Dental Association 2015; 62 (2): 114-120

Introduction

The World Health Organisation has identified antibiotic resistance as a major threat to worldwide public health.¹ Every year there are an estimated 25,000 deaths in Europe due to antibiotic resistance.² This is primarily caused by inappropriate prescribing habits, which lead to the over-use of antibiotics. The dental profession is globally responsible for between 7 and 11% of all antibiotic prescriptions.³ Indiscriminate prescribing practices among dentists, particularly in the field of oral surgery, need to be targeted. Inappropriate prescribing of antibiotics leads to selection and dominance of resistant microorganisms. The exchange of genetic material can also increase resistance, resulting in resistant genes spreading between populations of bacteria.⁴ As a consequence, antibiotics are becoming less effective and contribute to many infections, which are increasingly difficult to treat. The dental profession must demonstrate leadership in helping to reduce the impact of antibiotic resistance.

The human microbiome

The human microbiome consists of the microbes, along with their genes and genomes, that live in and on the human body. These resident microbes are important to our health as they play a significant role in maintaining our immune systems, contributing to digestion and acting as a first line of defence against pathogens. Researchers now believe that many diseases may be the result of disturbed microbiomes. The current understanding indicates that the human body is made up of 10 times more microbial cells than human cells. It is thought that there may be millions more microbial genes than human genes in this human and microbiome system, and it is the ways in which these microbial genes interact with the human host that describe their ultimate role in health.⁵ At the same time as we are beginning to appreciate the microbiome, scientists are growing concerned about things that we are doing that may disturb this delicate system. Antibiotic resistance develops when bacteria are exposed to



Dr Laura Fee BA BDS MJDF

Correspondence

Dr Laura Fee
Fee & Associates, Church Street, Carrickmacross, Co. Monaghan.
Email: lauramichellefee@gmail.com M: 086-338 9260

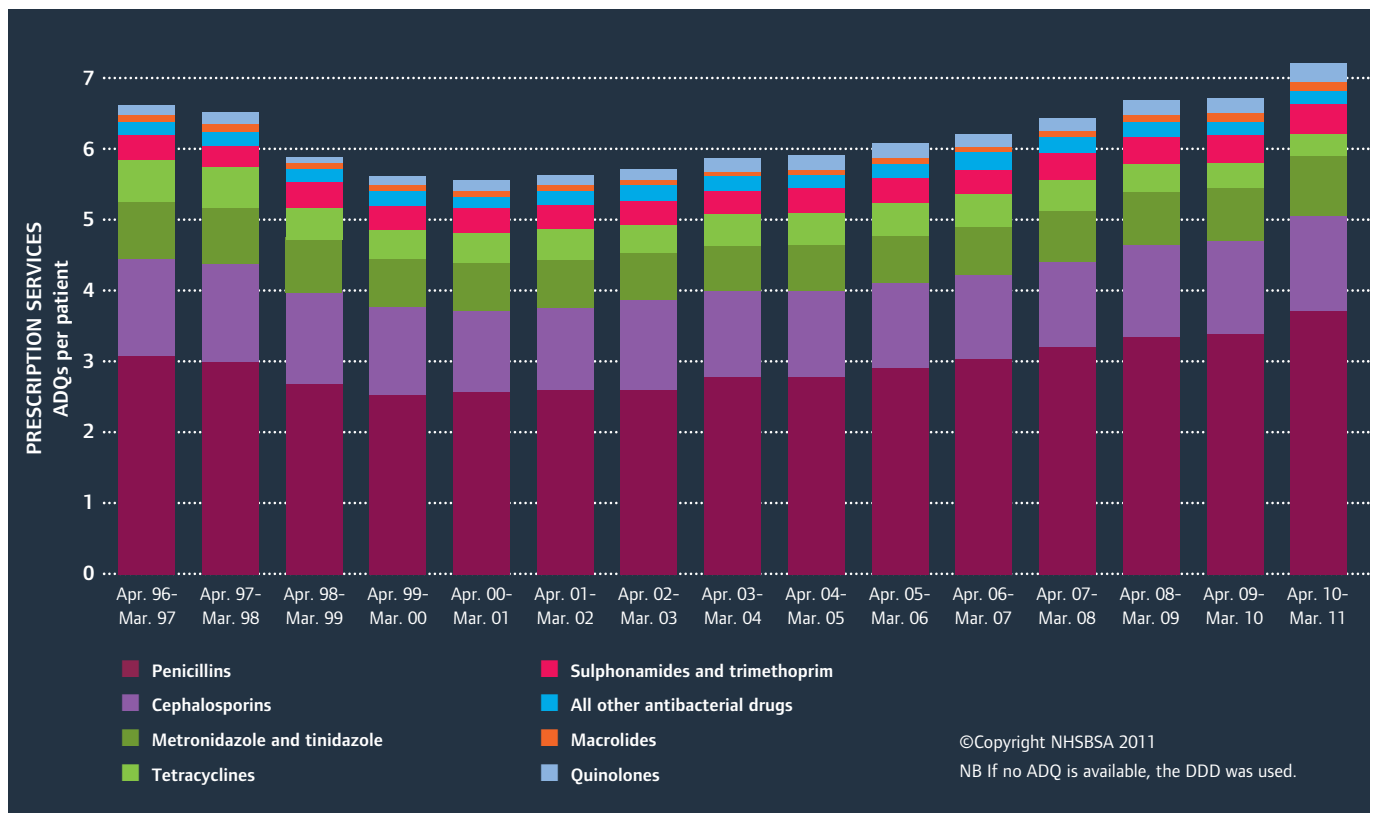


FIGURE 1: Trends in usage of antibacterials in general practice in England.⁷¹

sub-lethal doses of an antibiotic that, instead of killing them, allows them to develop genetic resistance against the antibiotic. Antibiotics can also kill beneficial bacteria in our microbiomes. There is thought to be a relationship between the theorised disturbance in the human microbiome through antibiotic use and the unexpected rise in autoimmune diseases and allergies, particularly in Western countries (Figure 1). Autoimmunity is the failure of our own immune system to distinguish 'self' from 'non-self'. This failure can lead to an immune response being mounted against our own cells and tissues. Examples of autoimmune diseases include rheumatoid arthritis, lupus, diabetes and coeliac disease. Current thinking is that antibiotics cause the loss of normal microbiome constituents, removing the necessary triggers for normal immune system development. As a result, an underdeveloped immune system might possibly encourage autoimmune diseases to develop.⁶

Healthcare-associated infections

The number of infections emerging due to multi-drug resistant organisms is rising sharply and the timeline for the development of new antibiotics is limited. A study comparing short-term (three days) with longer-term (five days) prophylaxis following excision of head and neck lesions found a significantly lower number of patients had wounds infected by methicillin-resistant *Streptococcus aureus* (MRSA) in the shorter term group.⁷ Antibiotic resistance adversely affects patient outcomes and increases the length of their hospital stays. In addition, there are tremendous healthcare expenses involved in developing new drug therapies to treat such patients. Administration of antibiotics also predisposes patients to infection with

Clostridium difficile, which causes antibiotic-associated colitis.⁸ Some 5% of healthy adults carry low concentrations of *C. difficile* in their colon asymptotically.⁹ The overuse of antibiotics by dentists can upset the harmony of bacteria in the gut. *C. difficile* infection occurs when these bacteria multiply and produce toxins, resulting in symptoms such as diarrhoea and fever. Patients who have been treated with broad-spectrum antibiotics are at the greatest risk.¹⁰

There were 1,696 new cases of *C. difficile* infection documented in Ireland throughout 2010. The majority of these patients completely recovered; however, on rare occasions this infection proved fatal.¹¹ More conservative antibiotic prescribing is imperative to reduce the number of emerging healthcare-associated infections.

Antibiotic stewardship

Antimicrobial stewardship is an organisational approach to promoting and monitoring conservative use of antimicrobials to maintain their ongoing effectiveness.¹²

The objective of antimicrobial stewardship is to improve antibiotic prescribing patterns. Antibiotic resistance poses a threat to the elderly, to children, and to patients with weakened immune systems. However, an increase in infections that are more difficult to treat not only affects vulnerable patients but also the wider community. Bacterial resistance can complicate the treatment of even mild infections.

Educating the dental profession and the public in the judicious use of antibiotics as part of an antimicrobial stewardship programme is imperative in

safeguarding this vital medicine. Unfortunately, patients have come to expect antibiotics for ‘toothache’, which is an inflammatory condition and best managed with local measures in combination with analgesics. Good communication and reassurance by the dental profession must enforce antibiotic stewardship. However, an unscheduled emergency often presents a profoundly difficult situation for the dentist. As a profession, we are increasingly vulnerable to regulatory criticism if we cannot justify our care to our patients in circumstances of acute pain.

Doron and Davidson stressed three important aims with antimicrobial stewardship:¹³

- ▶ optimise treatment for patients;
- ▶ prevent inappropriate prescribing; and,
- ▶ reduce the development of resistance in the individual patient and therefore the wider community.

The dental profession must show leadership in slowing the development of antimicrobial resistance by demonstrating more judicious prescribing in both private and hospital settings.

Indications for therapeutic antibiotic treatment in oral surgery¹⁴

Therapeutic antibiotic treatment is the use of substances that reduce the growth or reproduction of bacteria, including eradication therapy.¹⁵ In the field of oral surgery, clinical situations that require antibiotic therapy include:

- ▶ management of acute/chronic infections;
- ▶ management of active infective disease; and,
- ▶ immediate treatment if there is a delay due to unco-operative behaviour requiring referral to specialist services (this may happen if a dentist is unable to establish drainage and the patient requires sedation/general anaesthesia).¹⁶

Therapeutic antibiotics are also indicated where body temperature is elevated and where signs or symptoms of systemic spread, such as lymphadenopathy and trismus, exist. Facial cellulitis with or without dysphagia also requires immediate antibiotic treatment to prevent the spread of infection through lymph and blood circulation, which could culminate in septicaemia.¹⁷ Most dental infections can be successfully resolved by removal of the source. However, there is still a worrying tendency among dentists to favour an antibiotic prescription over immediate dental treatment.¹⁸

In managing dento-alveolar infections in children and immunocompromised patients early treatment is imperative. Local infections can spread very quickly, culminating in life-threatening consequences such as Ludwig’s angina.¹⁹

Acute dento-alveolar infections

Antibiotics are only indicated as an adjunct to local treatment where the patient’s temperature is increased and there is evidence of systemic spread and local lymph gland involvement.²⁰ If the infection has resolved three days post drainage or removal of the cause, and the temperature has returned to normal, then antibiotics can be stopped.²¹

Chronic dento-alveolar infections¹⁴

These usually present as a well-localised abscess, sometimes with a sinus, but rarely require antibiotics unless:

- ▶ grossly spreading, or if there is an acute flare-up of infection; or,
- ▶ increased temperature or malaise is present.

Pericoronitis

For patients presenting with localised pain and swelling involving the pericoronal tissues, and in the absence of regional and systemic symptoms, it is recommended that only local measures are used. These include debridement of plaque and food debris, drainage of pus, irrigation with sterile saline, chlorhexidine or hydrogen peroxide, and elimination of occlusal trauma.

In addition to local pain and swelling, if the patient is experiencing regional or systemic signs and symptoms, antimicrobial therapy is indicated. It is important to emphasise that this is an adjunct rather than a first-line treatment. Systemic symptoms include pyrexia, tachycardia and hypotension. The antibiotic of choice is metronidazole 400mg three times a day for five days or phenoxymethylpenicillin 500mg four times a day for five days. The two antimicrobials can be used in combination for severe infections. For patients who are allergic to penicillin, erythromycin 500mg four times a day for five days is suitable.²²

Antibiotic prophylaxis in oral surgery

Prophylactic antibiotic treatment is the use of antibiotics before, during or after a diagnostic, therapeutic or surgical procedure to prevent infectious complications.²³ If antibiotic prophylaxis is administered too late or too early it reduces the effectiveness of the antibiotic and may increase the risk of a surgical site infection.²⁴ It has been shown that administration of prophylaxis more than three hours after the start of the procedure dramatically reduces its efficacy.²⁵

Historically, antibiotics were prescribed to prevent bacteraemias and metastatic infections resulting from dental procedures. The British Society of Antimicrobial Chemotherapy (BSAC) and the National Institute for Health and Clinical Excellence (NICE) have reviewed the evidence for bacteraemias in relation to cardiac patients. They concluded that the chance of developing a bacteraemia is greater from chewing and toothbrushing than from dental treatments.²⁶ It was found that even if antibiotic prophylaxis was 100% effective, it might only help to prevent a very small number of infective endocarditis cases.²⁷

The NICE guidelines state that there is no requirement to prescribe antibiotics for patients with acquired or congenital endocardial disease.²⁸ Likewise, for patients with total joint replacements, the BSAC found no evidence to support antibiotic prophylaxis when dental treatment is required.²⁹

However, amid the backdrop of universally conflicting arguments, NICE has recently announced that it is to immediately review its 2008 guidelines following new research published at a meeting of the American Heart Association in Chicago in November 2014. The new research suggests that the number of people developing infective endocarditis in the UK has increased following the publication of the NICE guidelines.³⁰ This raises the concern that despite a lack of supporting evidence for antibiotic prophylaxis, perhaps the total abolition of cover may have been a step too far? The need for more randomised prospective research is clear.

Risks of antibiotic prophylaxis

Side effects of antibiotics include diarrhoea, allergy, gastrointestinal upset and a potentially fatal anaphylactic reaction. However, the incidence of fatal anaphylactic reactions was found to be extremely low where a single dose of oral amoxicillin is concerned. Over a 50-year period, the AHA is unaware of any cases of fatal anaphylaxis resulting from the administration of penicillin

recommended in their guidelines.²⁷ To date, there is only one documented case of a fatal anaphylaxis in the GlaxoSmithKline Global records.³¹

Prophylactic antibiotic use in third molar surgery

Current research states that 12 people would need to receive antibiotic prophylaxis to prevent one infection.³² Antibiotics are frequently prescribed in a prophylactic way in cases where surgery is complex, and in patients suffering from systemic conditions causing immunodeficiency such as HIV, diabetes and cancer.³³ It is likely that antibiotics are more advantageous in immunocompromised patients, as infections in this group are more frequent and difficult to resolve.

However, there is no evidence that antibiotics prevent fever, swelling or problems with restricted mouth opening in patients who have had their wisdom teeth extracted. Therefore, the administration of antibiotics in healthy people to eliminate the risk of infections may cause more harm than benefit to both the individual patient and the wider population. The use of antibiotics was found to lead to at least one mild adverse effect for every 21 people treated.³² In oral surgery there appears to be very little clinical gain from prescribing postoperative antibiotics alone. There is no evidence to advise the use of antibiotics after surgical extraction of impacted teeth/roots to reduce infection postoperatively. The evidence clearly indicates that there is no decrease in postoperative infection, pain, swelling or wound healing.³⁴ It appears that medically compromised patients benefit the most from antibiotic therapy.

Immunocompromised patients

There is no definitive evidence that the routine use of prophylactic antibiotics is advisable in patients with the following conditions:³⁵ leukaemia, immunosuppressive drugs following organ transplantation, lymphoma, anti-cancer chemotherapy, poorly controlled diabetes and HIV. Treatment should be carried out after correspondence with the patient's specialist.

Bisphosphonate-related osteonecrosis of the jaw

The scientific evidence does not support the routine administration of antibiotics in this patient cohort when undergoing dental procedures.³⁶

Radiotherapy

Patients with a history of radiotherapy for head and neck cancer are at a very high risk of developing osteoradionecrosis (ORN) following even straightforward extractions or biopsies.³⁷ There is controversy around identifying the most suitable antimicrobial regime. A recent survey of oral and maxillofacial consultants in the UK showed wide variation in practice. Most were in favour of preoperative antimicrobial use for the surgical removal of lower posterior teeth, and 89% advised a postoperative antibiotic course. Much of the controversy surrounds the microbial involvement in the pathogenesis of ORN, which is still unclear.³⁸

If a tooth is of hopeless prognosis, then advice on management should be attained from a maxillofacial surgeon. The risk of osteonecrosis of the jaw is high in this patient cohort and increases with time. Poor blood flow and tissue penetration in the irradiated site make the use of antimicrobials debatable.³⁹

Management of dry socket

Dry socket is a post-extraction complication, which follows the breakdown of the blood clot and occurs as a result of bacterial invasion. Its incidence is in the

region of 4%.⁴⁰ The aetiology of dry socket is related to systemic factors, localised infection and surgical trauma. Antibiotics are only recommended in the presence of spreading infection.³²

Studies have proven that approximately 38 healthy people would need to be treated with prophylactic antibiotics to prevent a single case of dry socket.³²

Surgical endodontics

A recent systematic review highlighted that prescribing prophylactic antibiotics to prevent systemic disease is not always in the patient's best interests.²⁸ Similarly, prophylactic administration to prevent postoperative infection has not been shown to be advantageous.⁴¹ Antibiotics should only be prescribed where signs of systemic involvement exist, with lymphadenopathy and pyrexia, along with appropriate surgical drainage if required.⁴² The RCS Surgical Endodontic Guidelines recommend preoperative and postoperative chlorhexidine mouthwashes as being the best method of preventing infections.⁴³

Therefore, the only indications for antibiotic therapy in surgical endodontics include infections with:

- ▶ gross local spread;
- ▶ systemic involvement; and,
- ▶ where treatment must be delayed or in cases where drainage is impossible and periradicular surgery is needed.

Current evidence highlights that postoperatively antibiotics do not decrease swelling, percussion pain or the amount of analgesics needed to alleviate symptoms.^{44,45}

Dental implant placement

There is very limited evidence to support the use of routine prophylactic antimicrobials in implant therapy. Where good asepsis is absent, it has been proven that antimicrobials are ineffective.⁴⁶ A meta-analysis, however, recommends the following protocol to reduce the failure of implants:

- ▶ amoxicillin 2g one hour preoperatively; or,
- ▶ in patients allergic to penicillin, clindamycin 600mg one hour preoperatively.

Prophylactic antibiotics given orally one hour preoperatively seem to reduce early dental implant failure; however, no differences in postoperative infections have been observed by some authors.⁴⁷ It is, however, considered good practice to recommend antibiotics where immediate implants are placed into extraction sockets.⁴⁸ The use of prophylactic antibiotics is indicated for patients at risk of endocarditis, those with immunodeficiencies, those with metabolic diseases, patients who have been irradiated in the head and neck, and when extensive and prolonged surgery is expected.⁴⁹ Prophylaxis should not be extended beyond the first three postoperative days since it does not appear to result in additional protection.⁵⁰

Perioperative antibiotic prophylaxis is advised when intraoral bone grafting is necessary prior to dental implant placement, even though there are no studies with high-level evidence to support this. It appears that the risk of infection with implants is less when preoperative and postoperative antibiotics are prescribed.^{51,52,53}

Maxillofacial fractures

Prophylactic antibiotics in the treatment of compound mandibular fractures have been shown to reduce the incidence of postoperative infection to 6%

compared with 50% in patients not receiving prophylactic antibiotics.⁵⁴ Currently, there is no data supporting the use of postoperative antibiotics.⁵⁵ The efficacy of prophylactic antibiotics in the management of craniofacial fractures remains highly controversial. A systematic review advises perioperative antibiotics in all facial thirds and preoperative antibiotics in comminuted mandibular fractures. Postoperative antibiotics were not recommended in any facial third.⁵⁶

Auditing current practice

It is clear that more short period antibiotic audits, which are held at regular intervals with stakeholder feedback, are needed. These help to ascertain the number of prescriptions written, their appropriateness, and also to highlight areas of prescribing knowledge lacking in the dental practice. Within clinical practice, audits have been shown to positively encourage appropriate prescribing patterns.⁵⁷ However, it must also be understood that prescriptions are an indirect measure of antibiotic consumption and do not precisely reflect the rate of emerging resistance, which is multifactorial.⁵⁸

The General Dental Council (GDC) in the UK has outlined responsible prescribing standards for dentists. These state that a drug should only be prescribed when appropriate. In recent years the GDC has reprimanded an increasing number of dentists regarding inappropriate antibiotic prescribing. These malpractices included giving a prescription without seeing the patient, not checking for allergies and failing to initiate drainage as the first line of treatment.⁵⁹

Dental prescribing by practitioners outside the dental profession

In the case of out-of-hours emergencies, patients often consult their GP before their dentist. GPs are more likely to prescribe antibiotics than dentists for acute dental problems.⁶⁰ Therefore, where oral infections are concerned, antibiotic prescribing is not exclusive to dentists. Other healthcare professionals also contribute to the threat of antibiotic resistance.

The Infectious Diseases Society of America recommends the use of specific antibiotic order forms to prevent inappropriate prolongation of antibiotic prophylaxis. These have been shown to reduce inappropriate prescribing from 64% to 21%.⁶¹

Use of microbiology laboratories by the dental profession

Diagnostic microbiology laboratories are an excellent resource for helping dentists with therapeutic decisions. Yet within the profession bacteriological sampling mostly occurs when empirical therapy has proven unsuccessful.⁶² Evidence of inappropriate prescribing within the dental profession indicates that the facility is grossly underused.⁶³ Diagnostic microbiology laboratories could also assist more in resistance surveillance and in the development of local policies and guidelines.⁶⁴

Are we taking the problem seriously enough in dentistry?

Every year on November 18, European Antibiotic Awareness Day aims to increase knowledge among patients and healthcare professionals about antibiotic resistance.⁶⁵ The Thunderclap Initiative also coincides with this date to harness social media networks to help spread the message that 'infection needs drainage before considering antibiotics'.⁶⁶

It is critically important that the dental profession enforces antibiotic stewardship programmes.⁶⁷ Currently in Ireland, there are no national legislative

or regulatory mandates optimising the use of antibiotics through stewardship programmes. There is also no national surveillance system to determine the extent of resistance and to monitor the use of antibiotics.⁶⁸

With regard to patient compliance, the dental profession could show leadership by encouraging patients to return uncompleted antibiotic courses to them. Currently, government ministers have no official policy on this. More controlled disposal of antibiotics could prevent their release into the environment, where they may have deleterious effects on environmental microbes by selecting for more resistance. Perhaps in the future the Irish Dental Association could find a mechanism of destroying these unwanted antibiotics.

Antibiotic resistance is a real and imminent threat to the health and well-being of our nation and indeed the global community. Action is urgently needed to slow resistance by pledging to cut antibiotic overuse. As a profession we have a duty of care to follow the 'path of least resistance' in protecting this life-saving medicine.

References

1. **World Health Organisation.** Antimicrobial resistance. Global Report on Surveillance 2014 Summary.
2. **Aronsson, B., Boscan, I.S., Cars, O., Giamarellou, H., Gyssens, I.C., Lutsar, I., et al.** The Bacterial Challenge: Time to React. Joint Technical Report from the European Centre for Disease Prevention and Control and European Medicines Agency. Stockholm: ECDC, 2009.
3. **Dar-Odeh, N.S., Abu Hammad, O.A., Al-Omiri, M.K., Khraisat, A.S., Shehabi, A.A.** Antibiotic prescribing practices by dentists: a review. *Ther Clin Risk Manag* 2010; 6: 301-306.
4. **Palmer, N.A., Pealing, R., Ireland, R.S., Martin, M.V.** A study of prophylactic antibiotic prescribing in National Health Service general dental practice in England. *Br Dent J* 2000; 189 (1): 43-46.
5. **Human Microbiome Project Consortium.** Structure, function and diversity of the healthy human microbiome. *Nature* 2012; 486: 207-214.
6. **Honda, K., Littman, D.R.** The microbiome in infectious disease and inflammation. *Annual Rev Immunol* 2012; 30: 759-795.
7. **Avery, C.M.E., Ameerally, P., Castling, B., Swann, R.A.** Infection of surgical wounds in the maxillofacial region and free flap donor sites with methicillin-resistant *Staphylococcus aureus*. *British Journal of Oral and Maxillofacial Surgery* 2006; 44 (3): 217-221.
8. **Jobe, B.A., Grasley, A., Deveney, K.E., Deveney, C.W., Sheppard, B.C.** *Clostridium difficile* colitis: an increasing hospital-acquired illness. *Am J Surg* 1995; 169 (5): 480-483.
9. **Nelson, R.L., Kelsey, P., Leeman, H., et al.** Antibiotic treatment for *Clostridium difficile*-associated diarrhea in adults. *Cochrane Database Syst Rev* 2011; (9): CD004610.
10. **Office for National Statistics.** Statistical Bulletin. Deaths involving *Clostridium difficile*. England and Wales, 2011. Office for National Statistics, 2012.
11. **Health Service Executive.** Preventing *Clostridium difficile* infection. [Internet] Available from: <http://www.hse.ie/eng/health/az/C/C-diff/Preventing-Clostridium-difficile-infections.html>.
12. **Ridge, K.W., Hand, K., Sharland, M., Abubaker, I., Livermore, D.M.** Antimicrobial Resistance. In: CMO Annual Report of the Chief Medical Officer. Volume Two, 2011. Infections and the rise of antimicrobial resistance. [Internet] Available from: <http://www.dh.gov.uk/health/2013/03/cmo-vol2/>.
13. **Doran, S., Davidson, L.E.** Antimicrobial stewardship. *Mayo Clin Proc* 2011; 86 (11): 1113-1123.

14. **Faculty of General Dental Practice (UK).** Antimicrobial Prescribing For General Dental Practitioners. FGDP Guidelines 2014. [Internet] Available from: <http://www.fgdp.org.uk/content/publications/antimicrobial-prescribing-for-general-dental-pract.ashx>.
15. **National Centre for Biotechnology Information (NCBI).** NCBI Medline thesaurus. Search terms: antibacterial agent, therapeutic use. [Internet] Available from: www.ncbi.nlm.nih.gov/entrez/query.fcgi?CMD=search&DB=mesh.
16. **Brennan, M.T., Runyon, M.S., Batts, J.J., Fox, P.C., Kent, M.L., Cox, T.L., et al.** Odontogenic signs and symptoms as predictors of odontogenic infection: a clinical trial. *J Am Dent Assoc* 2006; 137 (1): 62-66.
17. **Swift, J.Q., Gulden, W.S.** Antibiotic therapy – managing odontogenic infections. *Dent Clin N Am* 2002; 46: 623-633.
18. **Barker, G.R., Qualtrough, A.J.E.** An investigation into antibiotic prescribing at a dental teaching hospital. *British Dental Journal* 1987; 162: 303-306.
19. **Sandor, G.K., Low, D.E., Judd, P.L., Davidson, R.J.** Antimicrobial treatment options in the management of odontogenic infections. *J Can Dent Assoc* 1998; 64 (7): 508-514.
20. **Matthews, D., Sutherland, S.** Clinical practice guidelines on emergency management of acute apical periodontitis and acute apical abscess. *Evid Based Dent* 2004; 5: 7-11.
21. **Martin, M.V., Longman, L.P., Hill, J.B., Hardy, P.** Acute dento-alveolar infections: an investigation of the duration of antibiotic therapy. *Br Dent* 1997; 183 (4): 135-137.
22. **Moloney, J., Stassen, L.F.A.** Pericoronitis: treatment and a clinical dilemma. *Journal of the Irish Dental Association* 2009; 55 (4): 190-192.
23. **National Centre for Biotechnology Information (NCBI).** NCBI Medline thesaurus. Search terms: antibiotic prophylaxis.
24. **Baum, M.L., Anish, D.S., Chalmers, T.C., Sacks, H.S., Smith, H., Jr, Fagerstrom, R.M.** A survey of clinical trials of antibiotic prophylaxis in colon surgery: evidence against further use of no-treatment controls. *N Engl J Med* 1981; 305 (14): 795-799.
25. **Classen, D.C., Evans, R.S., Pestotnik, S.L., Horn, S.D., Menlove, R.L., Burke, J.P.** The timing of prophylactic administration of antibiotics and the risk of surgical-wound infection. *N Engl J Med* 1992; 326 (5): 281-286.
26. **Gould, F.K., Elliott, T.S., Foweraker, J., Fulford, M., Perry, J.D., Roberts, G.J., et al.** Guidelines for the prevention of endocarditis: report of the Working Party of the British Society for Antimicrobial Chemotherapy. *J Antimicrob Chemother* 2006; 57 (6): 1035-1042.
27. **Wilson, W., Taubert, K.A., Gewitz, M., Lockhart, P.B., Baddour, L.M., Levison, M., et al.** Prevention of infective endocarditis: guidelines from the American Heart Association: a guideline from the American heart Association Rheumatic Fever, Endocarditis and Kawasaki Disease Committee, Council on Cardiovascular Disease in the Young and the Council on Clinical Cardiology, Council on Cardiovascular Surgery and Anesthesia and the Quality of Care and Outcomes Research Interdisciplinary Working Group. *J Am Dent Assoc* 2007; 138 (6): 739-745, 747-760.
28. **National Institute for Health and Care Excellence.** CG64: Antimicrobial prophylaxis against infective endocarditis in adults and children undergoing interventional procedures. London: NICE; 2008. [Internet] Available from: <http://guidance.nice.org.uk/CG64>.
29. **Simmons, N.A., Ball, A.P., Cawson, R.A., Eykyn, S.J., Hughes, S.P., McGowan, D.A., et al.** Case against antibiotic prophylaxis for dental treatment of patients with joint prostheses (Letter). *Lancet* 1992; 339 (8788): 301.
30. **National Institute for Health and Care Excellence.** NICE to review its guidance on the use of antibiotics to prevent infective endocarditis. [Internet] Available from: www.nice.org.uk.
31. **Stassen, L., Rahman, N., Rogers, S., Ryan, D., Healy, C., Flint, S.** Infective endocarditis prophylaxis and the current AHA, BSAC, Nice and Australian guidelines. *Journal of the Irish Dental Association* 2008; 54 (6): 264-270.
32. **Lodi, G., Figini, L., Sardella, A., Carrassi, A., Del Fabbro, M., Furness, S.** Antibiotics to prevent complications following tooth extractions. *Cochran Database Syst Rev* 2012; 11: CD003811.
33. **Epstein, J.B., Chong, S., Le, N.D.** A survey of antibiotic use in dentistry. *J Am Dent Assoc* 2000; 131 (11): 1600-1609.
34. **Siddiqi, A., Morkel, J.A., Zafar, S.** Antibiotic prophylaxis in third molar surgery. A randomized double-blind placebo-controlled clinical trial using split-mouth technique. *Int J Oral Maxillofac Surg* 2010; 39 (2): 107-114.
35. **Joint Formulary Committee.** *British National Formulary (68th ed.)*. London: British Medical Association and Royal Pharmaceutical Society of Great Britain, 2014.
36. **Edwards, B.J., Hellstein, J.W., Jacobsen, P.L., Kaltman, S., Mariotti, A., Migliorati, C.A.** Updated recommendations for managing the care of patients receiving oral bisphosphonates therapy: an advisory statement from the American Dental Association Council on Scientific Affairs. *J Am Dent Assoc* 2008; 139: 1674-1677.
37. **Cayman, L.** Clinical controversies in oral and maxillofacial surgery: Part two. Management of dental extractions in irradiated jaws: a protocol without hyperbaric oxygen therapy. *J Oral Maxillofac Surg* 1997; 55: 275-281.
38. **Kanatas, A.N., Rogers, S.N., Martin, M.V.** A survey of antibiotic prescribing by maxillofacial consultants for dental extractions following radiotherapy in the oral cavity. *Br Dental J* 2002; 192: 157-160.
39. **Koga, D.H., Salvajoli, J.V., Alves, F.A.** Dental extractions and radiotherapy in head and neck oncology: review of the literature. *Oral Dis* 2008; 14 (1): 40-44.
40. **Monaco, G., Staffolani, C., Gatto, M.R., Checchi, L.** Antibiotic therapy in impacted third molar surgery. *Eur J Oral Sci* 1999; 107 (6): 437-441.
41. **Lindenboom, J.A.H., Frenkan, J.W.H., Valkenburg, P., Van den Akker, H.P.** The role of preoperative prophylactic antibiotic administration in periapical endodontic surgery: a randomized, prospective double-blind placebo-controlled study. *Int Endod J* 2005; 38: 877-881.
42. **Freedman, A., Horowitz, I.** Complications after apicectomy in maxillary premolar and molar teeth. *Int J Oral Maxillofacial Surg* 1999; 28: 192-194.
43. **Evans, G.E., Bishop, K., Renton, T.** Guidelines for Surgical Endodontics – the position after ten years. *Br Dent J* 2012; 212 (10): 497-498.
44. **Pickenpaugh, L., Reader, A., Beck, M., Meyers, W.J., Peterson, L.J.** Effect of prophylactic amoxicillin on endodontic flare-up in asymptomatic, necrotic teeth. *J Endod* 2001; 27 (1): 53-56.
45. **Henry, M., Reader, A., Beck, M.** Effect of penicillin on postoperative endodontic pain and swelling in symptomatic necrotic teeth. *J Endod* 2001; 27 (2): 117-123.
46. **Abu-Ta'a, M., Quirynen, M., Teughels, W., van Steenberghe, D.** Asepsis during periodontal surgery involving oral implants and the usefulness of peri-operative antibiotics: a prospective randomized controlled clinical trial. *J Clin Periodontol* 2008; 35 (1): 58-63.
47. **Esposito, M., Worthington, H.V., Loli, V., Coulthard, P., Grusovin, M.G.** Interventions for replacing missing teeth: antibiotics at dental implant placement to prevent complications. *Cochrane Database Syst Rev* 2010; (7): CD004152.
48. **Binahmed, A., Stoykewych, A., Peterson, L.** Single preoperative dose versus long-term prophylactic antibiotic regimens in dental implant surgery. *Int J Oral Maxillofac Implants* 2005; 1: 115-117.

49. **Esposito, M., Coulthard, P., Oliver, R., Thomsen, P., Worthington, H.V.** Antibiotics to prevent complications following dental implant treatment (Review). *Cochrane Database Syst Rev* 2003; (3): CD004152.
50. **Fleming, P., Feigal, R.J., Kaplan, E.L., Liljemark, M.F., Little, J.W.** The development of penicillin-resistant oral streptococci after repeated penicillin prophylaxis. *Oral Surg Oral Med Oral Pathol* 1990; 70 (4): 440-444.
51. **Kraut, R.A.** Clean operating conditions for the placement of intraoral implants. *J Oral Maxillofac Surg* 1996; 54: 1337-1338.
52. **Dent, C.D., Olsor, J.W., Farish, S.E., et al.** The influence of preoperative antibiotics on success of endosseous implants up to and including stage II surgery: a study of 2641 implants. *J Oral Maxillofac Surg* 1997; 55 (Suppl. 5): 16-24.
53. **Laskin, D.M., Dent, C.D., Morris, H.F., et al.** The influence of preoperative antibiotics on success of endosseous implants at 36 months. *Ann Periodontol* 2000; 5: 166-174. Three references there supporting pre and post antibiotics for implants.
54. **Zallen, R.D., Curry, J.T.** A study of antibiotic usage in compound mandibular fractures. *J Oral Surg* 1975; 33: 431-434.
55. **Miles, B.A., Potter, J.K., Ellis, E.** The efficacy of postoperative antibiotic regimens in the open treatment of mandibular fractures: a prospective randomized trial. *J Oral Maxillofac Surg* 2006; 64: 576-582.
56. **Munding, G.S., Borsuk, D.E., Okhah, Z., Christy, M.R., Bojovic, B., Dorafshar, A.H., et al.** Antibiotics and facial fractures: evidence-based recommendations compared with experience-based practice. *Craniofacial Trauma Reconstr* 2015; 8 (1): 64-78.
57. **Palmer, N.O., Martin, M.V., Pealing, R., et al.** Antibiotic prescribing knowledge of national health service general dental practitioners in England and Scotland. *Journal of Antimicrobial Chemotherapy* 2001; 47: 233-237.
58. **Heritage, J., Wilcox, M., Sandoe, J.** Antimicrobial resistance potential. *Lancet* 2001; 358 (9287): 1099-1100.
59. **General Dental Council (UK).** Responsible Prescribing. [Internet] Available from: www.gdc-uk.org.
60. **Anderson, R., Calder, L., Thomas, D.W.** Antibiotic prescribing for dental conditions: general medical practitioners and dentists compared. *British Dental Journal* 2000; 188: 398-400.
61. **Marr, J.J., Moffet, H.L., Kunin, C.M.** Guidelines for improving the use of antimicrobial agents in hospitals: a statement by the Infectious Diseases Society of America. *J Infect Dis* 1988; 157 (5): 869-876.
62. **Roy, K.M., Smith, A., Sanderson, J., et al.** Barriers to the use of a diagnostic oral microbiological laboratory by general dental practitioners. *British Dental Journal* 1999; 186: 345-347.
63. **Sweeney, L.C., Dave, J., Chambers, P.A., Heritage, J.** Antibiotic resistance in general dental practice – a cause for concern? *Antimicrob Chemother* 2004; 53 (4): 567-576.
64. **Roy, K.M., Smith, A., Sanderson, J., et al.** Barriers to the use of a diagnostic oral microbiology laboratory by general dental practitioners in England and Scotland. *Journal of Antimicrobial Chemotherapy* 1999; 47: 233-237.
65. **European Antibiotic Awareness Day.** [Internet] Available from: <http://ecdc.europa.eu/en/EAAD/Pages/Home.aspx>.
66. **Antibiotic Action in Dentistry.** European Antibiotic Awareness Day. [Internet] Available from: <https://www.thunderclap.it/en/projects/6598-antibiotic-action-in-dentistry>.
67. **Crighton, A.** Antibiotic stewardship. *British Dental Journal* 2011; 211: 443.
68. **Bax, R., Bywater, R., Cornaglia, G., et al.** Surveillance of antimicrobial resistance – what, how, whether? *Clinical Microbiology and Infection* 2001; 7: 316-325.
69. **Ashiru-Oredope, D., et al.** Improving the quality of antibiotic prescribing in the NHS by developing a new Antimicrobial Stewardship Programme: Start Smart – Then Focus. *J Antimicrob Chemother* 2012; 67 (Suppl. 1): i51-i63.

Success and survival of autotransplanted premolars and molars during short-term clinical follow-up

Verweij, J.P., Toxopeus, E.E., Fiocco, M., Mensink, G., van Merkesteyn, J.P.R.

Aim

Autotransplantation is an elegant therapy for single tooth replacement that is too often overlooked in patients with missing teeth. Especially, autotransplantation of third molars to replace heavily damaged or missing molars is often not considered. This study investigated the success and survival of autotransplanted premolars and molars during clinical follow-up.

Materials and methods

The medical files and radiographs of 97 consecutive patients were retrospectively investigated. Seventy-nine patients could be included in this study. Autotransplantation of 97 premolars and 14 molars (111 procedures) was performed. The median follow-up time was equal to 13.4 months.

Results

In this study group, 82% of transplanted teeth were classified as successful and 98.2% were present at the end of follow-up. No transplants were extracted during standard follow-up of one year. The five-year tooth survival probability was 87.5% (95% CI, 64.5-100). One premolar and one molar were extracted, respectively, four and nine years after autotransplantation.

Conclusions

These results show that autotransplantation is associated with high success and survival rates, and can provide a reliable treatment option for tooth replacement in young patients. Further research regarding long-term outcome is necessary to assess if the transplanted teeth function as normal teeth after clinical follow-up.

Journal of Clinical Periodontology 2015; 43 (2): 167-172.

Efficacy of the Nance appliance as an anchorage-reinforcement method

Al-Awadhi, E.A., Garvey, T.M., Alhag, M., Claffey, N.M., O'Connell, B.

Introduction

The Nance appliance is widely considered to be an efficient method of anchorage reinforcement; however, much of the perceived advantage is based on clinical judgment. The aim of this study was to assess the amounts of anchorage loss and desired tooth movement associated with the Nance appliance.

Methods

The mandibular arches of seven beagle dogs were used. The first and third premolars were extracted. Reference miniscrews were placed at the first premolar sites as stable references to measure the amounts of anchorage loss and desired tooth movement. Four beagles were fitted with custom-made Nance appliances on the fourth premolars and orthodontic bands on the second premolars (Nance group). Three beagles were fitted with orthodontic bands on the second and fourth premolars, with no anchorage reinforcement (control group). The second premolars were retracted over 15 weeks in both

groups. The amounts of second premolar movement (desired tooth movement) and fourth premolar movement (anchorage loss) were recorded at five, 10 and 15 weeks. The percentages of desired tooth movement and anchorage loss to the total space closure were calculated.

Results

The mean desired tooth movement was significantly greater in the Nance group than in the control group at 10 weeks ($P < 0.05$) but was not significantly different at five and 15 weeks. The mean percentages of anchorage loss to the total space closure at 15 weeks were 45.7% in the control group and 28.8% in the Nance group. The Nance group had 16.9% less anchorage loss and 16.6% more desired tooth movement than did the control group at 15 weeks ($P < 0.05$). Most of the anchorage loss (80%) in the Nance group occurred during the first 10 weeks.

Conclusions

The Nance appliance did not provide absolute anchorage, but there was significantly less anchorage loss with it than in the control group. The majority of anchorage loss occurred during the first 10 weeks in the Nance group.

Am J Orthod Dentofacial Orthop 2015; 147 (3): 330-338.

Will you still be smiling at the end of the year?

Make sure your practice is profitable in 2016

As Ireland's only specialist dental accountants we're here to help you control your practice costs

QUARTERLY ACCOUNTS

PAYROLL SERVICES

TAX CONSULTANCY

COST OF TREATMENT

MedAccount offer a full range of specialist dental accounting support and advisory services for Associates, Principals, Expense Sharing Partners and Hygienists.

MedAccount Services

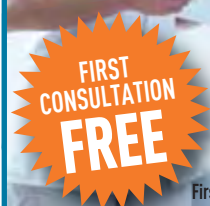96 Lower Georges Street

Dun Laoghaire

Co Dublin

Tel: 01 280 6414

Email: info@medaccount.ie



First consultation **FREE OF CHARGE** with no obligation to engage

Long-term follow up of revascularisation using platelet-rich fibrin

Ray Jr, H.L., Marcelino, J., Braga, R., Horwat, R., Lisien, M., Khaliq, S.

Introduction

Trauma is one of the primary causes of tooth loss and pulpal injury in adolescents and children. Prior to regenerative endodontics, treatment of necrotic, immature teeth with open apices was limited to long-term calcium hydroxide (Ca(OH)₂) apexification and subsequent root canal therapy or extraction. Through revascularisation, retention of these teeth can be achieved, and the elimination of patient symptoms and the radiographic appearance of continued root development were obtained.

Case review

This report illustrates a revascularisation protocol through a case where platelet-rich fibrin (PRF) was utilised as an autologous scaffold for traumatised, necrotic, immature teeth with incomplete root development. Through consistent follow-up reports, comprising both clinical examination and radiographs, marked improvement in the condition of the traumatised tooth was noted.

Discussion

This case demonstrates the feasibility of utilising PRF as an effective treatment protocol for traumatised teeth in lieu of traditional treatment protocols, such as long-term calcium hydroxide (Ca(OH)₂) apexification or extraction. The choice of utilising PRF, as opposed to other platelet concentrates such as platelet-rich plasma (PRP) or a blood clot, lies in PRF's ability to allow for a slow, long-term release of autologous growth factors.

Dental Traumatology 2016; 32 (1): 80-84.

Headache attributed to masticatory myofascial pain: impact on facial pain and pressure pain threshold

Costa, Y.M., Porporatti, A.L., Stuginski-Barbosa, J., Bonjardim, L.R., Speciali, J.G., Conti, P.C.R.

There is no clear evidence on how a headache attributed to temporomandibular disorder (TMD) can hinder the improvement of facial pain and masticatory muscle pain. The aim of this study was to measure the impact of a TMD-attributed headache on masticatory myofascial (MMF) pain management. The sample was comprised of adults with MMF pain measured according to the revised research diagnostic criteria for temporomandibular disorders (RDC/TMD) and additionally diagnosed with (Group 1, n = 17) or without (Group 2, n = 20) a TMD-attributed headache. Both groups received instructions on how to implement behavioural changes and use a stabilisation appliance for five months. The reported facial pain intensity (visual analogue scale – VAS) and pressure pain threshold (PPT – kgf cm⁻²) of the anterior temporalis, masseter and right forearm were measured at three assessment time points. Two-way ANOVA was applied to the data, considering a 5% significance level. All groups had a reduction in their reported facial pain intensity (P<0.001). Mean and standard deviation (SD) PPT values, from 1.33 (0.54) to 1.96 (1.06) kgf cm⁻² for the anterior temporalis in Group 1 (P = 0.016), and from 1.27 (0.35) to 1.72 (0.60) kgf cm⁻² for the masseter in Group 2 (P = 0.13), had significant improvement considering baseline versus the fifth-month assessment. However, no differences between the groups were found (P>0.100). A TMD-attributed headache in patients with MMF pain does not negatively impact pain management, but does change the pattern for muscle pain improvement.

Journal of Oral Rehabilitation 2016; 43 (3): 161-168.

Quiz Answers

Questions on page 78

1. What is this painful swelling and what causes it?

This is an (odontogenic) infection of the primary fascial space – “right masticator space abscess”.

The masticator space is a distinct deep fascial space, bounded by the superficial layer of the deep cervical fascia. It contains the ramus and posterior body of the mandible, and the four muscles of mastication (medial and lateral pterygoid muscle, temporal muscle and masseter muscle).¹

Thankfully, this is a relatively rare infection. The main causes of bacteria gaining entry to the space are:

1. Odontogenic (tooth extractions, periodontitis, pericoronitis, dental caries, pulpitis, etc.) – most common source.
2. Trauma (e.g., to the TMJ).
3. Surgery.
4. Injections (e.g., inferior alveolar nerve block).

The majority of these infections are confined to local lesions, while in some cases they spread from the affected tooth along the anatomic spaces, and they may occasionally advance to a site far from the initial infection.

2. What treatment should be carried out?

The basic principles in treating any space infection are antibiotic therapy, removal of the source of infection, and incision and drainage of the infected space.²

A preoperative CT scan was taken to assess the area of infection. This was followed by a combined approach of surgical drainage and medical management (in this case, IV antibiotics for five days in hospital followed by a seven-day course of oral antibiotics). Postoperative management of the limited mouth opening included the use of warm compresses and muscle relaxants, along with a course of NSAIDs to control symptoms.

Timely intervention prevented the spread of infection into the deep spaces of the neck. Early detection and aggressive management are done in order to evade dreaded complications.

References

1. **Fernandes, T. Lobo, J.C., Castro, R., et al.** Anatomy and pathology of the masticator space. *Insights Imaging* 2013; 4 (5): 605-616.
2. **Topazian, R.G., Goldberg, M.H.** Management of Infections of the Oral and Maxillofacial Regions (4th ed.). W.B. Saunders, 2002.

SITUATIONS WANTED

Enthusiastic, hardworking dentist seeking part-time work in southwest Dublin/north Kildare region. Available Monday afternoons and all day Tuesday. Email dentalassociate16@yahoo.com.

Hardworking, motivated dentist with 12 years' experience looking for a part-time position in southeast/west area of Dublin. Available to work Saturdays. Email dentistaa@ymail.com.

SITUATIONS VACANT

Full-time, experienced associate dentist required in a well-established practice in Ennis. OPG, digital x-ray, great team. Long-term view preferable. Replies to gbrowne.ennis@eircom.net.

Associate dentist with experience required for two days a week in busy, modern family practice in Celbridge, Co. Kildare. Digital x-ray. Good private/public mix. Replies by email to brian.corcoran26@gmail.com.

Associate wanted for state-of-the-art practice based in North Kildare. Immediate start. Minimum three years' experience required. Three to five days available for the right candidate DOE. CV and references essential. Email Jen@dentaloptions.ie.

Associate required in Newbridge practice. State-of-the-art, purpose-built practice, fully computerised, full dental and administrative support. Minimum three years' post-qualification practice experience desirable. Long-term options for right candidate. Email replies to andrewcox204@gmail.com.

Kilkenny City. Associate dentist required two to three days per week. Modern computerised practice with hygienist and visiting oral surgeon. Please reply via email to ayrfielddentalpractice@gmail.com.

Limerick and Clare. Start May 2016. Award-winning practice requires full-time associate. Fully computerised practice, Exact software, digital radiography, CBCT, Cerec Omnicam, excellent support staff. Suits motivated, hardworking individual with good emphasis on professional development – www.limerickdentist.com. Email annette_odonovan@hotmail.com.

Limerick City: busy private practice wishes a part-time associate to join our dental team. Contact Conor at Shields Dental, Tel: 061-480070 or 085-751 1529, or Email info@shieldsdentalcentre.ie.

Abbey Dental Care requires an associate dentist in an expanding dental surgery in Navan, Co. Meath, starting with one day a week (Friday), with potential for a full-time position for the right candidate. Please send CVs to abbeydentalcare365@gmail.com.

Midlands – full-time self-employed associate wanted for busy, well-equipped, progressive, modern practice. Full range of patients. 90 minutes from Dublin. City based. Three surgeries – OPG – hygienist. Computerised. Excellent support staff. Immediate start. Good remuneration. Contact: niall@innovativedental.com

Part-time associate required for busy dental practice in North Dublin. Email drjjconneely@gmail.com.

Associate required two days a week in Co. Kildare. General practice. OPG. Digital x-rays. Single-surgery practice. Long-term view preferable. Email CV to monasterevindental@gmail.com.

Dental associate with a minimum of three years' experience and IDC registered required for busy Rathfarnham practice. Fully computerised, digital rads and OPG. Initially required for Friday 2.00-8.00pm and Saturday mornings, with a view to extending hours. Email Info@mowldsental.ie.

Part-time dental associate (three days per week) required for well-established dental practice in Co. Meath. Digital x-rays, OPG, hygienist, great support staff. Commutable from Dublin. Email kieran.davitt@dentalcareireland.ie.

Associate dentist required to join modern, purpose-built practice in Limerick City. Very busy, friendly, progressive practice with OPG, new equipment, hygienist and excellent support staff. Experience preferable but mentorship provided. Tel: 087-796 5106.

Part-time associate dentist with experience required three days a week in busy, modern, family practice in Co. Clare. Fully computerised, three-surgery practice with hygienist. Candidates must be IDC registered. References essential. Forward CV to louise.roslevandental@gmail.com.

Conscientious, experienced, friendly associate required, initially two days per week, one to include Saturday, with long-term view, in Navan, Co. Meath. Private and PRSI only. Excellent support team, hygienist, computerised, OPG. Contact: brewshilldentalcentre@eircom.net.

Looking to launch your career in the right direction? Full-time associate position available, taking over mature book. Callan Dental operates from a brand new state-of-the-art facility in Kilkenny. See our virtual tour on Callandental.ie. Applications to jacquelineclune1@gmail.com.

Associate required – West of Ireland. Dynamic, flexible, experienced associate required. Immediate start. Full week. Busy, well-equipped practice. Knowledgeable, supportive staff. Excellent figures. Good earning potential. Email with CV and personal profile: niall@innovativedental.com.

Part-time associate dentist required to join state-of-the-art practice in Nenagh Town, Co. Tipperary. Very busy, friendly, progressive practice with excellent support staff. Experience preferable but mentorship provided. Please send your CV to contact@nenaghndental.ie.

Part-time locum dentist required for maternity leave from May to November in busy north Cork practice. Please email mallowdentist@gmail.com.

Enthusiastic, motivated dentist required for part-time position (two to three days per week) in busy, fully-computerised practice, located 30-40 minutes north of Dublin. Minimum three years' post-qualification practice experience desirable. Position available from May 2016. Experienced staff, digital OPT, Kavo chair/fibreoptics. Reply with CV to meathdentists@gmail.com.

Advertisements will only be accepted in writing via fax (01- 295 0092), letter or email (fionnuala@irishdentalassoc.ie). Non-members must pre-pay for advertisements, which must arrive no later than **Friday, May 6, 2016**, by cheque made payable to the Irish Dental Association. Classified ads placed in the *Journal* are also published on our website www.dentist.ie for 12 weeks.

Advert size	Members	Non-members
up to 25 words	€75	€150
26 to 40 words	€90	€180

The maximum number of words for classified ads is 40.

If the advert exceeds 40 words, then please contact:

Think Media, The Malthouse, 537 North Circular Road, Dublin 1.
Tel: 01-856 1166 Fax: 01-856 1169 Email: paul@thinkmedia.ie

Please note that all classified adverts MUST come under one of the following headings:

- ▶ Positions Wanted
- ▶ Practices for Sale/To Let
- ▶ Equipment for Sale/To Let
- ▶ Positions Vacant
- ▶ Practices Wanted

Classified adverts must not be of a commercial nature. Commercial adverts can be arranged by contacting Paul O'Grady at Think Media.

Part-time dentist required one to two days per week in a Wicklow practice. A mixed practice of GMS, PRSI and private patients. Please forward CV to ldental99@yahoo.ie.

Dentist required to cover leave period from May 3-28, 2016. We are a busy general practice located in Ballybrack, south county Dublin. Full-time and part-time applicants will be considered. Email jobs@ballybrackdental.ie.

Galway – Smiles Dental is looking for a passionate dentist to join our well-established, busy Smiles Galway practice. Candidates must have general private and public experience and be IDC registered. Five days per week. Email joanne.bonfield@smiles.co.uk.

Principal dentist position available in Citywest clinic, immediate start, Monday to Friday, minimum three years' experience, excellent remuneration. Candidate must be IDC registered. Invisalign training preferred. Please send CV to info@onsiteservice.com.

Motivated, enthusiastic dentist required for busy, modern north County Dublin practice. Practice is computerised, with digital x-ray and OPG. Full-time position, to initially cover maternity leave, with option of a long-term job. Email hello@swords-dental.ie.

Principal dentist position available in Limerick. Replacing departing colleague, commencing June 2016 three days per week, with a view to full-time. Full service lab attached, computerised, microscope, etc. Minimum three years' experience, IDC registration essential. Email dentistlimerick@gmail.com.

Part-time dentist wanted, south Tipperary. Saturday with view to expanding hours. Excellent staff. Mixed private, medical card and PRSI. Immediate start. Email westerndental@eircom.net.

Co. Dublin – exciting opportunity for an enthusiastic general dentist to join our modern, well-equipped, state-of-the-art Smiles practice in Swords on a full-time basis. Candidates must have general experience and be IDC registered. Email joanne.bonfield@smiles.co.uk.

Dublin – exciting opportunity for a strong, enthusiastic general dentist to join our well-established, busy Smiles O'Connell Street practice in Dublin 1. Full-time basis, five days per week. Candidates must have general experience and be IDC registered. Email joanne.bonfield@smiles.co.uk.

Clare/Limerick. Start May 2016. Multidisciplinary practice requires full-time general dentist. Fully computerised, Exact software, digital radiography, CBCT, Cerec Omnicam, excellent support staff. Suits motivated, enthusiastic and passionate dentist. Please email Dr O'Donovan: annettestaunton1@gmail.com.

Dentist required for part-time position in modern north County Dublin practice. Hours: Tuesday 8.00am-4.30pm and Saturday 9.00am-1.00pm. Practice fully computerised with digital x-ray and OPG. Reply: colinpatricklynam@hotmail.com.

Part-time dentist required in busy practice in Athlone. Great communication skills and minimum three years' experience necessary. OPG, digital x-ray, intra-oral camera, etc. Email CV to dentalvacancy@hotmail.com.

Dublin practice has vacancies for general and implant dentists. Offers the opportunity to receive external and in-house referrals. Full on-site laboratory. Applicants should be productive, quality driven and have confidence/experience in a range of disciplines. Please contact dentistdublinrecruit@gmail.com.

Co Mayo. Full-time, enthusiastic general dentist required to join a modern, well-established practice, taking over mature book. Excellent support team, hygienist, computerised, OPG/digital x-rays. Candidates must have general experience and good communication skills. Please email info@tobindental.com.

Smiles Dental is looking for a passionate dentist to join our well-established, vibrant Tallaght practice in Dublin. Practice offers modern facilities. Must have experience and be IDC registered. Wednesday to Friday with a view to increase. Email joanne.bonfield@smiles.co.uk.

Drogheda – Smiles Dental is looking for a passionate dentist to join our well-established, busy Drogheda practice in Co. Louth. Practice offers modern facilities and is fully computerised. Must have experience and be IDC registered. Five days per week. Email joanne.bonfield@smiles.co.uk.

Part-time orthodontist required for busy, modern practice in north Dublin. Please send CV to northcitydental@gmail.com.

Specialist orthodontist required for busy modern north County Dublin practice. Five GDPs, practice computerised with digital OPG and visiting oral surgeon. One session per month to start, with potential to increase hours soon after. Email hello@swords-dental.ie.

Orthodontist – Smiles Dental is looking for an experienced, motivated specialist-registered orthodontist to join our modern, state-of-the-art practice in Swords, Co. Dublin. Initially one day per week with a view to increase. Email joanne.bonfield@smiles.co.uk.

Orthodontist required for our busy, friendly, specialist orthodontic practice in north County Dublin – purpose-built clinic with excellent facilities. Good referral base and flexible sessions available. For more information please email orthoassociate2016@gmail.com.

Orthodontist required to join our specialist orthodontic practice in Dublin 4. Superb facilities include iTero. www.ortho.ie – contact hughbradley@gmail.com.

Specialist orthodontist needed for general and orthodontics practice in south east. Full-time, part-time and locum options available. Award-winning, state-of-the-art practice with OPG/Ceph, Dolphin Software, four ortho chairs and fully trained ortho team. Email orthojobireland@gmail.com.

Endodontist required for busy private city centre practice in Dublin. One session per week (flexible). Internal referrals from four dentists. Global G3 microscope on site. Please forward CV with cover letter for attention of Danny to hello@docklandsdental.ie.

Golden opportunity for endodontist to join our practice in large town near Dublin. Nearest endodontist 30 minutes so great scope to build referrals. Terms and conditions negotiable, rental contract considered. Visit our website – wq dental.com – to see more. Email wq dental@gmail.com.

Periodontist/implantologist wanted part-time, two days weekly, for modern, four-surgery practice in Ratoath, Co. Meath (30 minutes from Dublin city centre). Fully computerised, great staff team. To replace excellent periodontist relocating after five years. Start June/July. References and CV essential. Email ratoathdental@gmail.com.

Hygienist needed to take over from departing colleague. Tuesday and/or Wednesday afternoon sessions. Please email CVs to helen@ballybrackdental.ie.

Hygienist position one to two days. Days flexible. To replace departing colleague. Busy book. Email CVs to blissingtondental@eircom.net.

Part time hygienist required to work in an expanding, modern practice in Dundalk. Our website – www.frielandmcgahon.ie – will give you an insight into our practice and team. If you are interested, email your CV to frielandmcgahon@gmail.com.

Part-time dental hygienist required for busy dental clinic in Blackrock. Competitive rates of pay and scope for increasing experience with both in-house and offsite training. Please contact victoria@seapointclinic.ie or call 01-284 2570.

Part-time hygienist required in Spiddal. Initially one day every two weeks.

Minimum contract of one year. Email lod@orthocosmetics.ie.

Northern Cross Dental is a newly expanded busy specialist practice and we are looking for a friendly, enthusiastic hygienist to join our team. Please forward CVs to mags@ncdental.ie.

Hygienist required to replace departing colleague in Bray, Co. Wicklow. Two days per week. Please email CV to hygienistrequired55@gmail.com. Start date in April.

Hygienist required for Dublin city practice – part-time: early mornings and late evenings. Team player with excellent clinical and patient management skills. Email marycreddy@gmail.com.

Part-time hygienist required to join our contemporary practice in Nenagh, Co. Tipperary. Must be a team player with excellent clinical and patient management skills. Please email CV to contact@nenagh dental.ie.

Dental hygienist required for two days per week (Thursdays and Fridays) for our dental practice in Bagenalstown, Co. Carlow. Email info@bernardmurphydental surgeons.ie.

Dental nurse required, part-time initially, for Dublin practice. Please forward CV and cover letter to dentalpracticedublin@gmail.com.

Part-time dental nurse required to work in a busy, modern practice in Dundalk. Our website – www.frielandmcfahon.ie – will give you an insight into our practice and team. If you are interested, email your CV to frielandmcfahon@gmail.com.

Experienced dental nurse required for D2 general practice. Friendly, enthusiastic team player, chair side and reception days. Computer knowledge and excellent communication skills required. Email dentaljobs2015@gmail.com.

Full-time dental nurse positions available in Kilkenny in multi-specialty practice. Qualification, good organisational and computer skills required. Please email CV to 1014mck@gmail.com.

Full-time nurse required for busy Dublin southside practice. Must be energetic, have good computer skills and be prepared to work as a team member. Please send CV to drgarrymcfahon@gmail.com.

Dental Care Ireland would like to recruit an experienced dental nurse to work in our specialist practice in Dublin 4. Experience working in specialist practice and knowledge of Exact advantageous. Please send your CV to marguerite.burke@dentalcareireland.ie.

Dental nurse required full-time to work in a modern, state-of-the-art clinic in south Dublin. Experience not essential; trainee nurses welcome to apply. Please forward your CV to careers@deansgrangedental.ie.

Northern Cross Dental is a newly expanded busy specialist practice and we are looking for a friendly, enthusiastic dental nurse to join our team. Please forward CVs to mags@ncdental.ie.

Dental nurse required part-time for a busy modern practice in Carlow Town. Experience not essential, but preferable. Email montgomeryhouse dc@gmail.com.

Dental nurse wanted for immediate start. Fully computerised paperless practice in a large multinational company in Cork. The ideal candidate should have excellent organisational skills, computer skills, and be able to integrate into and work within a large team. Email billy_waters@apple.com.

Busy dental practice in south County Dublin requires enthusiastic and friendly dental nurses – full-time and part-time. Ideal candidates will be qualified, experience not essential; good chairside manner, excellent communication skills. Please email cover letter and CV to ddentaldublin@gmail.com.

Experienced dental nurse required to join our busy city centre practice. Part-time position available – must be friendly, enthusiastic team player. Forward CV to diamondsml dental@gmail.com.

Experienced dental nurse required for specialist dental clinic in Limerick City. Please send CV and cover letter to dentalnurserecruit@gmail.com.

Full-time, qualified dental nurse required for busy south side practice. Please forward CV to alex@beechwooddental.ie.

Part-time dental nurse required for new orthodontic practice in Bray, Co. Wicklow. Thursdays and Fridays 9.00am-5.00pm. Orthodontic experience and radiology preferred but not essential. May lead to full-time position. Email davidhone@hotmail.com.

Experienced, full-time nurse required, minimum one to two years' experience. Email behan36@hotmail.com.

Dental nurses required in a multidisciplinary specialist practice in Dublin 4. Experienced nurse required for full-time hours over four days. Salary negotiable DOE. Part-time trainee nurse required. Support for further education is available. Salary DOE. Flexible hours. Email info@nidm.ie.

Part-time/full-time dental nurse required to join our busy, contemporary practice in Nenagh, Co. Tipperary. Must be friendly, enthusiastic team player with great communication skills. Please forward CV to contact@nenagh dental.ie.

Busy Dublin 24 practice needs a full-time experienced practice manager/receptionist. An applicant must have good people skills; clinical experience would be helpful but not necessary. Please forward a current CV to sheena.mceniff@gmail.com.

Dublin 4 specialist practice seeking reception maternity cover for May to October, inclusive. Full training, working alongside other reception staff. CV to dublincitydentistry@gmail.com.

Full-time receptionist required for a fully computerised practice in Kildare. Must be proficient in computers, telephone skills, social media marketing and dictaphone typing skills. Must also have good people skills and be a team player. Email behan36@hotmail.com.

PRACTICES FOR SALE/TO LET

Practice with premises for sale Dublin 9. Long-established, busy, single-handed, three fully-equipped ground floor modern surgeries, OPC, office, waiting room. Good location, potential for expansion. Dentist retiring. No medical card. Overhead accommodation. Email northdublinpractice@gmail.com.

For sale – south east Leinster. Busy single-handed surgery with easy commute to Dublin. Ample room for expansion – well equipped. Excellent staff. Flexible options, rent/freehold. High profits. Favourably priced. Very large potential for growth. Email niall@innovatedental.com.

Established medical aesthetic/dental clinic for sale – €475,000 – Dublin 2. Five surgeries: two doctors/two dentists/two support staff. Lease (12 years fixed). Superb terms/rent/excellent location and parking. Fantastic opportunity for clinician and/or potential lifestyle business owner. Enquiries to premiummedicaldentalsale@gmail.com.

For sale – D2 south Dublin. Busy, high-profile location with excellent footfall. Good equipment. Room for expansion – medium/long-term. Great potential. Low overheads. No medical card. Excellent profits. Very competitively priced – dentist retiring. Contact: niall@innovatedental.com.

Dental practice for sale, Dublin 13. Long-established, very busy, single-handed. Freehold house. Waiting room. Great location and potential. Dentist retiring. Email: fionnualaoh@yahoo.com

A passionate advocate

Dr Mairéad Browne is a GDP in Cork City, and current President of the Munster Branch.

What led you to first get involved in the IDA?

I joined the year after I qualified. I was completing vocational training in Ireland and membership was complimentary for the first year after graduating. Initially, I only attended a handful of lectures and meetings. As a newly qualified graduate, the biggest barrier I found to attending lectures and meetings was that feeling that I didn't really know anyone. However, the Munster Branch evening lectures are great because there's a big emphasis on the social aspect, so I could keep up to date with CPD and catch up with friends as well.

What form did that involvement take and how did it develop?

I started attending more lectures and meetings, and got to know everybody at the Branch. Then Dr Maire Brennan, who was President at the time, nominated me for the Branch Committee. This year I was nominated to be Munster Branch President and Munster Representative on Council of the IDA. It's a lot of work: chairing meetings and organising the evening lectures, as well as our Annual Scientific Meeting. It's quite time consuming but I had a very experienced, supportive and hardworking committee behind me and I found it very rewarding. I had no idea of the time and effort that goes into organising any event, so my tenure as President has given me a much greater appreciation for anybody who does get involved and the workload they commit to.

What has your involvement in the IDA meant to you?

Overall as an experience it's been very rewarding personally and professionally, and I feel that I'm a much more confident practitioner and a better dentist. I've learned how to delegate and how to organise. My confidence has improved and it's spilled over into my practice, helping me to balance working among several different practices, with different teams.

What has been the single biggest benefit of IDA membership for you?

The biggest benefit for me has been support, both professionally and personally. Being in practice is very isolating, but I found that going to the lectures is a great way to learn, and to meet with your peers – to ask questions, raise issues, gain support and realise that you're not on your own.

How would you like to see the Association progress into the future?

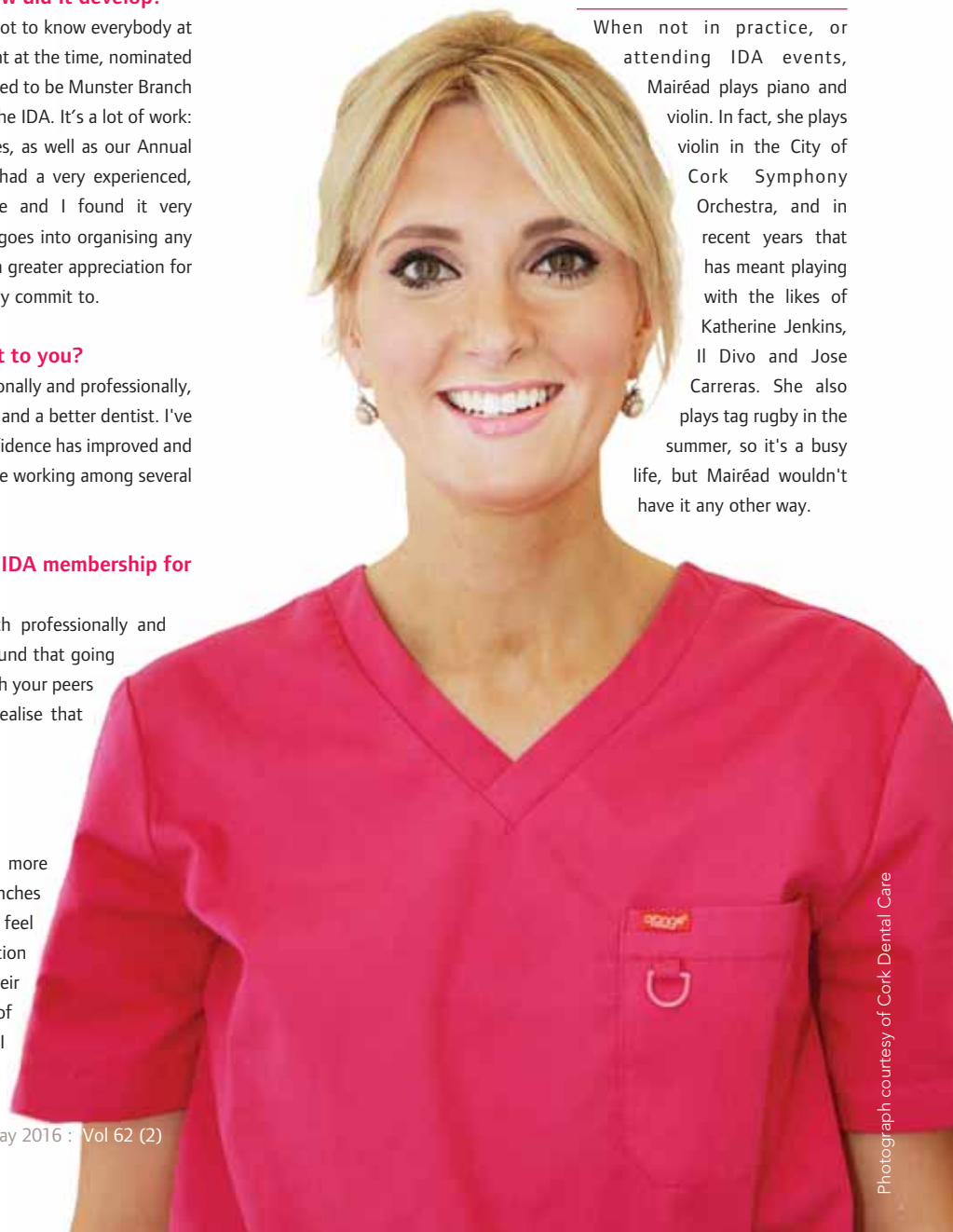I think as an association we have to encourage more members to get involved at committee level in branches and really encourage branches to be more active. I feel passionately that every single member of the Association should serve on a committee over the course of their membership. Our profession is going through a lot of changes and it's really important that we're unified. I tell friends of mine – people who are coming back

from the UK – to join the Association. There's no point sitting on the fringes complaining if you have a grievance or an issue – that's what the Association is there for. It's our Association and we're the members so you have to get involved.

Even if you can't commit to committee membership, come to the branch meetings and lectures. The organisation advocates on behalf of its members so it's so important that from the ground level up we're active.

Every individual member has a responsibility to get involved and to use the IDA to its full potential.

When not in practice, or attending IDA events, Mairéad plays piano and violin. In fact, she plays violin in the City of Cork Symphony Orchestra, and in recent years that has meant playing with the likes of Katherine Jenkins, Il Divo and Jose Carreras. She also plays tag rugby in the summer, so it's a busy life, but Mairéad wouldn't have it any other way.



DENTAL PROTECTION YOUR PROFESSIONAL PARTNER

Supporting you throughout your career



Advice through the
largest worldwide team of
dentolegal experts



Protection from
the costs of clinical
negligence claims



Support with CPD through
events, workshops
and publications

Peace of mind when you need it most

DENTAL PROTECTION MORE THAN DEFENCE

For membership information call **1800 509 441**

www.dentalprotection.org

New Sensodyne® Repair & Protect

– now with stronger repair![†]

Advanced technology for your patients with dentine hypersensitivity

What's new about Sensodyne® Repair & Protect?

The immediate availability of sodium fluoride when brushing allows for **greater fluoride uptake into the hydroxyapatite-like layer formed by NovaMin®¹**, repairing[†] your patients' dentine, to provide clinically proven sensitivity relief.*

This improved availability results in an **even harder reparative[†] layer over and within exposed dentine tubules,²⁻⁶** helping to protect against the future pain of dentine hypersensitivity.



Recommend new Sensodyne® Repair & Protect for specialist expertise in dentine hypersensitivity care

[†] Vs. previous formulation. Forms a protective layer over the sensitive areas of the teeth. Brush twice a day for lasting sensitivity protection.
* with twice daily brushing

References: **1.** GSK Data on File, 142234. **2.** Greenspan DC et al. J Clin Dent 2010; 21: 61-65. **3.** La Torre G and Greenspan DC. J Clin Dent 2010; 21(3): 72-76. **4.** Earl JS et al. J Clin Dent 2011; 22(3): 62-67. **5.** Parkinson et al. J Clin Dent 2011; 22(3) 74-81. **6.** GSK Data on File, ML498. **7.** GSK Data on File, ML584. **8.** GSK Data on File, ML589.

Trade marks are owned by or licensed to the GSK group of companies.