


Volume 60 Number 6
December 2014/January 2015


IDA
irish dental association

Journal of the Irish Dental Association

Iris Cumainn Déadach na hÉireann



Sweet tooth

Does the dentist have a role in identifying patients with undiagnosed diabetes mellitus?



SENSODYNE SENSITIVE DENTIST OF THE YEAR AWARDS 2014



The Sensodyne Sensitive Dentist of the Year 2014 is Dr James Turner who was nominated by his patient Mary Hallis for detecting her throat cancer. She said: "I just wouldn't be here without him".

IDA PRESIDENT **Dr Peter Gannon**
 IDA CHIEF EXECUTIVE **Fintan Hourihan**

JOURNAL CO-ORDINATOR **Fionnuala O'Brien**

EDITOR
Professor Leo F.A. Stassen
 FRCS(Ed), FDSRCS, MA, FTCD, FFSEM(UK) FFDRC SI

DEPUTY EDITOR
Dr Dermot Canavan
 BDentSc, MGDS(Edin), MS(UCalif)

EDITORIAL BOARD
Dr Iseult Bouarroudj BDS NUI
Dr Michael Crowe BSc BDentSc DPDS (Bristol)
Tina Gorman RDN, FAETC, Cert Conscious Sed.

Dr Mark Kelly BA BDentSc
Dr Christopher D. Lynch BDS PhD MFDRC SI
 FDS (RestDent)RCSI FACD FHEA

Donna Paton RDH
Dr Ioannis Polyzois
 DMD, PhD, MDentCh, MMedSc

Dr Ciara Scott
 BDS MFD MDentCh MOrth FFD (RCSI)

Dr Seamus Sharkey BDS NUI FRACDS (Syd)
 MFDSRCS DChDent (Prosthodontics) FFDRC SI

Dr Simon Wolstencroft
 BDS FDSRCS MScD MOrth FDSOrth

Dr Alastair Woods BA BDentSc

The *Journal of the Irish Dental Association* is the official publication of the Irish Dental Association. The opinions expressed in the Journal are, however, those of the authors and cannot be construed as reflecting the Association's views. The editor reserves the right to edit all copy submitted to the Journal. Publication of an advertisement does not necessarily imply that the IDA agrees with or supports the claims therein.

For advice to authors, please see:
www.dentist.ie/resources/jida/authors.jsp

Published on behalf of the IDA by
 Think Media, 537 NCR, Dublin 1

T: 01-856 1166
www.thinkmedia.ie

EDITORIAL
Ann-Marie Hardiman, Paul O'Grady

DESIGN AND LAYOUT
Tony Byrne, Tom Cullen, Ruth O'Sullivan

ADVERTISING
Paul O'Grady

DID YOU KNOW? The IDA has just launched a mentoring programme for dentists

265 EDITORIAL
 A public scandal

267 PRESIDENT'S NEWS
 Change must come

268 LETTERS TO THE EDITOR

269 NEWS

274 QUIZ

275 NEWS FEATURE
 IDA launches mentoring programme

276 BUSINESS NEWS

281 SENSITIVE DENTIST OF THE YEAR AWARDS
 A report from the first ever gala awards ceremony

285 IDA MEMBERS' NEWS **MEMBERS ONLY**

290 CLINICAL FEATURE
 Extraction of a maxillary molar tooth
 N Rahman

293 PEER-REVIEWED
 Oral carcinoma of the anterior hard palate: an unusual presentation
 L Walshe, O Omar, D MacCarthy, LFA Stassen

298 Does the dentist have a role in identifying patients with undiagnosed diabetes mellitus?
 A Sultan, A Warreth, P Fleming, D MacCarthy

304 ABSTRACTS

306 PRACTICE MANAGEMENT
 I didn't expect that!

307 CLASSIFIED

310 DIARY OF EVENTS



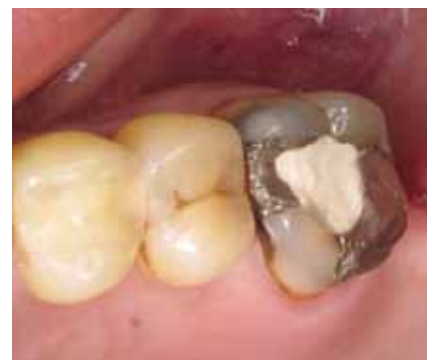Sensitive dentists 281

The Sensodyne Sensitive Dentist of the Year Awards



Practice management 206

A case of miscommunication



Clinical 290

Extraction of a maxillary molar

Irish Dental Association Unit 2 Leopardstown Office Park, Sandyford, Dublin 18.
 Tel: +353 1 295 0072 Fax: +353 1 295 0092 www.dentist.ie
 Follow us on Facebook (Irish Dental Association) and Twitter (IrishDentists).



Total average net circulation 01/01/13 to 31/12/13:
3,499 copies per issue. Circulated to all registered dentists in the Republic of Ireland and Northern Ireland.

Colgate®

INTRODUCING A BREAKTHROUGH IN EVERYDAY CAVITY PROTECTION

PROVEN BY 8 YEARS OF CLINICAL RESEARCH
INVOLVING 14,000 PEOPLE



**Sugar Acid
Neutraliser™
Technology**
powered by Arginine
+
Fluoride

Fluoride

Unique mode of action to
complement the power
of fluoride

- 4 x greater remineralisation¹
- Directly fights sugar acids
in plaque – the #1 cause
of cavities^{2,3}
- Up to 20% fewer new
cavities in 2 years^{4,5}



**Maximum
Cavity Protection**
plus **Sugar Acid Neutraliser™**

*versus a regular fluoride toothpaste with 1450 ppm fluoride.

References

1. Cantore R et al. *J Clin Dent.* 2013;24 (Spec Iss A):A42-A44. 2. Wolff M et al. *J Clin Dent.* 2013; 24 (Spec Iss A):A45-A54. 3. Santarpià P, Lavender S, Gittins E et al. Submitted for publication in *Am J Dent.* 2013. 4. Kraivaphan P et al. *Caries Res* 2013;47:582-590. 5. Hu DY et al. Data on file. Colgate-Palmolive Company, 2013.

COLGATE. COMMITTED TO A CAVITY-FREE FUTURE

www.colgateprofessional.co.uk

A public scandal

Professor Leo Stassen contrasts the recommendations of the first report of the National Oral Health Forum with the publication of the HSE budget for 2015.

The recommendations of the first report of the National Oral Health Forum are outlined in the members' section of this *Journal*. They are clear, sensible, progressive and in the public interest. Recommendations include: decisions to be based on clinical needs; the restoration of foundation training in dentistry; intelligent use of patient co-payment; and, the development of the optimal skill mix in dental practices. These are important, worthwhile and practical recommendations. The recommendations also address oral healthcare policy in Ireland in several ways:

- primary dental care should mirror the Primary Health Care Strategy;
- primary care services should link into appropriate secondary care services;
- continuity of care should be ensured;
- securing and maintaining oral health early in life is an urgent concern; and,
- priority should be given to the development of a strong primary prevention policy, and service entitlement for children, special needs and vulnerable groups.

These aren't just broad aspirations dreamed up by someone in the dental profession; they are the recommendations of the most important stakeholders in dentistry and oral health. The report is entitled 'A vision for improved oral health in Ireland' and is promoted primarily by the Association, the Dublin and Cork dental schools, and the Faculty of Dentistry at the RCSI.

Public scandal

Depressingly, we also read in this edition from both the President, Dr Peter Gannon, in his message, and in the news pages from the Chief Executive, Fintan Hourihan, of the announcement of the HSE's service plan for 2015. In essence, bar a €1 million allocation for orthodontics (which in itself is wholly inadequate), there is no increase in allocation for the provision of public dental health services.

The context of this announcement is a working public which has been paying PRSI but receiving nothing for it in oral health bar a dental health check once a year, and an unemployed/elderly/vulnerable population with medical cards, which has been on highly restricted oral care since the start of the recession.

Oral healthcare is no more or less important than any other form of healthcare. It will, when neglected as now, cause pain, distress and, in cases such as oral cancer, it will kill you.

It is being treated by the State as less important. This is a public

scandal and is already resulting in pain and illness. What is even more upsetting is that the Association met with the Minister, Dr Varadkar, in advance of the announcement, and impressed on him the importance of prevention as a public policy. What part of this message did Dr Varadkar not understand? It is willful neglect of our population and the State will pay a high price for the treatment of its citizens in the future – but not until those citizens have endured years of unnecessary pain and suffering.

Several years ago the term 'parity of esteem' was useful in articulating an important civil right in Irish politics. It appears the phrase may have to be reintroduced in relation to the healthcare of the population.

Good news

Elsewhere in the *Journal*, we have a multitude of great articles for you: scientific, clinical, practice management, abstracts, advice and news. One of the best news items is that dentists are being heralded by their patients and that was celebrated in style at the Royal Hospital Kilmainham on December 6 at the Sensodyne Sensitive Dentist of the Year Awards. Congratulations to every dentist that was nominated, but especially to Drs James Turner, Anna Zwolinksa, Vincent O'Connor and Aidan Higgins.

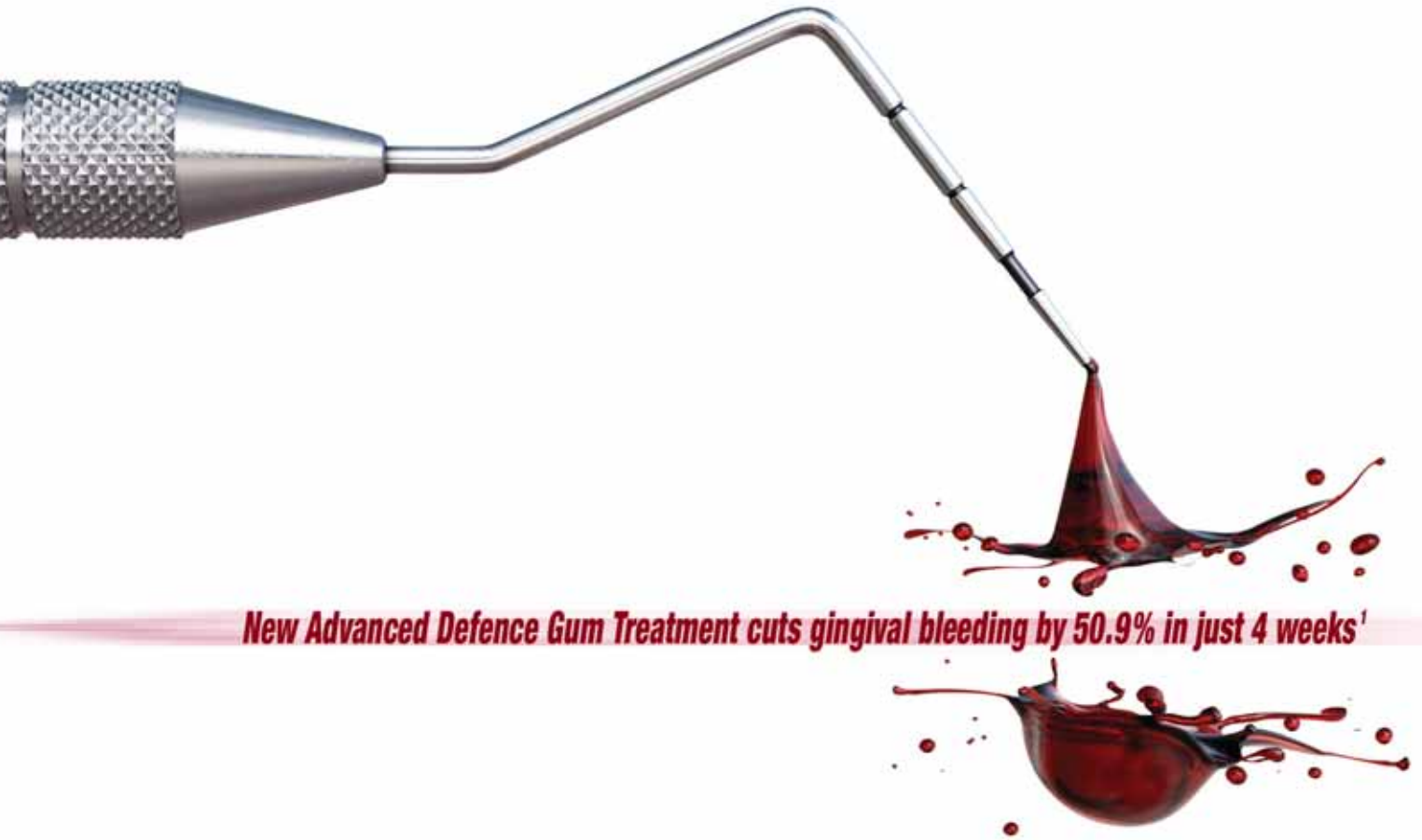
Next year

We have had a good year in the *Journal* and we hope that you did too. On behalf of the Editorial Board, I want to thank all our contributors and reviewers for their great work. We wish all our readers a happy Christmas and a peaceful and prosperous 2015.



Leo F. A. Stassen

Prof. Leo F. A. Stassen
Honorary Editor



New Advanced Defence Gum Treatment cuts gingival bleeding by 50.9% in just 4 weeks¹

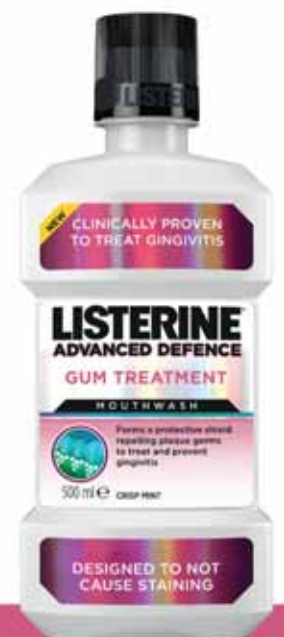Introducing the latest in the professional range from LISTERINE® – a twice-daily mouthwash **clinically proven to treat gum disease as an adjunct to mechanical cleaning.**

Advanced Defence Gum Treatment is an alternative to chlorhexidine-based remedies. It's formulated with unique LAE (Ethyl Lauroyl Arginate) technology that forms a physical coating on the pellicle to prevent bacteria attaching, and so interrupts biofilm formation.

When used after brushing it treats gum disease by reducing bleeding; 50.9% ($p < 0.001$) in only 4 weeks.¹

In addition, Advanced Defence Gum Treatment is **designed to not cause staining.**²

PART OF THE
LISTERINE®
ADVANCED DEFENCE RANGE



References:

1. Bleeding Index Reduction DOF 1 – 2013 (LAEBBA0001).
50.9% reduction in whole-mouth mean Bleeding Index at 4 weeks.
2. DOF 2 – 2013 (UNKPLT0006).

NEC/LI/13-0240b

Advanced Defence against gum disease

Change must come

PETER GANNON voices the Association's disappointment at recent HSE announcements on dentistry.

It was disappointing to read the HSE service plan for 2015 announced in November. An IDA delegation met recently with Dr Varadkar, Minister for Health. We impressed on him the benefits of prevention and regular dental visits. We called for the reintroduction of the DTSS treatments, as promised by Fine Gael, and suggested that the scale and polish, for a small increase in spending, would benefit a very large group of patients. We also outlined the difficulty that HSE dentists had in coping with the huge numbers eligible for treatment and suggested that a return to better staff numbers is vital.

Unfortunately, our words appear to have fallen on deaf ears. The only increase in dental spending is €1 million towards reducing HSE orthodontic waiting lists. This is very disappointing, but not surprising, orthodontics being a favourite topic of our TDs.

It does not seem that this Government, or the Department of Health, have any strong commitment to oral health or see that it is a part of a person's overall health. Our current DTSS contract is being ignored by the HSE when it suits them and the scheme is not providing adequate care for many eligible patients. The Public Dental Service is inadequately staffed and funded, and cannot meet its remit.

It is clear that change must come. As an association we need to explore the different options for dental services in the future: what the Public Dental Service and State dental schemes might provide in the way of treatment; which groups should be assisted; and, how this might be funded.

While other health professionals have become more dependent on State schemes in recent years, the opposite has become the case for dentists. We should, therefore, be able to look more critically, individually and as an organisation, at any future proposals for the provision of dental care. We need to make sure that we can maintain our high standards and continue to provide an excellent standard of care for all our patients, and that those with special needs or limited resources can rely on a dependable, easily accessible service.

Sensitive Dentist Awards

I would like to congratulate the many dentists who were nominated for these awards. It is always rewarding each year to read the patient testimonies highlighting the fine care and attention they have received. Media coverage of dentists often has a negative slant and it is important to hear the other side of the story. We know ourselves, and surveys confirm this, that our patients are very loyal and stay with us primarily because they trust us to provide the best and most appropriate treatment we can.

IDA mentoring scheme

The Irish Dental Association is setting up a mentoring scheme for members in all branches of the profession. Dentistry can sometimes be an isolated profession and often dentists are faced with problems

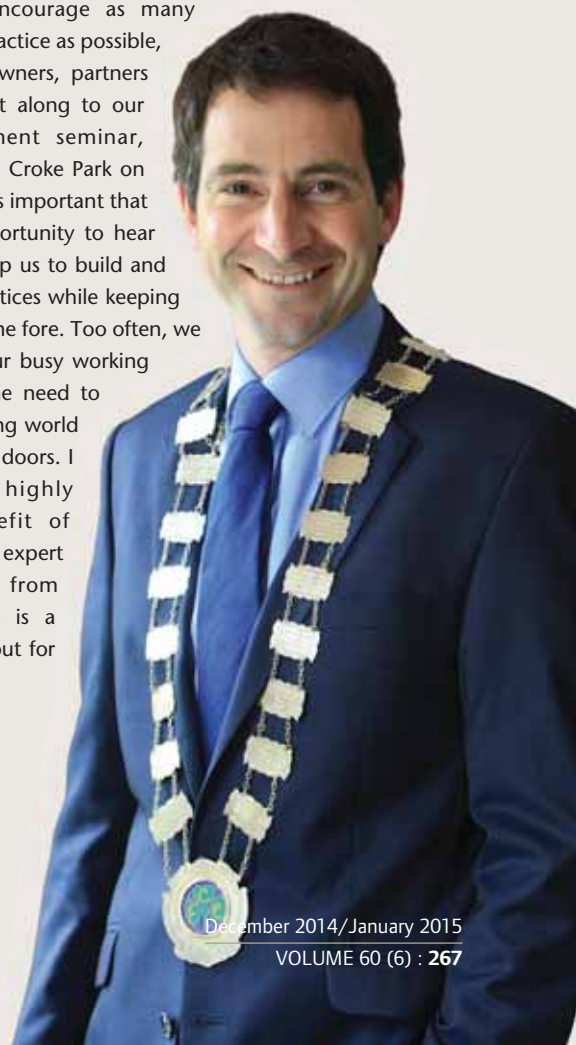that are not covered in their dental training. The goal of the proposed scheme will be to provide guidance and support to members, by putting them in touch with colleagues who will provide confidential guidance and support personally, or will direct them to an appropriate person who can provide the necessary advice. I would like to express my own thanks to the group of dentists who have volunteered to be mentors, and to give of their time and share their knowledge for the benefit of other dentists.

Oral Health Forum report

The Oral Health Forum brought together the key stakeholders working in the area of oral health in Ireland. The intention is to try to develop ideas and solutions for an oral healthcare system that is both good for the population and for those that work within it. It recently published its first report, which the IDA has circulated by email to members. We, as an organisation, need to remain involved and to make sure that our views are central to any future proposals.

IDA Practice Management Seminar

Finally, I would encourage as many dentists in private practice as possible, whether they are owners, partners or associates, to get along to our practice management seminar, which takes place in Croke Park on January 31. It really is important that we avail of the opportunity to hear experts who can help us to build and grow profitable practices while keeping patient interests to the fore. Too often, we get caught up in our busy working lives and neglect the need to consider the changing world outside our practice doors. I can't commend highly enough the benefit of learning from the expert speakers but also from colleagues in what is a really valuable day out for IDA members.



Dear Editor,

I would like to comment on two articles from the *Journal of the Irish Dental Association* of August/September 2014 (Volume 60 (4)). The first was 'Ethics and dentistry' (practice management) – an interview with Dr Eleanor O'Higgins, and the second was 'Handling a complaint after a patient has moved' (case study) by Dr Sue Boynton of Dental Protection (DPL). These are unrelated articles but they both deal with ethics and honesty in a broad sense.

In 'Ethics and dentistry' (pages 186-188), Dr O'Higgins is quoted as saying the dentist "could use ... superior knowledge to mislead or take advantage of a client [sic] by recommending unnecessary treatments". Further on in the interview she states that: "There is an understandable temptation for us all to be swayed by self-interest as exemplified by more profitable treatment modalities over equally effective, less expensive interventions".

I would regard these as very sweeping statements and would ask Dr O'Higgins to provide the scientific studies that support these claims either in Ireland or her native Canada.

In the second article ('Handling a complaint after a patient has moved'; case study, page 202), Dr Sue Boynton states that: "Two or more dentists may have a difference of clinical opinion, each being equally valid and justifiable". However, this would not seem to be the case as DP gave their support to Dr A on the basis that "there was no evidence that the patient required such extensive treatment" from Dr B.

One can only assume that DP gave their support to Dr A because his treatment modalities were more "evidence-based" but this implies that Dr B (in the terminology of Dr Higgins) was "recommending unnecessary treatment". If this is the case, why was there no mention of sanctions/reporting of Dr B to the relevant authorities?

It is laudable for DPL to support a hardworking dentist abiding by professional standards of care.

Is it not also necessary to report cases that are well outside the realm of valid and justifiable difference of clinical opinion?

Yours

Dr John F Hackett BDS MGDS RCSI

General Dental Practitioner, The Valley Dental Practice,
Section C, Unit 8 Cleaboy Business Park, Waterford City

Dear Sir,

It is important to reiterate the context in which my observations were made in my interview with the *Journal*. They related to the special responsibility of all professional service providers – financial, legal, health, etc. – who have superior knowledge to their clients/patients. This can apply to a range of professions. Potentially, this superior knowledge could make the client/patient particularly vulnerable as service providers could be in a position to take undue advantage. Possible overtreatment in dentistry, arising from the unequal relationship between practitioner and patient, was given by me as a valid example.

As for "scientific studies" to support my comments, the very nature of professional misconduct can be clandestine and the victim may be

unaware that misconduct has occurred. Thus, this issue is not really open to scientific study. Of course, a central point of the interview was to emphasise how professional integrity is a strong protection against the kind of misconduct instanced.

I should add that when preparing for my interview with the *Journal*, I had discussions on aspects of professional ethics with a number of dentists.

Eleanor O'Higgins

Dear Editor,

Thank you for forwarding on to Dental Protection the letter regarding the case study 'Handling a complaint after a patient has moved'. A case study such as this is useful because it can often generate discussion as it reflects a type of situation that can arise in everyday practice.

Colleagues will be well aware that individual clinical opinions are formed within a spectrum of evidenced fact and personal experience. They may not be identical in all respects and the skill sometimes lies in weighing them up and coming to a consensus.

A classic example is the old amalgam, which has been in place for a number of years. Some clinicians will adopt a careful monitoring approach, whereas others prefer early intervention. Similarly, some clinicians prefer to provide crowns to heavily restored teeth at an earlier stage than others.

In this particular scenario, Dr B appeared to have been of the genuine clinical opinion that his treatment was necessary. Dr A had a greater weight of evidence to support his clinical opinion. The decision on how to proceed was entirely a choice for the patient who, in this particular case, found Dr A's explanation and openness, in showing her the serial radiographs, to be persuasive. As is so often the case, the transparent nature of the communication helped the patient to develop trust in the clinician.

With kind regards,

Yours sincerely

Sue Boynton, Senior Dento-Legal Adviser, Dental Protection

Re: O'Higgins, E. Ethics and dentistry. *JIDA* 2014: 60 (4): 186

Dear Sir,

Congratulations on choosing such a splendid, informative, authoritative article. You should be very proud to encourage your protégés to read it. For a youngster to carry such intellectual awareness in the head would/must greatly ease the pressures of practising and learning, and being examined and tested.

It might be useful to get the authors to speak to undergraduates – say, annually?

Good choice and many thanks for making me think – again!

Best wishes

Aidan O'Reilly BDS FFD

Mews No. 12, Waterloo Lane, Ballsbridge, Dublin 4

Association CEO addresses European group



IDA CEO Fintan Hourihan addressed the CED in Brussels recently.

IDA Chief Executive Fintan Hourihan was asked to address the recent Council of European Dentists (CED) meeting in Brussels. He addressed the issue of advocacy, and how best professional associations can make their voices heard to influence policy and legislation in Europe.

RCSI ASM



From left: Dr Brian Schmidt; Dean of the Faculty of Dentistry, RCSI, Dr John Walsh; Mr David Vaughan; and, Dr Kumara Ekanayake.

The Faculty of Dentistry at the Royal College of Surgeons in Ireland held another very successful Annual Scientific Meeting on October 30 and 31. The theme of 'Current Controversies in Dental Practice' was ably covered in presentations on caries and fluoride, among other topics. The Edward Leo Sheridan lecture was delivered by Mr David Vaughan and Dr Brian Schmidt.

New HSE service plan = same old dental cutbacks

Dentists have denounced the HSE's service plan for 2015 as a devastating blow after it was confirmed that almost four million adult patients are now facing a sixth successive year of cuts to dental treatments worth €100m annually.

IDA Chief Executive Fintan Hourihan said dentists were shocked that there was no provision to increase funds towards the costs of dental care treatment for medical card holders in 2015. Commenting on the publication of the service plan, he said: "Since 2010, adults covered by the dental scheme for HSE medical card holders and those covered by the Department of Social Protection's PRSI dental scheme have seen ongoing annual cuts in State supports of over €100m each and every year. It is therefore incomprehensible that there is no additional funding for medical card patients in the first service plan for seven years to provide a net increase in spending".

"The result of this continued deterioration in assistance for patients has been characterised by a huge decline in patients attending for preventive care and treatment, which in turn has caused a massive rise in extractions (up over 33% since 2009), the greater provision of dentures and the rising incidence of tooth decay and gum disease."

"The €1m provided for orthodontic waiting lists is a paltry sum for a huge problem but the fact remains that those with unmet or diagnosed dental need represents a huge multiple of those requiring orthodontic care and treatment," Mr Hourihan concluded.

New book examines dental fraud

Having been awarded a PhD for his research, Dr Liam Lynch has published a book entitled *The Elephant in the Room*, which reviews the literature in regard to occupational fraud in dentistry. Emphasising that the majority of dentists do not perpetrate any type of dental fraud, abuse or scam, Dr Lynch says that measuring effectiveness in countering professional fraud by dentists in publicly funded oral healthcare has received little attention.

Dr Lynch says the primary aim of the book is to describe a new analytic instrument, which he has designed to facilitate oral healthcare systems to objectively assess the effectiveness of their counter-dental practitioner fraud strategy. It should also enable comparison to best practice, to other delivery systems and to previous assessments of the same delivery system.

This book examines an important topic and Dr Lynch is to be commended for his interest in a vital topic, which is studied rarely away from the white heat of controversy and banner headlines. All dentists agree that probity is important for sustaining confidence in the profession while needing to be administered in a fair manner, so publication of this research should be welcomed. Reflecting the stringent demands placed on doctoral research, this is a challenging read whose appeal will be strongest for readers with a pronounced interest in this topic.

Occupational Fraud in Publicly Funded Dentistry – The Elephant in the Room by Dr Liam Lynch PhD is published by Lightfort Publishing.

Schottlander Oral Prize goes to Irish dentist



From left: Dr Gerry McKenna; Dr Brian Schottlander; and, Dr Brendan Scott.

Dr Gerry McKenna was this year’s winner of the prestigious British Society of Prosthodontics Schottlander Oral Prize. The presentation of prize and certificate took place at a dinner held at the Royal Society of Medicine in London. Gerry’s paper was entitled 'Tooth replacement for partially dentate older patients: a cost effectiveness analysis' and carefully analysed the cost effectiveness of the RPD and SDA concepts, and their application in the treatment of older patients. His co-authors were Professor Finbarr Allen, Dr Noel Woods and Dr Michael Cronin from University College Cork. In making the presentation Brian Schottlander said: “Dr McKenna has come up with a clear conclusion from his work and it is good to learn that the evidence from it will be influential in making decisions about the preferred treatment options for this age group”.

Gerry is a newly appointed Senior Clinical Lecturer and Honorary Consultant in Restorative Dentistry at the Centre for Dentistry, Queens University Belfast.

Confidential support for dentists in need



Over the last few years the dental profession has been hit severely by a combination of recession and severe cutbacks in the State payment schemes. Even the most careful of colleagues can, with a combination of financial issues and perhaps unforeseen illness or death, end up in dire financial trouble. The Irish Dental Benevolent Society, which is a registered charity, was set up in 1949 with the aim of raising funds to help dentists or their dependants. Our role is to assist colleagues and their families who may be experiencing difficulties. We operate independently and with the strictest of confidentiality.

We urgently require funds and are appealing for financial help from any dentists who can contribute in any way. The most effective method is to set up a regular standing order, or to make a yearly contribution. Donations of €250 and above to charities allow a tax refund to be claimed, which is an enormous boost to the Society’s fund. Bequests and larger donations are of course very welcome.

How the Benevolent Society can help:

- supplementing income;
- protecting the family home;
- helping to educate dependents;
- helping to meet health costs;
- helping with insurance premia; and,
- helping with once-off expenses.

How you can help:

- subscribe to the Society by means of a standing order;
- donate online at www.idbs.ie;
- support the Irish Dental Benevolent Society events;
- tell your colleagues about the Society, both to support us and in case our assistance should ever be required; or,
- raise some money at your class reunions.

How to contact us

All correspondence relating to new applications, donations and grantees may be sent to the Treasurer: Dr Mark Kelly, c/o Irish Dental Benevolent Society, Shelbourne Dental Clinic, Office 7, Grand Canal Wharf, South Dock Road, Dublin 4, or Email: info@idbs.ie.

Dr Stephen Hancocks OBE awarded FDI’s highest honour



Stephen Hancocks has been recognised by the FDI for his services to the organisation. For the last 14 years Stephen has been the editor of the *International Dental Journal* and at times single-handedly kept the publication alive and relevant to all member associations. The FDI General

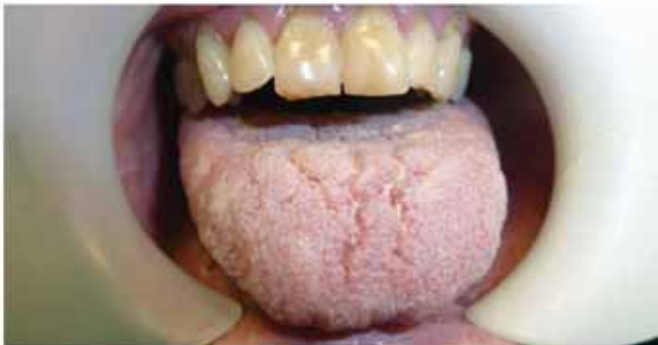Assembly has awarded him Member of the List of Honour for his unique contributions throughout his time at the FDI. On hearing of this award, Stephen commented: “The clue to my feelings on receiving this is contained in the title of the award itself because I am deeply honoured to have been recognised in this way.” The award will be presented to Stephen during the Opening Ceremony of the Annual World Dental Conference in Bangkok next September.

Hyposalivation and xerostomia

Catherine Waldron, RDH MSc MA (Health Promotion), PhD student (Special Care Dentistry),
Dublin Dental University Hospital, Lincoln Place, Dublin 2.

The term hyposalivation is used to describe the objective assessment of a below normal salivary flow, whilst the term xerostomia is used for the more subjective complaint of a dry mouth. The two do not always go hand in hand. Many patients with hyposalivation may not be aware of it. Therefore, oral healthcare professionals have a responsibility to assess saliva flow as part of a patient examination as the consequence of hyposalivation can be devastating.

Typical appearance of a dry mouth



The prevalence of hyposalivation increases with age and is estimated to be >30% in those over 65 years of age. The main causes of hyposalivation are:

- medications, including antidepressants, sedatives and antihypertensives;
- oral diseases affecting the major and minor salivary glands;
- systemic diseases, most particularly Sjögren's syndrome; and,
- head and neck radiotherapy.

Medications

One of the most common side effects of taking medications is hyposalivation. An increasing number of the patients we see in practice on a daily basis are taking multiple medications. Some 50% of over 65 year olds have two or more chronic conditions, and the risk of experiencing a dry mouth increases the more medications a person is taking, rising from 20% when taking one medication to 70% when taking seven or more medications.¹

Oral diseases

The oral diseases causing dry mouth can be caused by infections, trauma and neoplasms. Chronic parotitis is an infectious condition normally caused by an obstruction of the salivary duct or gland. Signs and symptoms are swelling of the gland, pain and discharge. A mucocele is a common condition, which results from trauma to a minor salivary gland such as when a person bites their lip, and which normally heals uneventfully. A more serious condition occurs when calcification (stones, calculi) form in the submandibular gland or ducts and these stones may need to be surgically removed if they do not clear themselves. Any

blockage of the submandibular duct or gland would result in a noticeable drop in saliva flow. Most neoplastic tumours are benign, but the chance of one being malignant increases with age and they tend to occur in the submandibular and sublingual glands.¹

Sjögren's syndrome

This is the most common of the systemic diseases affecting saliva flow. It is an autoimmune disease occurring mostly in woman in their 40s and 50s. Typically, in the primary form, the symptoms of dry eyes and/or dry mouth occur, resulting from a gradual loss of function of the lacrimal and salivary glands. The secondary form additionally includes a connective tissue disease such as rheumatoid arthritis or lupus.²

Head and neck radiotherapy

As a consequence of receiving head and neck radiotherapy, the salivary glands can become damaged. This is due to the sensitivity of the acini or cell clusters in the salivary glands to the radiation. The damage caused is dose and time dependant, for example a patient receiving >25Gy is likely to have permanent damage to the salivary glands in the target area. Patients receiving <25Gy will experience considerable reduction in saliva flow (reduced by 60-90%) within the first week of treatment but have some chance of this flow rate slowly recovering after treatment is completed.¹

Treatment

Regardless of the cause of the hyposalivation, the treatment options are the same:

- on confirming a diagnosis, consult with the healthcare team regarding removal of any causes;
- advise the patient about the need for more regular dental visits due to the increased risk of dental caries and other oral infections;
- give detailed and tailored oral hygiene advice including the use of fluorides, antimicrobials and chewing sugar-free gum;
- counsel the patient regarding smoking cessation, dietary adjustments and hydration; and,
- advise the patient about oral moisturisers, stimulants and substitutes to ease the symptoms of dryness.^{3,4}

References:

1. Edgar, M., Dawes, C., O'Mullane, D. *Saliva and Oral Health: an essential overview for the health professional* (4th ed.). Stephen Hancocks Ltd, 2012.
2. Scully, C., Felix, D.H. Oral medicine – update for the dental practitioner. Dry mouth and disorders of salivation. *Br Dent J* 2005; 199 (7): 423-7 – <http://www.nature.com/bdj/journal/v199/n7/full/4812740a.html>.
3. Gupta, A., Epstein, J.B., Sroussi, H. Hyposalivation in elderly patients. *J Can Dent Assoc* 2006; 72 (9): 841-6.
4. UK Medicines Information. (2013). Saliva substitutes: Choosing and prescribing the right product. www.medicinesresources.nhs.uk/GetDocument.aspx?pageId=504026 (accessed 5th November 2014).

no more
compromises



The Tapered Internal family of dental implants provides excellent primary stability, maximum bone maintenance and soft tissue attachment for predictable results.

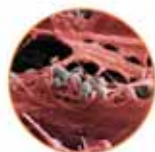restorative ease

45° conical internal hex connection creates a robust, biologic seal and is color-coded for quick identification and component matching



connective tissue attachment

Laser-Lok uniquely creates a physical connective tissue attachment and biologic seal



bone attachment

Laser-Lok® microchannels achieve superior osseointegration



universal surgical kit



For more information, contact
Telephone: +44 (0)1344 752560
Email: infouk@biohorizons.com
www.biohorizons.com

BIOHORIZONS
SCIENCE • INNOVATION • SERVICE

News

JOURNAL OF THE IRISH DENTAL ASSOCIATION

A fine welcome in Carlow for the HSE dentists



Pictured at the Past Presidents lunch at the recent HSE Dental Surgeons Annual Seminar were: Back row (from left): Dr Stephen Brightman; Dr Pdraig Halvey; Dr Jane Renehan; Dr Joe Greene; Dr Barney Murphy; Dr Iseult Bouarroudj; Dr Jim McCafferty; Dr Anne O'Neill; and Dr Rosarii McCafferty. Front row: Dr Cora McCarthy; Dr Maeve O'Connor; this year's President Dr Frances O'Callaghan; Dr Mia Delaney; and, Dr Margie Houlihan.

Members of the HSE Dental Surgeons Group of the IDA gathered in the Mount Wolseley Hotel in Carlow for this year's Annual Seminar. In a departure from previous years, this year's seminar consisted of two full days of lectures, and a packed hall of delegates heard an impressive group of speakers, who covered a wide range of topics relevant to dental professionals in the Public Dental Service. Dr Frances O'Callaghan took over as President of the Group at this year's seminar. Dr Eamon Croke, President of the Dental Council, began proceedings on Thursday morning with a presentation on the long-awaited Dental Act, which he described as 'the Department's Godot'.

Dr Breige McNulty from the UCD Institute of Food And Health presented the results of a large national nutrition study of pre-school children. Dr Nick Armstrong spoke next on 'Decontamination – who's responsible?' Dr Armstrong looked at the relevant standards with respect to decontamination in the dental surgery, in the context of decontamination standards for equipment, and also health and safety legislation, which takes in the dentist's responsibility as an employer. Dr Sheila Galvin gave a whistle stop tour of the many medical emergencies that can occur in a dental practice.

In the afternoon, Dr Eleanor McGovern gave a passionate presentation on her work with children who suffer from cleft lip and palate. Professor Denis O'Mullane gave a comprehensive presentation on the evidence for fluoridation.

Dr Dympna Daly gave a presentation on molar incisor hypomineralisation (MIH), including examination and treatment techniques, and a number of case studies.

The final speaker of the day was Professor Martin Kinirons, who took delegates through a range of dental trauma cases from the relatively minor to more serious trauma. On Friday morning, in a change to the programme, Dr Una Lally gave a presentation on composites, listing common problems, and discussing ideal materials for restoration.

Dr Lally was followed by Liz Murray, who gave an account of the Dental Council criteria for clinical audit in radiology – Round 2. She argued that clinical audit is an excellent opportunity to step back and look at your own work with new eyes and, if done correctly, will lead to improved levels of care. Dr Marielle Blake followed with a fascinating presentation on the assessment of children seen at second, fourth and sixth class – what to refer, and when to wait and see.

Dr Rob Cunney began the afternoon session with a fascinating look at the history of antibiotic use. Dr Cunney is a member of a group that is currently developing dental antibiotic guidelines, which will be incorporated into primary care web-based guidelines for use on mobile devices.

The final speaker of the conference was Dr Vicky Jones, who gave an entertaining and passionate presentation on oral health for patients suffering from dementia, multiple sclerosis and Parkinson's disease.

ASTRA TECH IMPLANT SYSTEM

Thank you.
We couldn't have
done it without you.



Clinically
documented
success
over three
decades

We asked how the
ASTRA TECH Implant System
could be improved.
We listened to what you
said you wanted.
We delivered much more.

Simplicity without compromise

The next step in the continuous evolution
of the ASTRA TECH Implant System

- Surgical flexibility
- Restorative ease
- Maintenance of marginal bone

Join the **EVolution!**
44 (0)845 450 0586

implants.uk@dentsply.com www.dentsplyimplants.co.uk
Education – www.courses4implants.com
Surgical partners and GDP restoration – www.dentists4implants.com
Practice growth support – www.goodbyegaps.com



Large Irish delegation attends iADH Congress in Berlin

Thirteen members of the Irish Society for Disability and Oral Health attended the biennial Congress of the International Association for Disability and Oral Health (iADH) in Berlin in October. Dr Alison Dougall and Prof. June Nunn from the Dublin Dental University Hospital presented an educational symposium, which outlined resources developed by the iADH to support education in special care dentistry. The Irish delegation also contributed 10 short oral and poster presentations outlining special care services provided, service development initiatives and research undertaken, the second largest contribution by any country to the event. Dr Emma Corrigan won an iADH award for her presentation of an initiative supporting a homeless population to access care under the Dental Treatment Services Scheme.



Above (from left): Drs Maura Haran; Grace Kelly; Alison Dougall; Emma Corrigan; Danielle McGeown; Siobhan Stapleton; and, Caoimhin MacGiolla Phadraig.

Above left: Dr Emma Corrigan, who won Best Presentation at the Congress.

Will you still be smiling at the end of the year?

Make sure your practice is profitable in 2014

As Ireland's only specialist dental accountants we're here to help you control your practice costs

QUARTERLY ACCOUNTS PAYROLL SERVICES

TAX CONSULTANCY COST OF TREATMENT

MedAccount SERVICES

Medaccount offer a full range of specialist dental accounting support and advisory services for Associates, Principals, Expense Sharing Partners and Consultants.

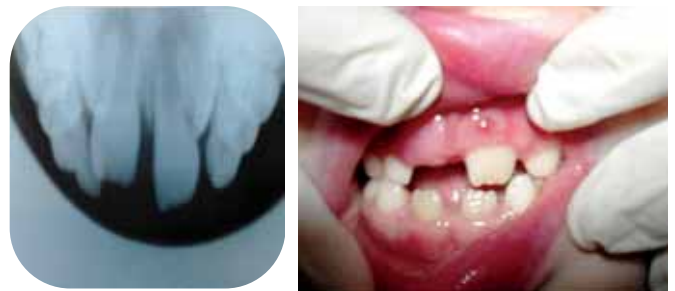FIRST CONSULTATION FREE

MedAccount Services
96 Lower Georges Street
Dun Laoghaire
Co Dublin
Tel: 01 280 6414
Email: info@medaccount.ie

First consultation free of charge, with no obligation to engage

Quiz

Submitted by Dr Iseult Bouarroudj.



A seven-year-old boy presents with an avulsed UL1. The EOT was 45 minutes (20 minutes dry and 25 minutes in milk). Initial management included replantation under LA and a flexible splint was placed for two weeks. Appropriate antibiotic therapy was prescribed and the patient's tetanus status confirmed. UL1 was partially erupted on avulsion with incomplete root development. The patient was reviewed three weeks post implantation and while UL1 was asymptomatic, an obvious sinus tract was present labially. Non-vitality was confirmed by sensibility testing and periapical pathology on radiographs.

Questions

1. What is the long-term prognosis of this tooth?
2. What are the most likely outcomes in this case?

Answers on page 305.

Professional mentoring

A special new mentoring service, for and from dentists, is now available to members through the Association.

Mentoring is "off line help by one person to another in making meaningful transitions in knowledge, behaviours, work or thinking." The mentor helps the mentee 'step outside the box' of his/her role and professional circumstances so that they can look at it together. It is like standing in front of a mirror with someone else, who can help you see things that have become too familiar for you to notice.

Clutterbuck and Megginson 1999

The Irish Dental Association has introduced a new service for members – professional mentoring. To mark the introduction of the service, a booklet has been produced to explain what is involved. A copy of the booklet is enclosed with this edition of the *Journal* for all members. The booklet has a question and answer style and here are some of the key excerpts.



The new booklet from the Association – it's enclosed if you are a member.

What is the purpose of the IDA Professional Mentoring Programme?

The Association approved the Professional Mentoring Programme, in response to a clearly identified membership desire, and need, following a comprehensive membership survey. Accordingly, the IDA Professional Mentoring Programme has been designed to be rolled out on a pilot basis over 2014/15 – subject to full evaluation, feedback and review.

The Programme's core purpose is to enable the provision/sharing of informal guidance, insight and wisdom by trained IDA volunteer mentors to participating mentee colleagues, over a range of professional practice areas.

Key to the Programme's success will be that the process is structured, safe and totally confidential. How this is achieved will be outlined and explained in detail in the Programme booklet.

The Programme will be entirely voluntary and within clear guidelines, with a focus on practical and helpful support. A careful matching process will be undertaken within the Programme to enable productive, useful and safe conversations. The design has been focused on best practice professional standards and the value of focused peer support.

What kinds of issues/areas and topics could be involved in mentoring conversations?

Whilst the priorities and content of the mentoring relationship will

be mentee led, it is anticipated that issues in one or more of the following subject areas could be addressed:

- setting up a new practice, or taking over an existing practice;
- practice management/development;
- regulations and compliance;
- record keeping/financial management;
- patient care – patient management;
- team dynamics;
- managing conflict/stress management;
- managing clinical problems;
- buying/selling a practice; and,
- career planning/professional development.

Mentoring discussions are not limited to the topics listed above; however, topics should be related to issues that affect the mentee's professional practice.

How does the Programme get started? How will mentees/mentors contract effectively and make progress?

The IDA 'Getting Started Guide and Checklist', which will be provided to mentor and mentee, provides guidance and a framework for the initial mentoring meeting and conversation.

A key requirement for clear, mutual contracting and agreeing both roles and expectations is that both the mentee and mentor discuss and sign up to the IDA Mentoring Agreement.

The Agreement covers and reiterates the core features:

- a short introduction to the overall IDA Mentoring Programme;
- mentor/mentee commitment: approach and roles;
- focus: objectives and outcomes for the mentoring partnership;
- mutual expectations and input;
- mentee: commitment – responsibility: active participation for full value;
- operations and convenient arrangements: duration of the mentoring partnership – meetings – scheduling;
- cancellation/rescheduling of meetings;
- records/review – evaluation; and,
- withdrawal from the mentoring partnership/request for change.

Mutually convenient arrangements are then agreed for contact, meetings or discussion.

It is hoped, anticipated and desired that the mentoring relationship is a cumulative experience, in which progress, momentum, trust and support builds over time.

Interested parties should contact Fintan Hourihan, Chief Executive of the Association, in the first instance.

DeCare Dental partners with brokers

DeCare Dental Insurance is now partnering with ARB, a leading wholesale insurance provider in Ireland, which represents over 350 brokers nationwide.

DeCare Dental CEO Maureen Walsh said: "Our key objective in the past year has been to increase access for both the consumer and corporate markets. This partnership with ARB helps to accelerate this strategy and will allow consumers all over Ireland to purchase or learn more about dental insurance through their broker. We've had a great response from the ARB broker community, who feel that our dental insurance proposition is an excellent fit for their customers". Commenting on the partnership, Paul Carty, Managing Director of ARB, said: "We see an excellent fit between DeCare Dental and ARB. DeCare Dental provides not only the widest range of products on the market, but also an exceptional level of service".

DeCare Dental's Healthy Smiles range of plans will be available through ARB brokers in four levels.



From left: Gavin Murphy, DeCare Dental Individual Sales and Retention Manager; Maureen Walsh, DeCare Dental CEO; and, Paul Carty, ARB Managing Director.

DMI acquires Dentaquip

DMI has announced that it has acquired Dentaquip Limited, a dental supply company based in Lisburn, Co. Antrim. Dentaquip is a long-established and well-respected dental dealer supplying a broad range of quality dental equipment, consumables and after sales



engineering services to dentists and dental laboratories throughout Northern Ireland. It has a team of 15 experienced and knowledgeable employees.

According to DMI, Dentaquip represents an excellent strategic fit with DMI, as both companies have similar agencies and focus on strong partnerships with customers and business partners. Based in Dublin, DMI has a total of 32 experienced and highly qualified personnel who provide a very similar service to Dentaquip.

Commenting on the announcement, Pat O'Brien, CEO of DMI said: "We are delighted to acquire such a reputable company. The acquisition of Dentaquip will expand the range of products and services available for Dentaquip's customers, provide more opportunities for employees and create additional value for dental professionals in Northern Ireland".

Over the coming months, DMI says it intends to rationalise some processes to ensure that customers obtain the benefits of scale associated with the companies coming together. However, in the meantime, it is business as usual for both companies in terms of how they interact with suppliers and customers.

John Fanning retires

Many of our readers will know John Fanning, who retired in December from Voco. When contacted by the *Journal*, John told us: "When I was invited by Voco to assist them in making the brand known in Ireland, I was delighted to accept the assignment as I had completed several start-up operations in Europe on behalf of US companies. I decided that I would give it six to 12 months and nearly nine years later I was still at Voco. I covered the whole of Ireland and when Amaris was launched in early 2007 this became my entry product into every clinic in Ireland. Today Voco is known and recognised in every part of Ireland. I will miss meeting so many nice people all over the country, especially those who always offered me a cup of tea on bad weather days knowing I had spent two or three hours driving to their location". Claire Austin has taken over as the Voco representative in Ireland.

Bifix Temp

Bifix Temp is a dual-curing, composite-based temporary luting material. According to its manufacturer,



Voco's Bifix Temp.

Voco, it combines highest aesthetics and simplest applicability and makes visually perfect results possible for temporary restorations. The translucent and tooth-like shade does not shine through and promotes the natural appearance of the temporary treatment. Thanks to film layers of below 5µm in thickness, temporaries can be luted to fit perfectly and without requiring time-consuming finishing work.



With Colgate MaxWhite One Professional, busy patients can enjoy visibly whiter teeth in just 3 days.¹ Also, they only need as little as 30 minutes a day for home treatment.

Order today from your dental wholesaler.

Results at the Speed of White

Visibly whiter teeth
in just 3 days

From **30** minutes per day

Colgate

**MAX
WHITE
ONE
PROFESSIONAL**



1. Mohan et al. J Dent 2008; 36:21-26.

Onsite Dental comes to Ireland



Onsite Dental has recently introduced its business model of a touring practice to Ireland. Local dentists are asked if they wish to staff the mobile surgery for events at big offices and office parks in their area. The hygienist, nurses and receptionists are provided by Onsite Dental. There was a demonstration day at Citywest in Dublin this autumn. Staffing the surgery on this occasion were (from left): Santina Lowe, event manager and dental nurse; Anne Marie Graham, RGN; Gemma Connolly, dental nurse; Dr Emma Clarke, dental surgeon; and, Caroline Quinlan, dental hygienist.

Identex iPad winner



Pauline Daly from Hazelwood Dental Surgery in Glanmire, Co. Cork recently received an iPad from Gerard Lavery, who presented it on behalf of the Irish Dental Trade Association. Pauline won the iPad in a prize draw at Identex 2014 held in partnership with the IDA at Citywest in September. Identex will take place on September 18 and 19, 2015, at Citywest Hotel.

Pioneers in implants



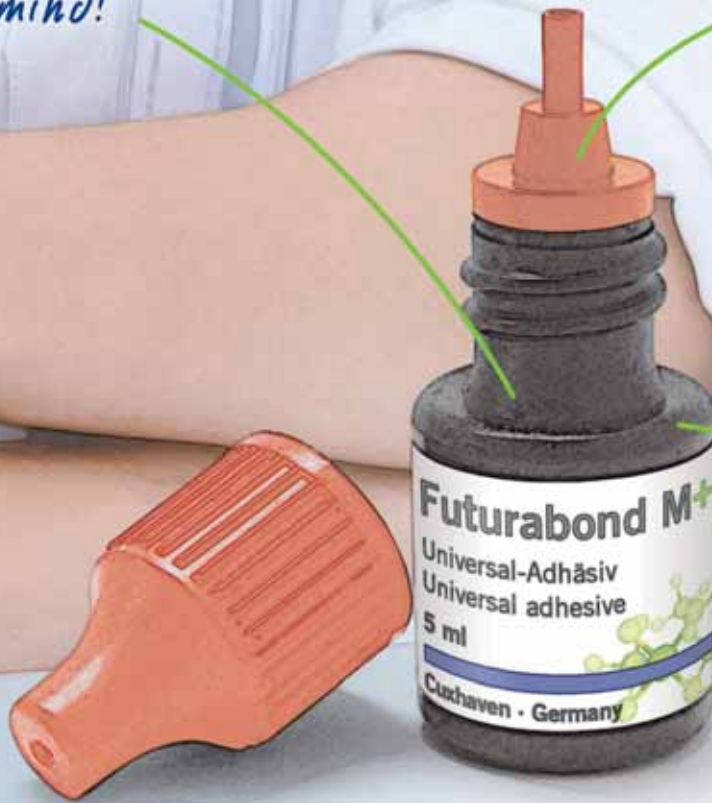A seminar to mark 30 years of implant dentistry in Ireland took place in Dublin in November. At the event, organised by Professor David Harris and attended by Professor Daniel van Steenberghe of the University of Leuven in Belgium, were several of the dentists and specialists that had been involved in the early adoption of implant technology and techniques in Ireland. Pictured were (from left): Professor David Harris; Dr Billy Davis; and, Professor Daniel van Steenberghe.

I am multi-talented!

Total-, Selective-,
Self-Etch:
I don't mind!

I can do so
much more than
conventional
adhesives!

My content is
sufficient for
more than
250 applications!



EVERY DROP IS PROFIT

A flexible and reliable solution for every bonding situation

- Can be applied with or without phosphoric acid etching
- Excellently suitable for direct or indirect restorations
- Secure adhesion to various materials such as metals, zirconium or aluminium oxide, as well as silicate ceramics, without additional primer
- Applied in one layer - only 35 seconds total working time

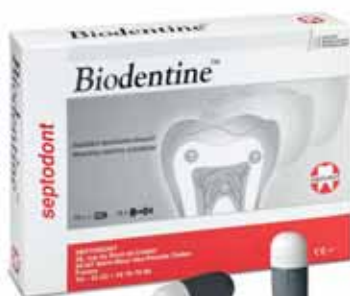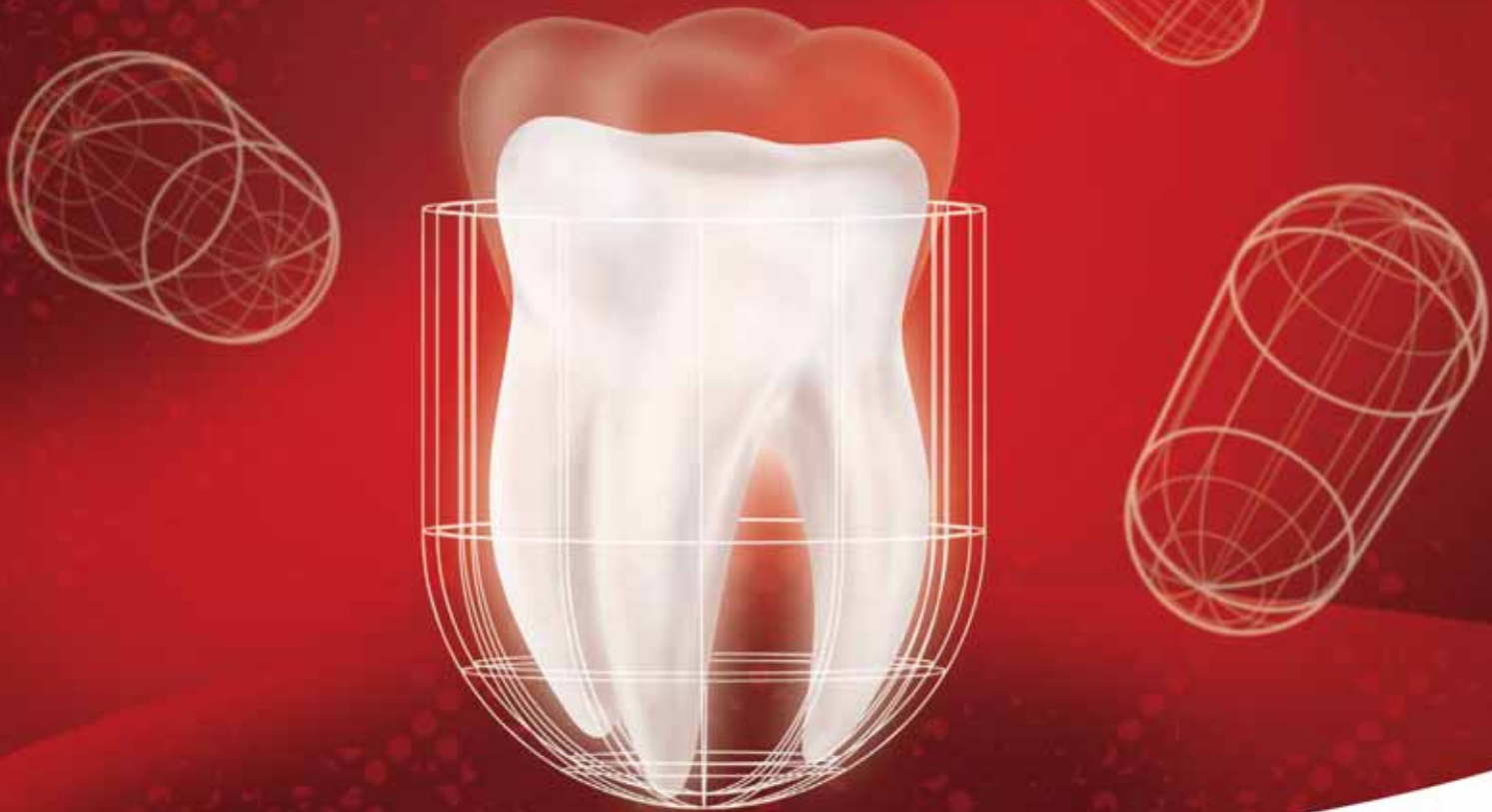Futurabond M+



For more information please contact:
Tel. 085 725 6078 or +44 758 420 0138 · info@voco.com

Biodentine™

The first and only dentine substitute in a capsule



ACTIVE
BIOSILICATE
TECHNOLOGY

As the first all-in-one biocompatible and bioactive dentine substitute, Biodentine™ fully replaces dentine wherever it is damaged.

Biodentine™ helps the remineralization of dentine, preserves the pulp vitality and promotes pulp healing. It replaces dentine with similar biological and mechanical properties.

Improving on Biodentine™ clinical implementations, you can now bond the composite onto Biodentine™ in the same visit and perform the full restoration in a single session.

To enjoy the clinical benefits of the first and only dentine substitute in a capsule, ask your dental distributor for Biodentine™.

www.septodont.ie

Tel: +44 (0)1622 695520

To arrange a demonstration contact Gerry Lavery on: +44 (0)7836255274

Anaesthetics • Endodontics • Restorative Dentistry • Dental Surgery • Prosthetic Dentistry • Disinfection & Hygiene



Sensitive dentists to the fore

A terrific night celebrating the very best of dental patient care was held at the Royal Hospital Kilmainham in Dublin in early December when the finalists and winners in this year's Sensodyne Sensitive Dentist of the Year Awards were announced.



Overall winner: Dr James Turner, Rathdrum, Co. Wicklow, detected a throat cancer in his patient, Mary Hallis.

Festive enjoyment met serious oral healthcare at the RHK in Dublin recently. This year, the judges had received another huge entry in the Sensodyne Sensitive Dentist of the Year Awards and had decided on the finalists and winners. Those decisions were announced to great acclaim in the magnificent surroundings of the Dining Hall in a ceremony expertly compered by TV3's Colette Fitzpatrick. Honorary Editor of the *Journal*, Professor Leo Stassen, said in his welcome notes: "Over the last six years, our judges have read the testimony of thousands of dental patients. This testimony is unique. As far as we know, no one has ever provided a channel or a forum for patients to say that they really appreciate the care they receive in our practices."

Eilís Tobin of sponsors, GSK, said: "When we started in 2008, none of us knew if this awards programme would work. But it has worked. It has provided us with wonderful stories about dentists and their patients. From superb clinical care to wonderful acts of human kindness, we have heard how dentists help their patients in a multitude of ways."

After dinner, each of the finalists in the four regions were called on stage to receive their certificates, and then the regional winner was announced (see all details of finalists and winners in the following pages). After all of the regional winners were announced, the Association President, Dr Peter Gannon was asked to open the envelope and announce the winner. Dr James Turner came forward to receive his trophy and be interviewed on stage by Colette about how he handled this particular case.

Dr Gannon concluded the ceremony saying: "Let me thank again – on all our behalves – the judges; the staff of the Association, especially Assistant Chief Executive, Elaine Hughes who has put so much work into this event; the Editorial Board and staff of the *Journal*; Eilís Tobin and her team in GSK; and Colette Fitzpatrick for making this a great event."

Afterwards, everyone enjoyed the evening, dancing to the band and socialising with colleagues and friends.

Sensodyne Sensitive Dentist of the Year

JOURNAL OF THE IRISH DENTAL ASSOCIATION

Finalists in Connacht/Ulster



From left: Dr James McGovern; Dr Aneta Spring; IDA President Dr Peter Gannon; Dr Vincent O'Connor; and Dr Stephen Campbell.

Dr Stephen Campbell, Sligo – nominated by Lucy Robus for helping her overcome her panic attacks.

Dr James McGovern, Galway – nominated by Gillian Egan for allaying of severe fear.



Winner: Dr Vincent O'Connor, Galway, for care of his patient, José Antonio, who has Down syndrome.

Dr Vincent O'Connor, Galway – nominated by Julia Antonia Byrne for care of her brother who has Down syndrome.

Dr Aneta Spring, Donegal – nominated by Caroline Morgan for management of dental phobia.

Dublin



IDA President Dr Peter Gannon with Dr Anna Zwolinska and Eilís Tobin of GSK.

Dr Pavlina Fagan, Lusk – nominated by Eamonn Clarke for emergency care of his daughter.

Dr Conor Gallagher, Fenian Street – nominated by John Cullen for the speed of response to a child's problem.

Dr Niall Mac Donagh, South Circular Road – nominated by Lorraine Rice for exceptional care of all the Rice family.



Winner: Dr Anna Zwolinska, Smithfield, nominated for her act of great kindness to her bereaved patient, Brendan Fox.

Dr Seán Malone, Sandycove – nominated by Jane Eyre for prompt emergency care of two broken teeth on a bank holiday weekend.

Dr Edward Owens, Sandford – nominated by Maria O'Cleirigh for her oral care after chemotherapy.

Dr Anna Zwolinska, Smithfield – nominated by Brendan Fox for an act of great kindness.

Finalists in Rest of Leinster



Eilís Tobin of GSK; overall winner Dr James Turner; Dr Paul Hooi; Dr Aoife Farrell; and, Dr Geraldine Honan.

Dr Aoife Farrell, Callan, Co. Kilkenny – nominated by James O’Keeffe for emergency care after a workplace accident.

Dr Geraldine Honan, Navan, Co. Meath – nominated by Sheila Courtney for her ability to calm a frightened patient.

Dr Paul Hooi, Gorey, Co. Wexford – nominated by Colette Hogan for



Winner: *Dr James Turner, Rathdrum, Co. Wicklow, for detection of a throat cancer in his patient, Mary Hallis.*

care of her seven-year-old daughter.

Dr Maeve O’Flynn, Kilkenny – nominated by Deirdre Costigan for exceptional oral healthcare.

Dr James Turner, Rathdrum, Co. Wicklow – nominated by Mary Hallis for detection of her throat cancer.

Finalists in Munster



From left: IDA President Dr Peter Gannon; Dr Aidan Higgins; Dr Anne Twomey; and Eilís Tobin of GSK.

Dr Aidan Higgins – nominated by Alice Myers for providing a “turning point” in her life.

Dr Jason Long – nominated by Veronica Wagner for outstanding care of the patient’s welfare.



Winner: *Dr Aidan Higgins for helping his patient Alice Myers to overcome her fear of dental treatment.*

Dr Gerry McCarthy – nominated by Noreen Harrington for three hours of care on St Stephen’s Day.

Dr Anne Twomey – nominated by Maureen O’Sullivan for care provided in the home.

Sensodyne Sensitive Dentist of the Year

JOURNAL OF THE IRISH DENTAL ASSOCIATION



From left: Eilís Tobin; Dr James Turner; and, Dr Peter Gannon.



The beautiful setting of the Royal Hospital Kilmainham was the perfect venue for this gala evening.



Host Colette Fitzpatrick interviews overall winner Dr James Turner.



Festive winners: Dr Anna Zwolinska, Dr Vincent O'Connor, Dr Aidan Higgins and Dr James Turner celebrate their success.



From left: Nicola Kennedy; Nuala Beecher; Pauline Orme; and Eilís Tobin of GSK.



Honorary Editor of the Journal of the Irish Dental Association, Prof. Leo Stassen, addressed the audience on the night.

A real alternative to amalgam has arrived...
DUAL CURED COMPOSITE!

Fill-Up!™

Deep. Fast. Perfect.

DEEP

- Up to 10mm guaranteed curing

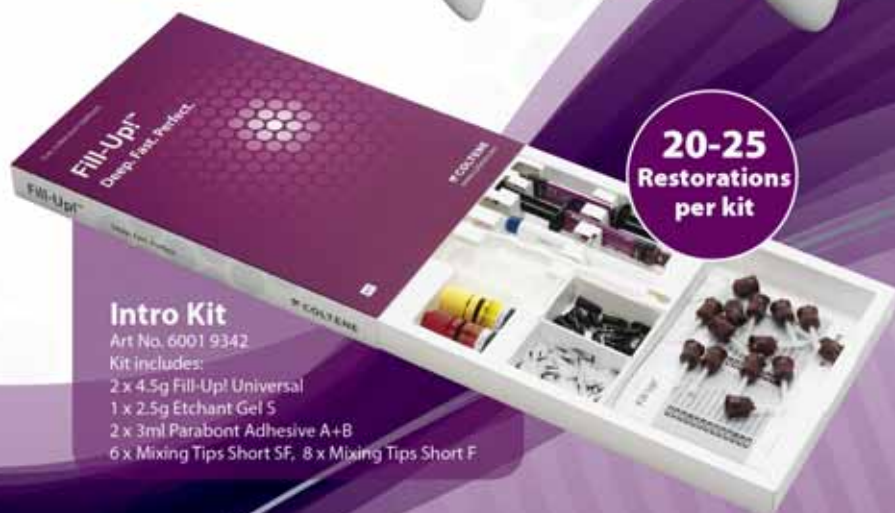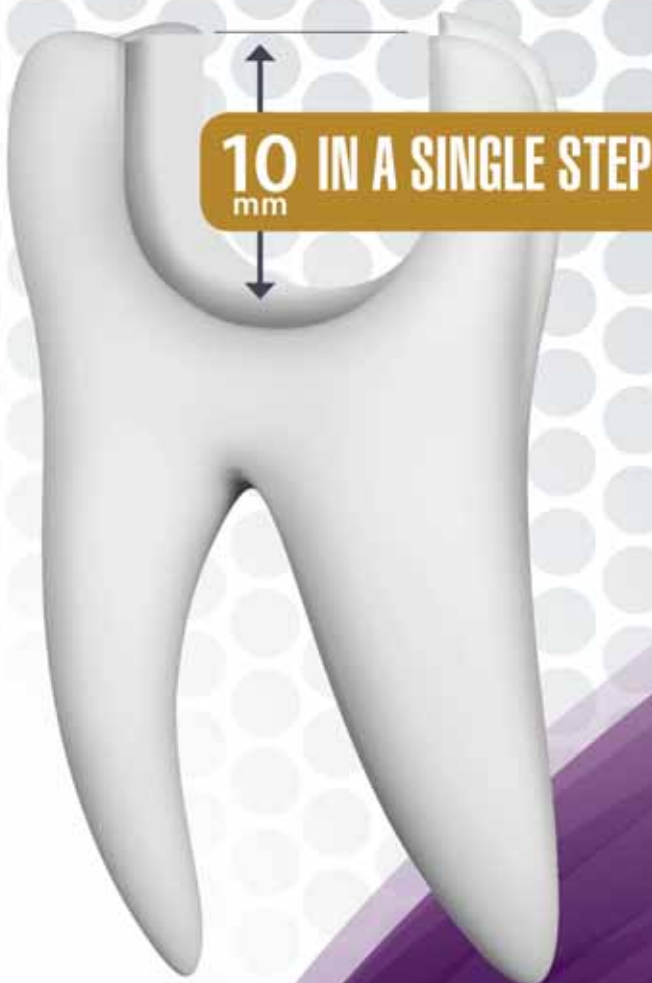
FAST

- Light cures in seconds
- Chemical cure in 3mins

PERFECT

- Minimal shrinkage due to dual cure
- Perfect marginal seal

Suitable for all posterior restorations



Intro Kit

Art No. 6001 9342

Kit includes:

- 2 x 4.5g Fill-Up! Universal
- 1 x 2.5g Etchant Gel S
- 2 x 3ml Parabond Adhesive A+B
- 6 x Mixing Tips Short SF, 8 x Mixing Tips Short F

To book a demonstration,
order a kit or for further information
please call the Fill-Up! hotline

BUY INTRO KIT...
**GET A SLEEVE OF TITLEIST
GOLF BALLS FREE*!**



BUY 3 PACKS OF REFILLS...
**GET A PACK OF LUXURY
LINDT GOLF BALLS FREE*!**



For further information, call the **Fill-Up!** hotline:
Freephone: +44 (0)1444 235486 Ext. 223 Julie or 224 Chris
info.uk@coltene.com | www.coltene.com

COLTENE

www.facebook.com/coltene.uk [@COLTENEUKLTD](https://twitter.com/colteneukltd) [Follow us on Instagram](https://www.instagram.com/colteneukltd) [Follow us on LinkedIn](https://www.linkedin.com/company/coltene) [Follow us on YouTube](https://www.youtube.com/channel/UC...)

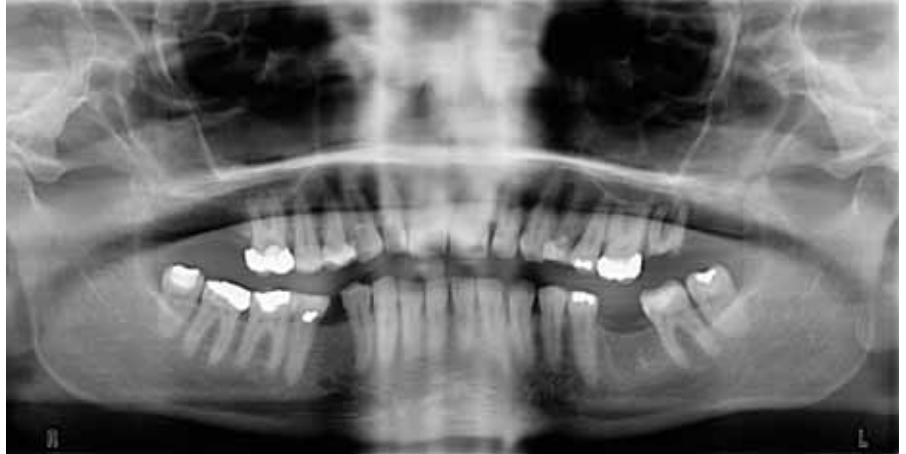

FIGURE 1: OPG showing the upper right first molar tooth (1.6) before extraction. It has a large restoration in place.

Extraction of a maxillary molar tooth

Introduction

Simple extraction of maxillary first and second molar teeth that are heavily restored can often be difficult. Teeth with large restorations or root canal fillings can fracture during a forceps extraction and a surgical technique must then be used. These extractions are further complicated by the tooth's close proximity to the maxillary antrum. Nowadays, atraumatic extraction techniques to preserve buccal bone are imperative as more patients are opting to restore the space with an implant. Raising a buccal flap is often unnecessary and may also lead to the loss of some buccal bone. This technique will describe the atraumatic removal of an upper maxillary molar tooth.

Step-by-step instructions for maxillary molar extraction

STEP 1

Pre-operative assessment of the patient's medical and social history should be carried out, ensuring that there are no contraindications for extraction. The OPG

(Figure 1) must be examined looking at the state of the tooth crown, the shape and length of the tooth roots, proximity to the maxillary antrum and adjacent teeth. In a heavily restored maxillary molar tooth (Figure 2), a surgical extraction must be planned for at the start of the procedure. A written consent form is signed discussing the normal surgical risks, including postoperative bleeding, swelling, bruising, infection, damage to adjacent teeth, creation of an oro-antral communication and the possible need for further surgery.

STEP 2

Assuming that there are no medical contraindications, 400mg ibuprofen and 1g paracetamol are given to the patient pre-operatively. If there is any sign of pre-operative infection, 500mg amoxicillin may also be used before the procedure starts.

STEP 3

Local anaesthetic should be administered to the buccal and palatal aspects of the tooth.

Dr Naomi Rahman

BA BDentSc DCh Dent (OS) FFD

Address for correspondence:

Dr Naomi Rahman

Specialist oral surgeon

Castleknock Orthodontics

The Ashleigh Centre

Castleknock Road

Dublin 15

T: 01-806 6066

E: nrahmanoralsurgery@gmail.com

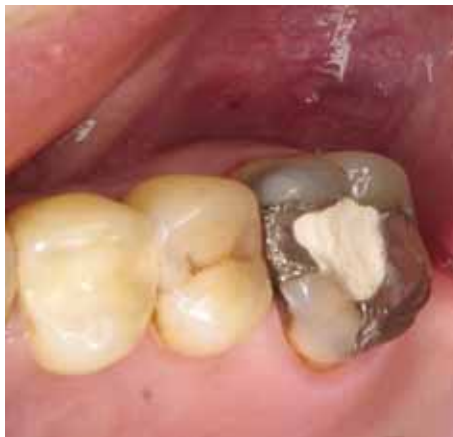

FIGURE 2: Occlusal view of tooth 1.6.

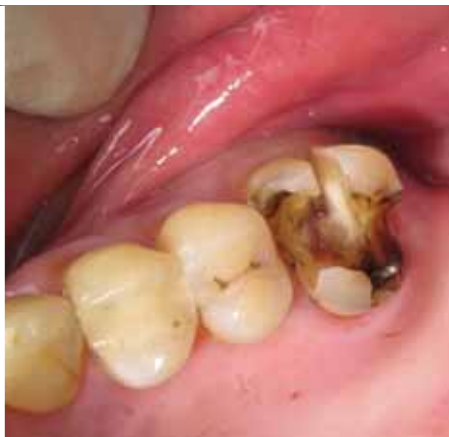

FIGURE 3: Restorative material removed from the tooth.

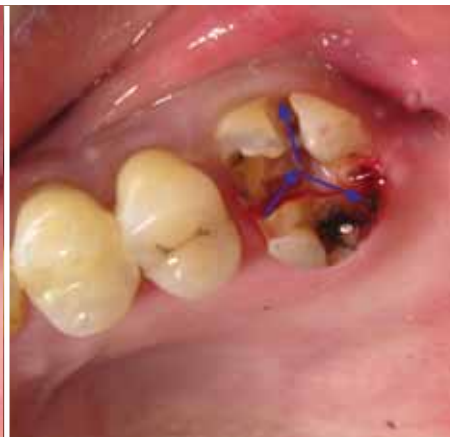

FIGURE 4: Cuts made in the shape of an inverted 'Y' to separate the three roots of the maxillary molar.

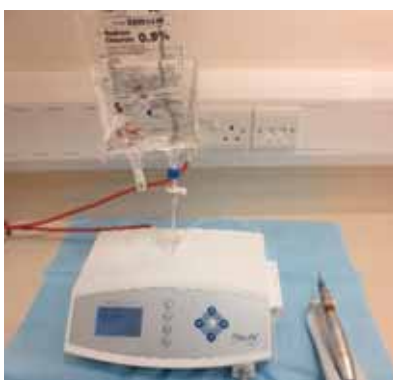

FIGURE 5: Surgical motor and drill with saline irrigation.



FIGURE 6: Surgical fissure bur in handpiece.

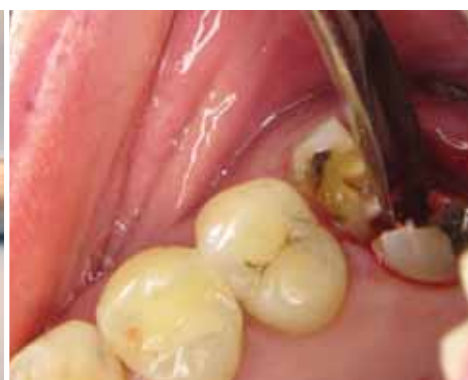

FIGURE 7: Using a large elevator to separate the three roots.

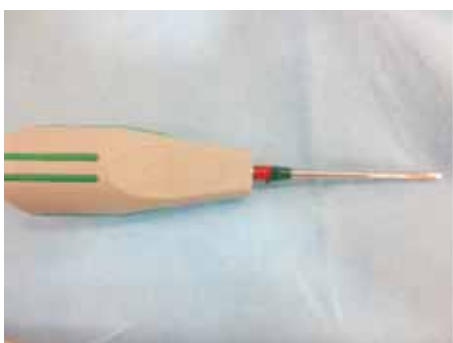
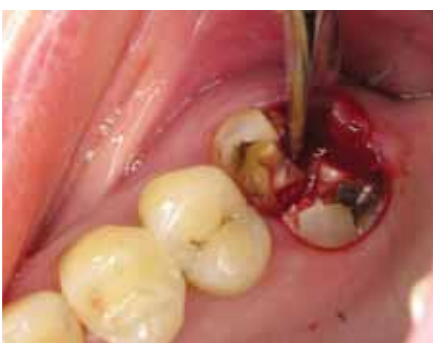
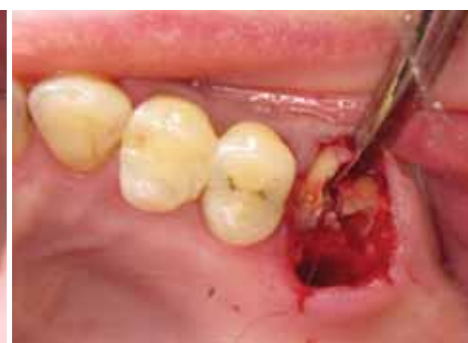
FIGURE 8: Luxator.



FIGURES 9 AND 10: Using a luxator/periosteal separator to break the periodontal ligament circumferentially around each root.



There is no need to raise a buccal flap for extraction of the tooth. Section the tooth crown/restorative material off first to gain visual access to the roots (Figure 3). Then section the roots to make the shape of an inverted 'Y' (Figure 4) with a surgical fissure bur attached to a surgical drill and motor with sterile saline irrigation (Figures 5 and 6). An air rotor drill should not be used, as this can cause the serious complication of surgical emphysema.

STEP 4

Use a large elevator (Figure 7) to fracture the roots into three separate pieces.

STEP 5

Use a periosteal separator to separate the periodontal ligament circumferentially around each root (Figures 8, 9 and 10).

STEP 6

Elevate each root separately with luxators, taking care to keep the buccal and interdental bony support intact. When there are curved, thin, non-vital, or bulbous roots, significant mobility of each should be achieved before attempted extraction from the socket (Figures 11, 12 and 13). A root forceps may be used to remove each root from its socket (Figure 14). In this case there is no need for a suture as no surgical flap has been raised.

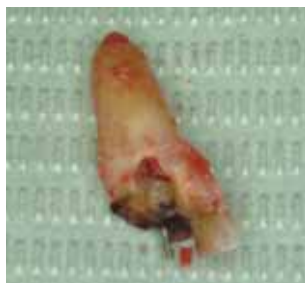

FIGURE 11: Palatal root.

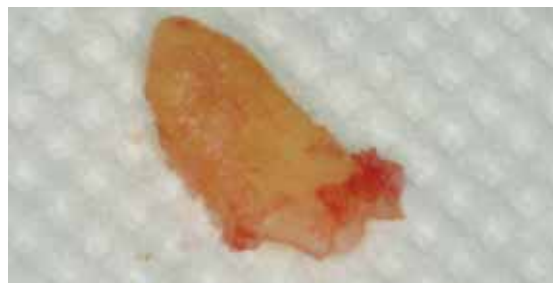

FIGURE 12: Distobuccal root.

STEP 7

Appropriate postoperative analgesia and antibiotics (amoxycillin 500mg tds 5/7) should be prescribed. The patient may be followed up in one week if necessary. This technique should result in reduced postoperative pain and swelling while preserving vital bone volume.

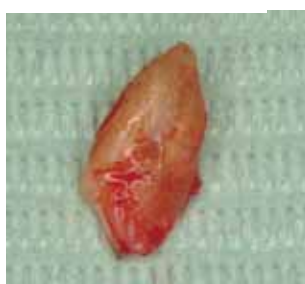

FIGURE 13: Mesiobuccal root.

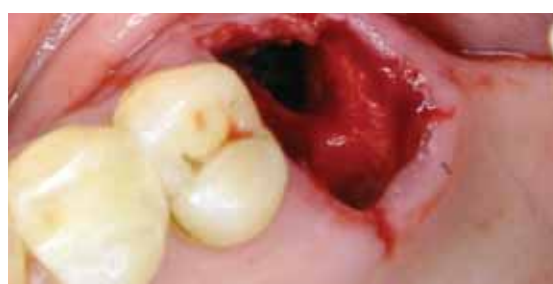

FIGURE 14: Socket site at the end of surgery.







the MAX implant

for immediate placement after a molar extraction



De-coronate the molar.



2mm twist drill followed by incremental tapered drills up to 6mm



Section roots with high speed drills and elevate root remains



Tap the site to ideal depth of implant



Introduce the implant until it's stable and 2mm below lowest part of edge

At Southern Implants, we have been providing innovative solutions to dental professionals since 1987. Solutions like the MAX Implant - the only FDA-certified wide-bodied implant for immediate placement in a multi-rooted molar socket. Available in three industry-compatible interfaces.

X-ray provided by Dr A. Hatfield



www.southernimplants.co.uk

Suite 366, Building 3, Chewick Park, 566 Chewick High Road, London, W4 5WA, UK | Tel: 0044 20 8999 6846 | info@southernimplants.co.uk

Oral carcinoma of the anterior hard palate: an unusual presentation

Précis

Squamous cell carcinoma (SCC) is the most common malignant disease of the oral cavity. It usually affects individuals over 50 years of age, with a history of tobacco or alcohol abuse, or both. This case report highlights the unusual presentation of an SCC in a young 22-year-old male. He was a non-smoker, social alcohol drinker, and was generally fit and well. Alongside the fact that this young patient had none of the usual risk factors for oral cancer, the abnormal lesion discovered on his anterior palate did not resemble a typical oral SCC. It was found in proximity to the maxillary central incisors, which had previously suffered trauma. Clinical and histopathological findings, and treatment, are discussed.

Journal of the Irish Dental Association 2014; 60 (6): 293-297.

Dr Lisa Walshe

BA BDentSc (TCD) MFDS (RCSI)
Oral and Maxillofacial Surgery Registrar
St James's Hospital
Dublin

Dr Osama Omar

Senior Lecturer/Consultant in
Maxillofacial Prosthodontics
Dublin Dental University Hospital

Dr Denise MacCarthy

Senior Lecturer/Consultant Restorative
Dentistry/Periodontology
Dublin Dental University Hospital

Prof. Leo F.A. Stassen

Professor of Oral & Maxillofacial Surgery
St James's Hospital

Address for correspondence:

Prof. Leo F.A. Stassen
Professor of Oral & Maxillofacial Surgery
St James's Hospital

Introduction

Head and neck cancer, the sixth most common cancer, is described as cancer of the lip, mouth, tongue, tonsil, pharynx (unspecified), salivary gland, hypopharynx, larynx and other. Oral cancer refers to cancer of the tongue, gingiva, floor of the mouth, palate, vestibule and retromolar area, and represents more than 90% of all head and neck cancers.¹ Historically, scientific literature has demonstrated a preferential incidence of head and neck cancers in men aged 50 to 70 years. However, an increasing number of young patients are being affected worldwide and most studies suggest that 4-6% of oral cancers now occur at ages younger than 40 years.² These are predominantly oral and oropharyngeal cancers. Recent epidemiological studies have shown an increase in the development of oral SCC in women and a decrease in the male:female ratio in young patients diagnosed with oral cancer.²⁻⁶ The increasing incidence of oral cancer in females results from an increased acceptability of tobacco and alcohol use among young women.⁷⁻⁹

Risk factors

Several studies examining risk factors for oral cancer in the young provide evidence that many younger patients have never smoked or consumed alcohol, or that duration of exposure may be too short for malignant transformation to occur. In these cases, cancer may be a different disease from that occurring in older patients. It may have a different aetiology and clinical progress, with a weaker link to the risk factors, and it has been suggested to have a more aggressive course.¹⁰⁻¹² Factors that have been investigated in order to explain the aetiology of oral SCC in young patients include genetic predisposition, previous viral infections, nutritional patterns, immunodeficiency, occupational exposure to carcinogens, socioeconomic conditions and oral hygiene.⁴ A family history is associated with an earlier onset of head and neck SCC and there are several studies indicating an increased risk in first-degree relatives.⁴ Evidence is perhaps strongest for infection with the human papillomaviruses (HPV).^{13,14} A recent multi-centre case control study reported that

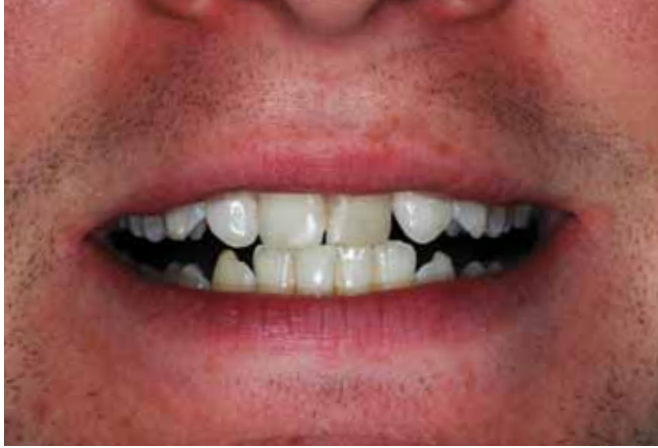

FIGURE 1: The patient's appearance on presentation.

infection with HPV-16 increased the risk of cancer of the oral cavity and particularly the oropharynx.^{15,4}

Site

Head and neck SCC in young patients tends to occur in the oral cavity and oropharynx.¹⁶ In the oral cavity, the tongue is the most common site in the young and, interestingly, the floor of mouth has been reported as a less common site compared with older patients.^{2,3,17} There appears to be a rising number of HPV-associated tonsil carcinomas, particularly in males (smokers and non-smokers). El Mofty demonstrated a strong association with HPV-16 and tonsillar cancer in males less than 40 years of age.¹⁸ It has been suggested that HPV must be a factor in the distinct group of less than 40 year olds, usually female non-smokers, with oral cancer, but El Mofty and O'Regan indicate otherwise.^{18,19}

The increasing trend of oral SCC in young individuals without known risk factors highlights the need for clinicians to be vigilant and carry out mouth cancer screening examinations for every patient regardless of age or associated risk factors. It is paramount that we are able to recognise oral disease/pathology at an early stage, providing a better prognosis, chance of survival, and quality of life for the patient. Unfortunately, many patients are still diagnosed with advanced disease, with over 60% presenting with either regional or distant spread.^{20,21} The five-year survival rates of oral cancer range between 50 and 80%, depending on the stage of the disease, varying from 86% for stage I (early diagnosis) to 12-16% for stage IV (late diagnosis).^{22,23} A major factor in poor outcome for oral cancers is late presentation, due in part to lack of awareness about oral cancers in the community. In a recent study of an outpatient hospital population, it was concluded that there was a poor level of knowledge about head and neck cancers in a population in the West of Ireland. Some 70% of respondents had never heard of head and neck cancer, 73% did not consider alcohol a risk factor and less than 50% would be concerned by persistent hoarseness or a prolonged oral ulcer. It has been shown that the probability of avoiding regional spread, and the associated 50% reduction in survival, is inversely related to diagnostic delay.²⁴

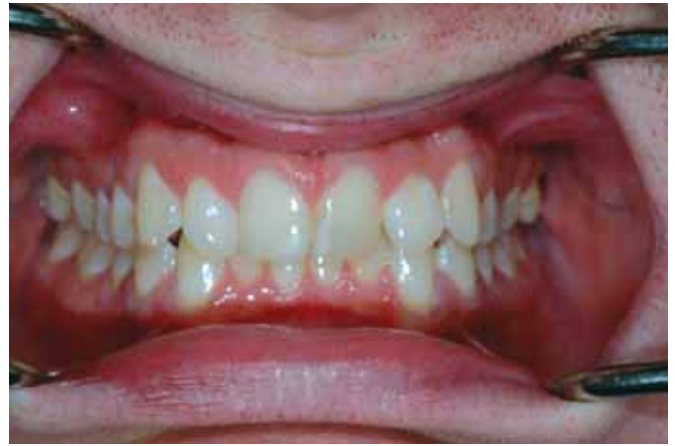

FIGURE 2: The teeth and gingiva on presentation.

The significant link between diagnostic delay and advanced stage presentation in relation to oral and pharyngeal cancer was confirmed in a recent meta-analysis by Gomez *et al.* in 2011.²⁵

Treatment of oral cancer has a major impact for patients in view of the importance of the mouth for speech, mastication and swallowing. However, advances in reconstruction have contributed greatly to patients' quality of life. Microvascular replacement of missing tissue and bone, innervated flaps, facial reanimation, and the advent of osseointegrated implants have led to functional rehabilitation.

In this article, we present an unusual case of oral SCC in a fit and healthy 22-year-old male with no history of alcohol or tobacco abuse. There was also a history of trauma to the incisor teeth in proximity to where the cancer was located approximately five years prior to the diagnosis.

Case report

A healthy 22-year-old male was referred by his general dental practitioner (GDP) to the Dublin Dental University Hospital for a periodontal assessment of a red swelling on the anterior palate (**Figure 1**). The swelling had been present for approximately two years and when the GDP noticed the abnormality on routine examination he recommended further investigation immediately. His presenting complaint was the presence of a red swelling on the anterior region of the hard palate related to the palatal gingival margin of 2.1 and 2.2 (**Figure 2**). The patient felt that the red swelling on the palate had been slowly increasing in size over the previous two years but he was not concerned as there was no associated pain. There was bleeding from the palatal area at times but no discharge or bad taste from the site. The central incisors had suffered minor trauma approximately five years prior to this and two composite restorations were required. Medically, the patient was fit and well, a non-smoker and a social drinker.

Clinical findings showed a swelling on the hard palate in close proximity to the upper left central and lateral incisors. It measured 15mm in size, had an irregular shape and was well defined with rolled margins. The swelling had a sessile granular appearance and was dark

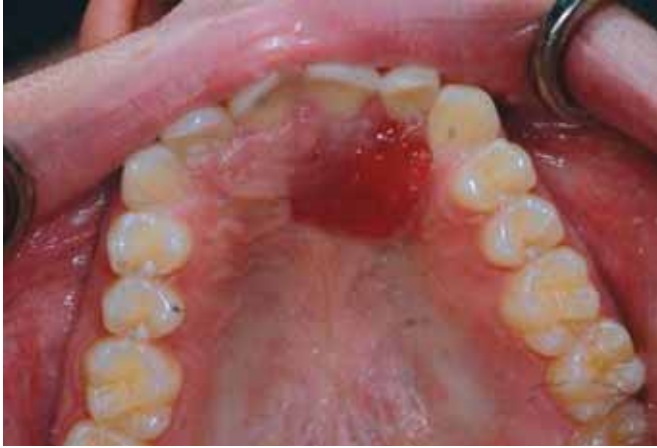

FIGURE 3: The palatal lesion.

red in colour with a vascular appearance. The area was soft to touch, non-tender, non-indurated, non-ulcerated, and the edges were slightly raised (Figure 3). All the anterior teeth responded to electric and thermal pulp testing. A panoramic radiograph revealed significant bone loss around the upper left central and lateral incisors, although there was no periodontal bone loss elsewhere in the mouth (Figure 4).

Management

The lesion had some features similar to an endodontic infection, clinically and radiographically, but the teeth remained vital. The margins of the lesion were slightly raised and rolled, raising suspicions of a cancer. A biopsy was carried out and histological analysis confirmed an SCC. The patient was immediately referred to the Oral and Maxillofacial Surgery Department in St James's Hospital for an oral cancer work up. Investigations included computed tomography (CT) and positron emission tomography (PET) scanning. In this case, investigations confirmed that the carcinoma was confined to the palate and no secondary tumours were located with a diagnosis of T1N0M0. Surgery was the treatment of choice for this cancer of the maxillary alveolus and the hard palate. This patient had wide local excision with resection of the involved mucoperiosteum and the underlying bone to ensure that an adequate margin was removed. An anterior maxillectomy, including the right and left inferior concha extending from the upper left second premolar to the upper right first molar, was carried out under general anaesthetic (Figure 5). Access was adequate to the posterior margin of the tumour and, therefore, it was not felt necessary to perform a lip-split to achieve a clear margin. Mucosal incisions were made allowing a 1cm margin of normal tissue, and bony cuts were made with an oscillating saw. After the exposure was obtained, dental extractions were performed as planned (Figure 6). The alveolar cuts were made through the sockets of the extracted teeth. This allows good bony support for the remaining teeth to support early dental rehabilitation. The specimen was removed from the mouth and prompt packing of the maxillectomy cavity helped to achieve haemostasis. A preformed dental obturator was placed in the

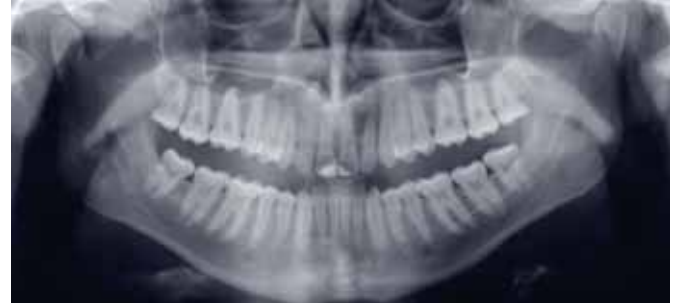

FIGURE 4: The panoramic radiograph shows resorption of the alveolar bone in the region of the upper left lateral incisor root. The radiolucent area was well localised to the lateral incisor and there was no sign of invasive resorption of the alveolar crest. Composite restorations can also be seen on the maxillary central incisor teeth. No root canal treatment was indicated at the time of trauma to the incisors.

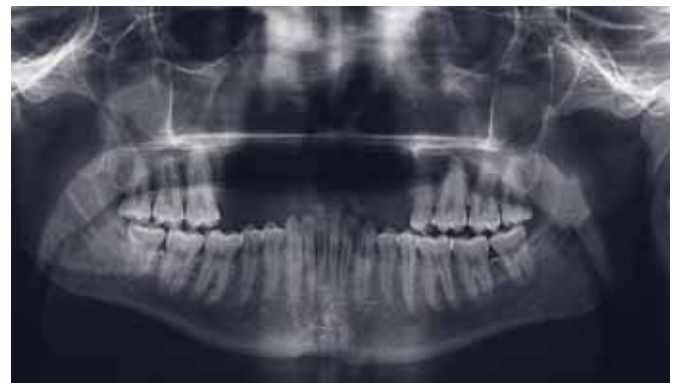

FIGURE 5: The postoperative panoramic radiograph outlining the extent of the maxillectomy and teeth extracted.

defect. Obturation is relatively quick as a reconstructive option at the time of primary surgery. The obturator had the advantage that the cavity could be inspected for recurrence and that it was relatively easy to achieve adequate speech and dental aesthetics. The disadvantage is the need for maintenance of the obturator over the life span of the patient and the debilitating effect of the prosthesis on an otherwise young, healthy, previously fully dentate male.

A permanent cobalt chrome obturator was fabricated when healing of the surgical site was adequate (Figure 7). Due to the early diagnosis, this disease was managed by surgery alone. Chemotherapy and radiotherapy were not indicated. This significantly reduced the long-term morbidity for the patient. The patient underwent an intense oral hygiene and preventive programme with the dental hygienist in the Dublin Dental University Hospital. Poor oral hygiene is a frequent finding in cancer patients and the need for adequate pre-operative and postoperative intraoral cleaning procedures was emphasised. This patient managed extremely well postoperatively and is currently wearing a cobalt chrome denture replacing his front teeth with a palatal obturator (Figure 8). He is now considering the possibility of free flap reconstruction with bone and soft tissue to complete full oral reconstruction.

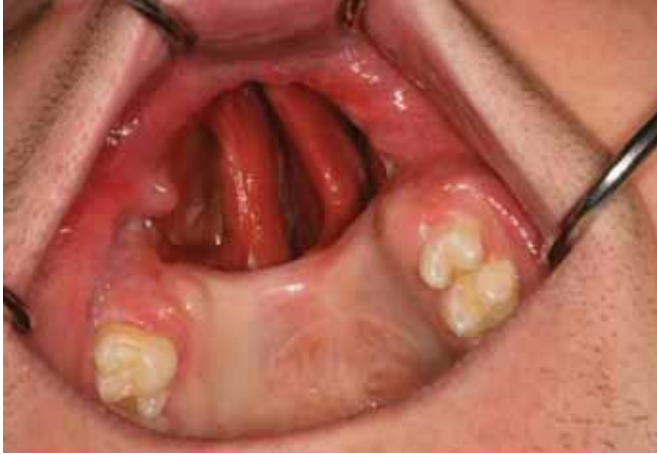

FIGURE 6: The palatal defect after surgical resection.

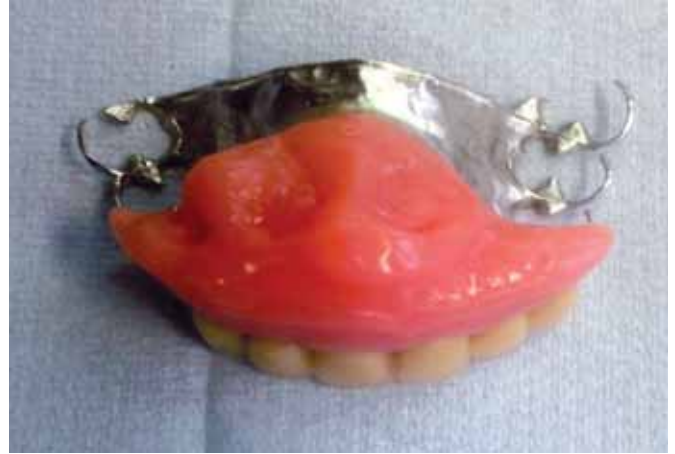

FIGURE 7: The cobalt-chrome obturator.

Discussion

The above case describes an unusual case of oral SCC treated recently. In this case report, the patient did not present with any of the usual risk factors. He was young, otherwise healthy, a non-smoker and a social drinker. Although smoking, especially with alcohol consumption, is a major cause of oral cancer, we must remember that non-smokers and non-drinkers can also develop the disease. Carcinomas of the hard palate and upper alveolus are relatively uncommon, accounting for 10% of oral cancers,²⁶ except in areas of India and Southeast Asia where reverse smoking is practised.²⁷ In the West, smokeless tobacco has not emerged as a significant risk factor in young patients. Shiboski noted carcinoma of tonsil, tongue and base of tongue increasing in young white patients from 1973-2001 in the United States.²⁸ Carcinoma of the hard palate is only half as common as carcinoma of the soft palate,^{29,30} and carcinoma of the

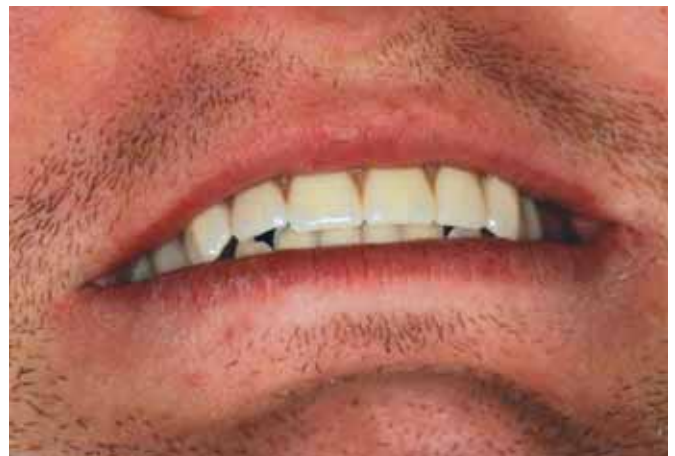

FIGURE 8: Appearance after placement of the denture.

Table 1: Warning symptoms and signs

A non-healing ulcer for more than three weeks is a mouth cancer until proven otherwise and requires referral and biopsy.
A persistent red/white patch (erythroleukoplakia) of no known cause, velvety like, which might even bleed on touch.
A new/expanding lump in the mouth with no known cause.
Any new lump on the palate, in the buccal mucosa, floor of mouth, or tongue lasting more than two weeks.
Unexplained numbness of the lip (upper and lower), tongue or face.
Difficulty chewing (limited mouth opening), swallowing or moving the tongue (fixed).
Unexplained loose teeth, bleeding from the mouth for no known reasons.
Persistent sore throat/hoarseness for longer than three weeks, ear pain.
Persistent nosebleeds/stuffy nose.
Discolouration or black pigmentation with satellite lesions in the mouth or on the head and neck skin.
Any salivary (parotid, submandibular or sublingual) or neck lumps, especially if any tendency to hardness.
A dental extraction site failing to heal.

maxillary alveolar ridge is only one-third as common as carcinoma of the mandibular alveolar ridge.³¹ These areas are lined with adherent keratinised mucosa that provides protection from the forces of mastication and may provide relative protection of the basal nuclei from the effects of carcinogens. Lesions of the maxillary alveolar ridge are often symptomatic, allowing early diagnosis. Some 82% of maxillary alveolar ridge carcinomas are T1 or T2 at the time of diagnosis, and 86% are N0.³¹ Palatal carcinomas tend to be larger when diagnosed, but only 13% have regional metastases when diagnosed.²⁹ The presence of regional metastases to the neck or locally advanced disease decreases five-year survival from approximately 70% to approximately 30%.³⁰

Fortunately, this cancer was well localised and diagnosed early. However, this is not always the case and, when the cancer is more advanced, the effects of treatment can be debilitating and disfiguring as well as having serious psychological effects on the patients. If we can strengthen the patient, dentist and doctor awareness of oral cancer, we can ensure a prompt referral to a secondary care facility. This can usually improve their treatment outcomes. If mouth cancer is suspected, patients should be directly referred by dental surgeons or

medical practitioners to the dental hospitals or nearest oral cancer service by telephone and referral letter. Dentists and dental hygienists also have an important role in prevention, with regard to smoking cessation, alcohol intake and diet, especially in our younger population. Diagnosis of any 'potentially malignant lesions' such as leuko/erythroplakias needs to be at the forefront of our minds when doing clinical examinations of patients regardless of age, risk factors and presenting complaints (Table 1). The mainstay of management at present involves a biopsy, investigations of the size, local spread and distant spread, discussion at a multidisciplinary meeting and a decision based on present research on the best treatment: oral and maxillofacial surgery, head and neck radiotherapy or chemotherapy. Most often it is a combination of treatments.

References

1. **National Cancer Registry Ireland, 2010.** Available from: http://www.ncri.ie/data.cgi/client/generate_stats.php.
2. **Llewellyn, C.D., Johnson, N.W., Warnakulasuriya, K.A.** Risk factors for oral cancer in newly diagnosed patients aged 45 years and younger: a case-control study in Southern England. *J Oral Pathol Med* 2004; 33 (9): 525-532.
3. **Martin Granizo, R., Rodriguez Campo, F., Naval, L., Diaz Gonzalez, F.J.** Squamous cell carcinoma of the oral cavity in patients younger than 40 years. *Otolaryngol Head Neck Surg* 1997; 117: 268-275.
4. **Hirota, S.K., Migliari, D.A., Sugaya, N.N.** Oral squamous cell carcinoma in a young patient – case report and literature review. *Ann Bras Dermatol* 2006; 81: 251-254.
5. **Mosleh-Shirazi, M.S., Mohammadianpanah, M., Mosleh-Shirazi, M.A.** Squamous cell carcinoma of the oral tongue: a 25-year, single institution experience. *J Laryngol Otol* 2009; 123: 114-120.
6. **Tremblay, S., dos Reis, P.P., Bradley, G., Galloni, N.N., Perez-Ordenez, B., Freeman, J., et al.** Young patients with oral squamous cell carcinoma. *Arch Otolaryngol Head Neck Surg* 2006; 132: 958-966.
7. **Binahmed, A., Charles, M., Campisi, P., Forte, V., Carmichael, R.P., Sándor, G.K.** Primary squamous cell carcinoma of the maxillary alveolus in a 10-year-old girl. *J Can Dent Assoc* 2007; 73: 715-718.
8. **Jaber, M.A.** Oral epithelial dysplasia in non-users of tobacco and alcohol: an analysis of clinicopathologic characteristics and treatment outcome. *J Oral Sci* 2010; 52 (1): 13-21.
9. **Curado, M.P., Hashibe, M.** Recent changes in the epidemiology of head and neck cancer. *Curr Opin Oncol* 2009; 21 (3): 194-200.
10. **Hirota, S.K., Braga, F.P.F., Penha, S.S., Sugaya, N.N., Migliari, D.A.** Risk factors for oral squamous cell carcinoma in young and older Brazilian patients: a comparative analysis. *Med Oral Patol Oral Cir Bucal* 2008; 13: 227-231.
11. **Oliver, R.J., Dearing, J., Hindle, I.** Oral cancer in young adults: report of three cases and review of the literature. *Br Dent J* 2000; 188: 362-365.
12. **Popovtzer, A., Shpitzer, T., Bahar, G., Marshak, G., Ulanovski, D., Feinmesser, R.** Squamous cell carcinoma of the oral tongue in young patients. *Laryngoscope* 2004; 114: 915-917.
13. **Herrero, R., Castellsague, X., Pawlita, M., et al.** Human papillomavirus and oral cancer: the International Agency for Research on Cancer multicentre study. *J Natl Cancer Inst* 2003; 95: 1172-1183.
14. **Kreimer, A.R., Clifford, G.M., Boyle, P., Franceschi, S.** Human papillomavirus types in head and neck squamous cell carcinomas worldwide: a systematic review. *Cancer Epidemiol Biomarkers Prev* 2005; 14: 467-475.
15. **D'Souza, G., Kreimer, A.R., Viscidi, R., et al.** Case-control study of human papillomavirus and oropharyngeal cancer. *N Engl J Med* 2007; 356: 1944-1956.
16. **Verschuur, H.P., Irish, J.C., O'Sullivan, B., Goh, C., Gullane, P.J., Pintilie, M.** A matched control study of treatment outcome in young patients with squamous cell carcinoma of the head and neck. *Laryngoscope* 1999; 109 (2, Pt 1): 249-258.
17. **Funk, G.F., Karnell, L.H., Robinson, R.A., Zhen, W.K., Trask, D.K., Hoffman, H.T.** Presentation, treatment, and outcome of oral cancer: a National Cancer Data Base report. *Head Neck* 2002; 24 (2): 165-180.
18. **El-Mofty, S.K., Lu, D.W.** Prevalence of human papillomavirus type 16 DNA in squamous cell carcinoma of the palatine tonsil, and not the oral cavity, in young patients: a distinct clinicopathologic and molecular disease entity. *Am J Surg Pathol* 2003; 27 (11): 1463-1470.
19. **O'Regan, E.M., Toner, M.E., Finn, S.P., et al.** p16(INK4a) genetic and epigenetic profiles differ in relation to age and site in head and neck squamous cell carcinomas. *Hum Pathol* 2008; 39 (3): 452-458. doi:10.1016/j.humpath.2007.08.004.
20. **Altekruse, S.F., Kosary, C.L., Krapcho, M., Neyman, N.** SEER Cancer Statistics Review 1975-2007. 2009 [cited 2010, 27 November]; Available from: http://seer.cancer.gov/csr/1975_2007.
21. **Cancer research-UK.** UK oral cancer incidence and mortality statistics. 2008. Available from: <http://info.cancerresearchuk.org/cancerstats/types/oral>.
22. **Kerdpon, D., Sriplung, H.** Factors related to advanced stage oral squamous cell carcinoma in southern Thailand. *Oral Oncol* 2001; 37 (3): 216-221.
23. **Speight, P., Warnakulasuriya, K.A.** Evaluation of screening for oral cancer against NSC criteria. 2010. Available at: http://www.4everlearning.com/pdfs/Evaluation_of_screening_for_oral_cancer_against_NSC_Criteria-1.pdf.
24. **O'Connor, T.E., Papanikolaou, V., Keogh, I.J.** Public knowledge of head and neck cancer. *Irish Med J* 2010; 4: 105-107.
25. **Gomez, I., et al.** Is diagnostic delay related to advanced stage oral cancer? A meta-analysis. *Eur J Oral Science* 2011; 117: 541-546.
26. **Petruzzelli, G.J., Myers, E.N.** Malignant neoplasms of the hard palate and upper alveolar ridge. *Oncology (Williston Park)* 1994; 8 (4): 43-48.
27. **Reddy, C.R.** Carcinoma of hard palate in India in relation to reverse smoking of chuttas. *J Natl Cancer Inst* 1974; 53 (3): 615-619.
28. **Shiboski, C.H., Schmidt, B.L., Jordon, R.C.** Tongue and tonsil carcinoma: increasing trends in the US population ages 20-44 years. *Cancer* 2005; 103 (9): 1843-1849.
29. **Ratzer, E.R., Schweitzer, R.J., Frazell, E.L.** Epidermoid carcinoma of the palate. *Am J Surg* 1970; 119 (3): 294-297.
30. **Evans, J.F., Shah, J.P.** Epidermoid carcinoma of the palate. *Am J Surg* 1982; 142 (4): 451-455.
31. **Soo, K.C., Spiro, R.H., King, W., et al.** Squamous carcinoma of the gums. *Am J Surg* 1988; 156 (4): 281-285.

Does the dentist have a role in identifying patients with undiagnosed diabetes mellitus?

Précis

This paper provides a literature review of the role of the dentist in screening patients for undiagnosed diabetes in the dental clinic. It highlights both dentist and patient attitudes towards such screening methods.

Abstract

Statement of the problem: Diabetes has become an epidemic and the incidence of undiagnosed diabetes is growing at an alarming rate. Diabetes is an associated risk factor for chronic periodontitis and has several other oral symptoms including dry mouth and oral infection. Expanding the role of the dentist may prove to be an efficient method of early detection and management of diabetes.

Purpose of the study: The aim of this paper is to critically analyse the literature and determine whether screening for undiagnosed diabetes mellitus is within the dentist's scope of practice.

Materials and methods: A PubMed/Google Scholar/Google literature search was conducted of papers published in the English language in the years 1980–2013. Over 140 articles were examined. Reference lists of key articles were also sourced and analysed. The most pertinent articles are presented in this review.

Results: Screening for diabetes mellitus in the dental office should only be carried out for high-risk patients in order for such screenings to be cost-effective.

Conclusions: Dentists have an ethical obligation and a duty of care to protect the well-being of their patients. A screening procedure to detect a serious underlying, undiagnosed systemic condition does not cause any harm to the patient and is in the patient's best interests.

Journal of the Irish Dental Association 2014; 60 (6): 298-303.

Sultan A
Warreth A
Fleming P
MacCarthy D

Address for correspondence:

Dr Denise MacCarthy

Senior Lecturer Consultant
Head of Division 2 – Restorative Dentistry
& Periodontology
Dublin Dental University Hospital
Lincoln Place
Dublin 2

T: 01-612 7239

F: 01-612 7297

E: Denise.MacCarthy@dental.tcd.ie

Introduction

Diabetes mellitus is a syndrome of abnormal carbohydrate, fat and protein metabolism that is caused by an absolute or relative lack of insulin.¹ Type 1 diabetes usually develops

in childhood and has a genetic, viral or autoimmune aetiology. Type 2 diabetes has a multifactorial aetiology with a strong genetic component and the condition can be prevented by simple lifestyle education.²

Type 2 diabetes accounts for 90% of diabetes worldwide and is characterised by insulin resistance.

Diabetes mellitus is now an epidemic with 366 million people affected globally.³ This number is projected to rise to 552 million in 2030.³ It is estimated that 183 million people with diabetes are undiagnosed.³ Diabetes is reported to have been responsible for 4.6 million deaths worldwide in 2011.³ The World Health Organisation (WHO) has projected that diabetes will be the seventh leading cause of death in the year 2030. Complications of undiagnosed or poorly controlled diabetes include retinopathy, neuropathy, nephropathy, peripheral vascular disease, coronary heart disease, gangrene and periodontitis. Early detection of pre-diabetes may stop the transition to established diabetes mellitus and, subsequently, life-threatening complications may be avoided.⁴ In the United States (US), up to 65% of people attend their dentist every year.⁵ In Europe, 57% of people visit their dentist every year and 54% of Irish people attend their dentist annually.⁶ This puts the dentist in a favourable position to screen for undiagnosed diabetes and to make a referral for further investigations to the patient's physician.

This literature review aims to determine whether the dentist has a role in screening patients for undiagnosed diabetes in the dental clinic.

Oral features of diabetes mellitus

Apart from obvious signs and symptoms of hyperglycaemia such as sudden unexplained weight loss, acanthosis nigrans marker, visual disturbances, polyuria (increased urination), polydipsia (increased thirst), polyphagia (increased appetite) and lethargy, there are various oral features that can be detected during a routine dental examination, which may alert the dentist to an undiagnosed systemic condition. The poorer the glycaemic control, the more evident the oral manifestations of diabetes mellitus are to the clinician. However, these oral features are not exclusive to diabetes and other causes should be excluded.

The most common oral complications of diabetes are gingivitis and periodontal disease. Periodontal disease was described by Loe⁷ as the sixth complication of diabetes and he concluded that adults were three times more likely to have periodontitis if they suffered from diabetes. Periodontitis has also been reported in children with poorly controlled diabetes and research shows that individuals with diabetes have higher plaque levels than non-diabetics.⁸ Initially, individuals with diabetes develop gingivitis and the transition to, and progression of, periodontitis is related to the rate at which the glycaemic control worsens. Salivary hyperglycaemia and an elevated glucose content of the gingival crevicular fluid are thought to provide an added supply of nutrients to periodontal bacteria. It has also been established that periodontal disease and diabetes share a bidirectional relationship,⁹ where poor glycaemic control impacts on the outcome of periodontal treatment and periodontitis negatively affects the patient's glycaemic control. Advanced glycation end products (AGEs) are formed under hyperglycaemic conditions due to non enzyme-based reactions involving the metabolism of lipids and proteins, and the build up of AGEs in the gingival tissues interferes with collagen formation.¹⁰ The

level of receptor for advanced glycation end products (RAGE) is elevated in the gingival tissue of people with diabetes. Expression of RAGE on the cell membranes of gingival epithelial cells and fibroblasts enables signalling through RAGE, which releases harmful free radicals and pro-inflammatory components that exacerbate periodontal disease and diabetes mellitus.¹¹ Patients with diabetes also have a greater susceptibility to infections and subsequently have a poor response to healing¹² due to impaired neutrophil and fibroblast function.¹⁰

Polyuria due to osmotic diuresis leads to dehydration and therefore reduced production and altered consistency of saliva resulting in xerostomia^{12,13} and dysgeusia (altered taste).^{12,14} Xerostomia may also be a side effect of diabetic medication.

Chronic periodontitis is characterised by clinical attachment loss resulting in gingival recession. Gingival recession, along with salivary hyperglycaemia and salivary hypofunction predispose to an increased incidence of root caries in diabetic patients.¹⁵ The evidence linking coronal caries to diabetes, however, is inconsistent. Diabetic individuals yield higher streptococci count in their oral flora, suffer from salivary dysfunction and have reduced salivary buffering capacity that may contribute to increased dental caries. Lalla and colleagues⁸ carried out a study on 342 children and found that the caries experience was the same between children with diabetes and non-diabetic children.

Candida albicans is an opportunistic fungal pathogen that is commonly present in the mouth and can become pathogenic in the presence of predisposing factors. In people with diabetes, impaired neutrophil function, xerostomia and salivary hyperglycaemia predispose to oral candidial infections, including oral candidiasis,¹²⁻¹⁴ angular cheilitis,¹⁶ denture stomatitis¹⁶ and median rhomboid glossitis.¹³

Longstanding hyperglycaemia can cause neuropathy and dehydration, which may manifest as a burning sensation in the oral cavity. This burning sensation can be one of the presenting symptoms of chronic hyperglycaemia and is frequently overlooked during clinical examination. A burning sensation in the mouth has been found to be more prevalent in patients with undiagnosed type 2 diabetes.^{13,14}

Epidemiological data from Hungary suggests that patients with diabetes may be at an increased risk of developing potentially malignant lesions in the oral cavity, although this is the only study to have shown this.¹⁷ However, the accuracy of using fasting blood glucose for diabetes testing may be less than satisfactory. Also, there was a high percentage of current and recent smokers in the group.

Oral hypoglycaemic drugs are known to cause lichenoid drug eruptions,¹⁸ which may be indistinguishable from the clinical appearance of oral lichen planus (OLP). Coated tongue and erythema migrans (geographic tongue) have been noted in patients with diabetes mellitus.^{13,16} Recurrent oral infections such as recurrent ulceration, recurrent episodes of herpes simplex infections and recurrent periodontal abscesses are all reported in diabetes mellitus, especially in marginally controlled cases. Halitosis, specifically in the form of a distinct ketonic breath, has been observed in patients with

Table 1: Oral features associated with diabetes mellitus.

Gingivitis	Increased susceptibility to oral infections
Periodontitis	Salivary hyperglycaemia
Poor wound healing	Elevated glucose content of gingival crevicular fluid
Dry mouth	Dysgeusia
Root caries	Sialosis
Candidal infections including angular cheilitis, denture stomatitis and median rhomboid glossitis	Impaired neutrophil and fibroblast function
Halitosis	

uncontrolled diabetes. **Table 1** shows oral features that have been reported to be associated with diabetes mellitus.

Asymptomatic bilateral enlargement of the parotid glands is referred to as sialosis¹³ and is seen in approximately 24% of individuals with diabetes mellitus.¹⁹ Infiltration of the parenchyma with adipose tissue leads to the enlargement of the parotid glands.

Dental office screening models for diabetes mellitus

Dental office screening for diabetes mellitus using gingival crevicular blood is a relatively new concept and only a few studies have been carried out, with no randomised controlled trials available to date. The advantages of utilising blood collected following periodontal probing are two-fold. Firstly, the patient's attitude towards this form of screening is more tolerated and viewed as less invasive than alternative screening methods such as finger prick testing.^{20,21} Secondly, the majority of state dental boards in the US do not approve the use of fingersticks for screening by dentists.

Studies have proven that glucose levels of blood obtained from the gingival crevice are significantly comparable to glucose levels of blood obtained from the finger puncture method²²⁻²⁵ and venous blood.^{23,26} A small amount of blood ranging from 0.3ml²³ to 0.6ml¹⁵ is enough for a measurement to be carried out with a self-monitoring device. Strauss and colleagues²⁷ showed that 85% of patients were capable of producing sufficient bleeding for a measurement.

Obtaining a blood sample from the gingival crevice involves isolating the most anterior tooth with a cotton roll, probing the pockets around the tooth with light pressure of no more than 20g and then placing a test strip directly into contact with the gingival crevicular blood. A reading can be processed in five seconds and the monitor can then be set aside and the periodontal screening completed.¹⁵

There are four principal blood tests used to screen for diabetes: fasting blood glucose (FBG); oral glucose tolerance test (OGTT); random blood glucose (RBG); and, glycosylated haemoglobin A1c (HbA1c). FBG and OGTT are not practical for dental patients as patients must be fasting for at least eight hours prior to these tests.²⁸ HbA1c, which gives a measure of the level of glucose bound to haemoglobin and is a reflection of the blood glucose control over the previous three months, has recently been advocated by the American Diabetes

Table 2: Effectiveness of screening for undiagnosed diabetes in the dental clinic.

Study	Year	Number	Methods	Results
Strauss and colleagues ²⁷	2012	120	Fingerstick blood samples from 120 patients and gingival crevicular blood samples were collected on special blood collection cards and analysed for HbA1c levels in a laboratory	55% = pre-diabetes 17% = potential diabetic
Borrell and colleagues ³⁰	2007	4,830	Using a logistic regression model with a self-reported family history of diabetes, hypertension, high cholesterol and periodontal disease.	27-53% = potential diabetic
Beikler and colleagues ²³	2002	45	Statistical analysis was performed by Pearson's correlation coefficient comparing fingerstick blood and gingival crevicular blood.	Blood samples taken from gingiva and fingertip showed very high inpatient correlation
Li and colleagues ³¹	2011	7,545	Utilised Third National Health and Nutrition Examination Survey (NHANES III) (1988-1994) and a list of predictors.	Sensitivity of 82.4% Specificity of 52.8%
Lalla and colleagues ³²	2011	601	1. Self-reported risk factors 2. At least four teeth are missing 3. At least 26% of pockets have a depth of more than 5mm 4. Fingerstick point of care HbA1c of 5.7% or higher	30% = pre-diabetic 4% = diabetic Sensitivity of 92%

Association as the gold standard test for screening and diagnosing diabetes. RBG (normal <7.8mmol/L)²⁸ and HbA1c (normal <5.7% or <42mmol/mol) tests have been suggested for screening in the dental clinic as patients are not required to fast prior to their appointment.^{23,27} An RBG measurement of >7.8mmol/L and a HbA1c of >5.7% or >42mmol/mol warrant a referral to a general practitioner for further investigation.

Laboratory HbA1c testing of gingival crevicular blood yields the highest sensitivity and specificity results in correlation with fingerstick blood and would therefore seem to be the most appropriate measurement to use.²⁷ However, laboratory HbA1c testing would not be cost-effective and would be too time-consuming if carried out within a dental setting. Patients are more willing to let dentists

perform a screening test that yields immediate results and are less willing to have a screening test done if the samples have to be sent out to an outside laboratory.²⁰ Chair-side point-of-care HbA1c testing has the advantage of results that are strongly correlated with laboratory results being available within five minutes, without having to be sent to a laboratory.²⁹ Existing studies have only utilised gingival crevicular blood testing by means of a glucometer or have required samples to be sent to a laboratory on special collection cards for HbA1c analysis and as of yet no studies have investigated chair-side point-of-care HbA1c testing of gingival crevicular blood. The cost-effectiveness and simplicity of this concept means that there is a valuable opportunity to research this novel concept in the future.

The most recent evidence suggests that the screening models are effective (Table 2). The model proposed by Strauss and colleagues²⁷ using gingival crevicular blood measured via laboratory HbA1c testing identified 55% of patients as having pre-diabetes and 17% as being potentially diabetic. Several studies have used the National Health and Nutrition Examination Surveys (NHANES) (1988-1994 and 2003-2004) to develop a prediction model using self-reported data to screen for undiagnosed diabetes in a dental setting.^{9,30,31} These studies reported varying sensitivities. The model proposed by Li and colleagues³¹ yielded a sensitivity of 82%. The model proposed by Lalla and colleagues³² could predictably identify 92% of true cases, when: at least four teeth are missing; at least 26% of pockets have a depth of more than five millimetres; and, there is a HbA1c of 5.7% or higher. This pilot study identified 30% of patients as being pre-diabetic and 4% of patients as potentially diabetic.

Screening for diabetes mellitus in the dental office should only be carried out for high-risk patients in order for such screenings to be cost-effective. The American Diabetes Association has developed criteria that classifies high-risk patients as being anyone that:

- (1) is over 45 years of age;
- (2) has a family history of diabetes;
- (3) has a BMI ≥ 26 kg/m²;
- (4) does not exercise regularly;
- (5) has hypertension;
- (6) has hyperlipidaemia;
- (7) is of a certain racial or ethnic group (African American or Hispanic); and,
- (8) has had gestational diabetes.

The greater the number of risk factors a person has, the higher the risk they have for developing diabetes. With the aid of the above criteria, clinical judgement should be used to determine which patients are high risk and are therefore eligible for screening.

The landmark study by Lalla and colleagues³² utilised multivariate regression analysis to predict the most ideal screening parameters, and identified periodontal pocket depths (PPDs), tooth loss and point of care HbA1c testing as the suggested screening parameters. Although this study yielded a potentially novel screening approach, it had some noteworthy limitations. The study used PPDs instead of clinical attachment level (CAL) to measure the periodontal status, whereas CAL is preferred according to the definition of periodontitis

by the American Academy of Periodontology, and the authors did not use the American Diabetes Association criteria of self-reported risk factors to increase statistical sensitivity. The study also did not use point-of-care HbA1c gingival crevicular blood for a glucose measurement but instead used fingerstick HbA1c, which is not approved by the majority of US dental boards. It was recently reviewed in the *Journal of Evidence Based Dental Practice* and commentary illustrated that using this screening algorithm, 8% of true diabetic cases were not identified and consequently these people would have remained unrecognised, potentially resulting in serious complications.³³ However, false negatives of this nature may be overcome by subsequent screenings at future visits.⁵

Attitudes towards screening for medical conditions in a dental setting

A questionnaire-based study identified that the most critical element required for chair-side medical screening in a dental setting is acceptance by patients.²⁰ More than 90% of patients surveyed felt that it was important for dentists to screen for systemic diseases that they may otherwise be unaware of, and several recent studies found that diabetes screening in a dental office was well accepted by patients.^{15,21,28} Recent studies have also shown that the majority of dentists feel that it is important to screen for undiagnosed medical conditions in a dental setting^{21,34} and, moreover, dentists said they were willing to participate in such screening methods.³⁴

A potential barrier to such screening procedures is that patients may feel that their dentist is not adequately trained to carry out a medical screening but a questionnaire-based survey of 433 patients identified that screening of medical conditions by a dentist rather than a physician was the least important barrier.³⁴ Studies have found that more than 90% of dentists would refer patients to their general practitioner for further testing^{34,35} and almost 90% of dentists were willing to collect saliva for diagnostics as opposed to a 55% willingness to collect blood via fingerstick.³⁴ It would be interesting to see in future research what dentists' attitudes would be in terms of their willingness to carry out HbA1c gingival crevicular blood testing in the dental clinic. A major barrier is reimbursement. The current cost of a portable chair-side HbA1c machine (Bayer's A1CNOW+â SELF-CHECK) is approximately \$39.99 and fortunately in the United States this machine is reimbursable by the government. It is hoped that in the near future this would also be the case in Europe. This product is FDA approved, results are lab accurate, can be obtained in five minutes and only a small amount of blood is required.

In order for a screening strategy to be effective dentists must feel confident in their ability to carry out a screening efficiently. General dental practitioners (GDPs) were asked about their attitudes towards screening for diabetes in the dental clinic and the majority lacked confidence in their abilities to screen for diabetes.³⁵ To tackle this confidence barrier, training courses on how to screen for medical conditions in a dental setting should be introduced at an undergraduate level and as part of continued professional development (CPD) programmes. It has been shown that formal

training can enhance the dentists' confidence in assessing diabetes.³⁶

Discussion

Diabetes has become an epidemic and the incidence of diabetes is growing at an alarming rate. Expanding the role of the dentist may prove to be an efficient way of controlling this rapidly growing epidemic.

The cost-effectiveness of screening for undiagnosed diabetes in a medical setting has been well documented in the medical literature. The literature thus far concludes that screening for diabetes is only cost-effective and worthwhile in targeted high-risk groups.^{28,33} Studies have illustrated that screening for cardiovascular-associated events and hypertension can be carried out effectively in a dental setting. Therefore, screening for diabetes mellitus, targeted at high-risk individuals, and cardiovascular-associated events in one complete screening procedure should be considered.

Early detection of an undiagnosed systemic condition significantly improves the prognosis of the condition, improves the patient's quality of life and lessens the complications associated with the condition.⁵ It must be made clear that the dentist's role stops here. A reliable diagnosis of diabetes mellitus cannot be made by a glucometer and furthermore the dentist is not covered medico-legally to make such a diagnosis. The dentist has an obligation to refer a patient who tests positive to an appropriate medical service for formal diagnosis and management.

In 2007, the United States healthcare system spent \$174 billion on diabetes mellitus and \$465 billion in 2011.⁴ In 2011, the Irish Health Service spent approximately €4 billion on obesity and diabetes. The number of newly diagnosed cases of diabetes is increasing every year and the increases in healthcare costs are a reflection of this. Screening for undiagnosed diabetes mellitus could provide long-term healthcare savings, as less money would hopefully need to be spent on managing complications that could be avoided with early detection, referral and appropriate treatment.³⁴

Dentists have an ethical obligation and a duty of care to protect the well-being of their patients. A screening procedure to detect a serious, underlying, undiagnosed systemic condition, and that does not cause any harm to the patient, is in the patient's best interests.

Dentists are well placed to screen for systemic conditions because of the high annual attendance level and because dentists can carry out a gingival crevicular blood test. More importantly, dentists are more familiar with the mouth, and are therefore ideally placed to diagnose periodontal disease and other oral manifestations of diabetes that medical practitioners may not be as familiar with.

Conclusion

The recommendation of this review is to use a four-step screening approach combining:

- (1) The American Diabetes Association criteria for classifying high-risk patients;
- (2) the presence of periodontal disease defined by clinical attachment level;

- (3) the presence of oral features indicative of undiagnosed diabetes; and,
- (4) a chair-side point-of-care HbA1c gingival crevicular blood test to create the most ideal, cost-effective and user-friendly screening model.

Pending further research focused on trialling the above proposed screening model and pending approval from medical and dental councils, it is suggested that a universal clinical guideline to screen patients at dental visits for undiagnosed diabetes mellitus be developed, implemented and made a public health priority. Dentists are ideally suited to screen for signs and symptoms of undiagnosed diabetes through medical history taking and oral examination, and should refer any patients about whom they have concerns to their general medical practitioner for further testing.

Periodontitis is currently not included in the American Diabetes Association criteria for classifying high-risk patients. There may be a reasonable argument for including periodontal disease in the ADA criteria for classifying high-risk patients as recent research has confirmed the bidirectionality of periodontal disease and diabetes, and periodontal disease is the most common oral complication of undiagnosed diabetes.

Dentists certainly have an important role in identifying patients with undiagnosed diabetes mellitus and they may also play an important role in the management of this condition by aggressively treating periodontal disease, which may improve glycaemic control.^{35,36,37}

References

1. **Wilson, M.H., Fitzpatrick, J.J., McArdle, N.S., Stassen, L.F.** Diabetes mellitus and its relevance to the practice of dentistry. *J Ir Dent Assoc* 2010; 56: 128-133.
2. **Yamaoka, K., Tango, T.** Efficacy of lifestyle education to prevent type 2 diabetes: a meta-analysis of randomised controlled trials. *Diabetes Care* 2005; 28: 2780-2786.
3. **International Diabetes Federation, 2012.** The Global Burden. Available from: <http://www.idf.org/diabetesatlas/5e/the-global-burden> [Accessed 14 November 2012].
4. **Engelgau, M.M., Narayan, K.M., Herman, W.H.** Screening for type 2 diabetes. *Diabetes Care* 2000; 23: 1563-1580.
5. **National Center for Health Statistics.** Health, United States, 2009 with Special Feature on Medical Technology. 2010: 345-346.
6. **Special Eurobarometer 330/Wave 72.3 – TNS Opinion & Social, 2010.** Oral Health Report. Available from: http://ec.europa.eu/public_opinion/archives/ebs/ebs_330_en.pdf [Accessed 31 August 2013].
7. **Loe, H.** Periodontal disease. The sixth complication of diabetes mellitus. *Diabetes Care* 1993; 16: 329-334.
8. **Lalla, E., Cheng, B., Lal, S., Tucker, S., Greenberg, E., et al.** Periodontal changes in children and adolescents with diabetes: a case-control study. *Diabetes Care* 2006; 29: 295-299.
9. **Strauss, S.M., Russel, S., Wheeler, A., Norman, R., Borrell, L.N., et al.** The dental office visit as a potential opportunity for diabetes screening: an analysis using NHANES 2003-2004 data. *J Public Health Dent* 2010; 70: 156-162.

10. Mealey, B.L., Oates, T.W. Diabetes mellitus and periodontal diseases. *J Periodontol* 2006; 77: 1289-1303.
11. Katz, J., Wallet, S., Cha, S. Periodontal disease and the oral-systemic connection: "is it all the RAGE?". *Quintessence Int* 2010; 41: 229-237.
12. Laskaris, G., Scully, C. *Periodontal Manifestations of Local and Systemic Diseases*. Springer, 2003: 273-274.
13. Lamey, P.J., Darwazah, A.M., Frier, B.M. Oral disorders associated with diabetes mellitus. *Diabet Med* 1992; 9: 410-416.
14. Gibson, J., Lamey, P.J., Lewis, M., Frier, B. Oral manifestations of previously undiagnosed non-insulin dependent diabetes. *J Oral Pathol Med* 1990; 19: 284-287.
15. Garton, B.J., Ford, P.J. Root caries and diabetes: risk assessing to improve oral and systemic health. *Aust Dent J* 2012; 57: 114-122.
16. Saini, R., Al-Maweri, S.A., Saini, D., Ismail, N.M., Ismail, A.R. Oral mucosal lesions in non oral habit diabetic patients and association of diabetes mellitus with oral precancerous lesions. *Diabetes Res Clin Pract* 2010; 89: 320-326.
17. Ujjal, M., Matos, O., Bibok, G., Somogyi, A., Szabo, G., et al. Diabetes and oral tumours in Hungary: epidemiological correlations. *Diabetes Care* 2004; 27: 770-774.
18. Kaomongkolgit, R. Oral lichenoid drug reaction associated with antihypertensive and hypoglycemic drugs. *J Drugs Dermatol* 2010; 9: 73-75.
19. Russotto, S.B. Asymptomatic parotid gland enlargement in diabetes mellitus. *Oral Surg Oral Med Oral Pathol* 1981; 52: 594-598.
20. Greenberg, B.L., Kantor, M.L., Jiang, S.S., Glick, M. Patients' attitudes toward screening for medical conditions in a dental setting. *J Public Health Dent* 2012; 72: 28-35.
21. Rosedale, M., Strauss, S. Diabetes screening at the periodontal visit: patient and provider experiences. *Int J Dent Hyg* 2012; 10: 250-258.
22. Parker, R.C., Rapley, J.W., Isley, W., Spencer, P., Killooy, W.J. Gingival crevicular blood for assessment of blood glucose in diabetic patients. *J Periodontol* 1993; 64: 666-672.
23. Beikler, T., Kuczek, A., Petersilka, G., Flemmig, T.F. In-dental-office screening for diabetes mellitus using gingival crevicular blood. *J Clin Periodontol* 2002; 29: 216-218.
24. Strauss, S.M., Wheeler, A.J., Russel, S.L., Brodsky, A., Davidson, R.M., et al. The potential use of gingival crevicular blood for measuring glucose to screen for diabetes: an examination based on characteristics of the blood collection site. *J Periodontol* 2009; 80: 907-914.
25. Khader, Y.S., Al-Zu'bi, B.N., Judeh, A., Rayyan, M. Screening for type 2 diabetes mellitus using gingival crevicular blood. *Int J Dent Hyg* 2006; 4: 179-182.
26. Suneetha, K., Rambabu, T. Gingival crevicular blood glucose assessment as a chairside test for diabetic patients with chronic periodontitis: a clinical study. *Indian J Endocrinol Metab* 2012; 16: 665-666.
27. Strauss, S.M., Tuthill, J., Singh, G., Rindskopf, D., Maggiore, J.A., et al. A novel intraoral diabetes screening approach in periodontal patients: results of pilot study. *J Periodontol* 2012; 83: 699-706.
28. Barasch, A., Stafford, M.M., Qvist, V., Palmore, R., Gesko, D., et al. Random blood glucose testing in dental practice: a community-based feasibility study from The Dental Practice-Based Research Network. *J Am Dent Assoc* 2012; 143: 262-269.
29. Arrendale, J.R., Cherian, S.E., Zineh, I., Chirico, M.J., Taylor, J.R. Assessment of glycosylated haemoglobin using A1CNow+ point-of-care device as compared to central laboratory testing. *J Diabetes Sci Technol* 2008; 2: 822-827.
30. Borrell, L.N., Kunzel, C., Lamster, I., Lalla, E. Diabetes in the dental office: using NHANES III to estimate the probability of undiagnosed disease. *J Periodontol Res* 2007; 42: 559-565.
31. Li, S., Williams, P.L., Douglass, C.W. Development of a clinical guideline to predict undiagnosed diabetes in dental patients. *J Am Dent Assoc* 2011; 142: 28-37.
32. Lalla, E., Kunzel, C., Burkett, S., Cheng, B., Lamster, I.B. Identification of unrecognised diabetes and pre-diabetes in a dental setting. *J Dent Res* 2011; 90: 855-860.
33. Dye, B.A., Genco, R.J. Tooth loss, pocket depth and HbA1c information collected in a dental care setting may improve the identification of undiagnosed diabetes. *J Evid Based Dent Pract* 2012; 12: 99-102.
34. Chatterjee, R., Narayan, K.M., Lipscomb, J., Phillips, L.S. Screening adults for pre-diabetes and diabetes may be cost-saving. *Diabetes Care* 2010; 33: 1484-1490.
35. Kunzel, C., Lalla, E., Albert, D.A., Yin, H., Lamster, I.B. On the primary care frontlines: the role of the general practitioner in smoking-cessation activities and diabetes management. *J Am Dent Assoc* 2005; 136: 1144-1153.
36. Simpson, T.C., Needleman, I., Wild, S.H., Moles, D.R., Mills, E.J. Treatment of periodontal disease for glycaemic control in people with diabetes. *Cochrane Database Syst Rev* 2010; 5: 1-65.
37. Sultan, A., Patel, F. Treatment of periodontal disease improves glycaemic control in type 1 and type 2 diabetes: a literature review. *Trinity Student Medical Journal* 2012; 13: 52-56.

Water fluoridation, dentition status and bone health of older people in Ireland

O'Sullivan, V., O'Connell, B.C.

Objective: To examine some of the potential benefits and risks of water fluoridation for older adults.

Methods: This study used The Irish Longitudinal Study on Ageing to access a nationally representative sample of 4,977 people aged 50 and older. The sample was used to estimate associations between the percentage of households in a respondent's local area with a currently fluoridated water supply and the probability of two binary outcomes: the respondent having all their own teeth; and, having normal bone density. Past exposure of individuals to fluoridated water was not assessed; the prevalence of fluoridated water in local supplies was obtained from the 2006 Census of Ireland. The Census data indicated that there was considerable variation in the proportion of households with fluoridated water supplies, especially in rural areas. Bone mineral density was estimated from a heel ultrasound of each respondent, and their number of teeth was self-reported. A range of individual variables, such as educational attainment, housing, wealth, age and health behaviours, was controlled for.

Results: It was found that the greater the percentage of households with a fluoridated water supply in an area, the higher the probability that respondents had all their own teeth. There was no significant relationship between the proportion of households with a fluoridated water supply in an area and bone health.

Conclusion: This study suggests that water fluoridation provides a net health gain for older Irish adults, although the effects of fluoridation warrant further investigation.

Community Dent Oral Epidemiol 2014; Oct 20. [Epub ahead of print.]

Does residual cement around implant-supported restorations cause peri-implant disease? A retrospective case analysis

Linkevicius, T., Puisys, A., Vindasiute, E., Linkeviciene, L., Apse, P.

Objectives: The purpose of this study was to determine the relationship between patients with a history of periodontitis and development of cement-related peri-implant disease.

Materials and methods: Seventy-seven patients with 129 implants for this retrospective analysis were selected from completed implant cases that were scheduled for regular maintenance or had experienced mechanical or biological complications between 2006 and 2011 in private practice. Implants with extracoronary residual

cement and implants without cement remnants were analysed. The selected cases were further divided into two groups – implants in patients with a history of periodontitis (1) and implants in periodontitis-free individuals (2). The selection of these groups was made on the basis of treatment history and orthopantomograph. As a control group, a set of 238 screw-retained implant restorations, delivered to 66 patients during the same period of time, was examined. The incidence of peri-implant disease among implants in all groups was calculated.

Results: Peri-implant disease was evident in 62 of 73 implants with cement remnants (85%). All implants in group 1 developed peri-implantitis – four early and 35 delayed disease cases. In the periodontally healthy group, 20 of 31 implants were diagnosed with peri-implant mucositis, three had early peri-implantitis, and 11 implants with cement remnants did not develop biological complications. In the group of implants without cement remnants, peri-implant disease was diagnosed in 17 of 56 cases (30%). In contrast, only two occurrences of peri-implant disease were registered in the control group of screw-retained restorations (1.08%).

Conclusions: Implants with cement remnants in patients with a history of periodontitis may be more likely to develop peri-implantitis, compared with patients without a history of periodontal infection.

Clin Oral Implants Res 2013; 24 (11): 1179-1184.

Risk factors associated with the longevity of multi-rooted teeth. Long-term outcomes after active and supportive periodontal therapy

Salvi, G.E., Mischler, D.C., Schmidlin, K., Matuliene, G., Pietursson, B.E., Brägger, U., et al.

Aim. To investigate risk factors for the loss of multi-rooted teeth (MRT) in subjects treated for periodontitis and enrolled in supportive periodontal therapy (SPT).

Material and methods: A total of 172 subjects were examined before (T0) and after (T1) active periodontal therapy (APT) and following a mean of 11.5±5.2 (SD) years of SPT (T2). The association of risk factors with loss of MRT was analysed with multilevel logistic regression. The tooth was the unit of analysis.

Results: Furcation involvement (FI) = 1 before APT was not a risk factor for tooth loss compared with FI = 0 (p=0.37). Between T0 and T2, MRT with FI = 2 (OR: 2.92, 95% CI: 1.68, 5.06, p=0.0001) and FI = 3 (OR: 6.85, 95% CI: 3.40, 13.83, p<0.0001) were at a significantly higher risk to be lost compared with those with FI = 0. During SPT, smokers lost significantly more MRT compared with non-smokers (OR:

2.37, 95% CI: 1.05, 5.35, $p=0.04$). Non-smoking and compliant subjects with FI = 0/1 at T1 lost significantly less MRT during SPT compared with non-compliant smokers with FI = 2 (OR: 10.11, 95% CI: 2.91, 35.11, $p<0.0001$) and FI = 3 (OR: 17.18, 95% CI: 4.98, 59.28, $p<0.0001$), respectively.

Conclusions: FI = 1 was not a risk factor for tooth loss compared with FI = 0. FI = 2/3, smoking and lack of compliance with regular SPT represented risk factors for the loss of MRT in subjects treated for periodontitis.

J Clin Periodontol 2014; 41 (7): 701-707.

An *in vivo* comparison of internal bacterial colonisation in two dental implant systems: identification of a pathogenic reservoir

Mawhinney, J., Connolly, E., Claffey, N., Moran, G., Polyzois, I.

Abstract objectives. The aim of this study was to compare internal bacterial colonisation in two implant systems, one screw root form (SRF) with an external hexagon connection and one plateau root form (PRF) with a Morse taper internal connection.

Materials and methods. Thirty-two implants – 12 SRF and 20 PRF – were sampled in 15 patients. All implants had been in function for at least six months prior to sampling. The implant restoration was removed and 10 μ l of sterile saline was introduced into the implant well via a sterile glass syringe. The saline was drawn back up and transferred to the laboratory for microbiological analysis. The number of aerobic and anaerobic colony forming units per millilitre was determined and the dominant microorganism in each sample was identified by 16s rRNA gene amplicon sequencing.

Results. There was a significant difference between bleeding on probing around the SRF implants (3%) and the PRF implants (28%) ($p=0.0496$). Bacterial colonisation was identified at 11 SRF and 19 PRF implants. The numbers of anaerobic bacteria recovered from PRF implants was significantly higher than that from SRF implants ($p=0.0002$). *Streptococcus* species and *Enterococcus faecalis* were found to dominate.

Conclusions. This *in vivo* study demonstrated bacterial colonisation in both types of implant systems, irrespective of the type of connection. Significantly greater anaerobic counts were found in the Morse taper internal connection implants.

Acta Odontol Scand 2014; 11: 1-7. [Epub ahead of print]

Answers to Quiz (questions on page 274)

1. The long-term prognosis of this tooth is poor owing to the non-vitality of such an immature tooth and the likely sequelae of an avulsion injury.
2. The most likely outcomes in this case include pulpal necrosis, infection-related resorption, ankylosis and eventual tooth loss. Root canal treatment was initially avoided in this case as there was a possibility of pulpal regeneration due to the immature root development. Indications where it is appropriate to see if pulpal healing by regeneration will occur are:
 - the tooth is immature (prior to the development of a complete root length with half or more apical closure) and where pulpal extirpation will leave a weakened root at increased risk of a late stage coronal fracture; and,
 - there is a chance of cemental/PDL healing of the periodontal membrane (extra-oral time of less than 30 minutes' dry time and less than 90 minutes' total extra alveolar time when stored in an appropriate storage medium).

For immature teeth meeting this criteria, no endodontic treatment is undertaken and the tooth is carefully monitored to assess pulpal regeneration or pulpal necrosis. In this presented

case, pulpal necrosis ensued rapidly and endodontic treatment was commenced.

Due to the likelihood of replacement root resorption and eventual tooth loss patients should be referred to a specialist inter-disciplinary team for long-term treatment planning. Even in situations where favourable healing occurs by cemental/PDL healing, this early appointment is important to ensure the child and parents are fully aware of the possible outcomes and treatment options.

It must be emphasised that while the prognosis of the tooth is poor, the priority should be to maintain the tooth as long as possible to maintain dental arch space, dental arch symmetry, and alveolar bone contour, and minimise the psychosocial impact of the injury to the child. Long-term treatment options following planned loss of this tooth include: implant placement; fixed partial denture; auto-transplantation; or, orthodontic space close with restorative camouflage.

For further resources see:

- <http://www.dentaltraumaguide.org> – International Association of Dental Traumatology
- <http://www.bspd.co.uk/UK> – National Guidelines in Paediatric Dentistry – Treatment of Avulsed Permanent Teeth in Children

I didn't expect that!

DAVID CROSER presents a case study from Dental Protection's archives, which carries invaluable learning points.



A middle-aged female patient had badly imbricated lower incisor teeth. She was attracted by the practice website of a dentist who stated that he could create dazzling smiles. The website contained many before and after treatment photos and they looked pretty impressive.

After an initial consultation, various options were outlined to the patient, ranging from orthodontic treatment to crowns. The costs and time scales associated with each approach to treatment were also discussed.

The patient had considered orthodontics in the past and ruled that out as a possibility because she had a busy social life and she was really looking for a quick fix. She said that once she had made her mind up to do something she wanted to get on with it. She had been particularly impressed by the photos on the website and was even more impressed when the dentist showed her more of the same. She pointed out that one of the website photos of completed treatment showed exactly the result she was looking for.

She was keen to start her treatment and chose to have her four lower incisor teeth crowned. Such was her enthusiasm that the dentist even juggled some appointments so that her treatment could be accommodated as soon as possible.

On fitting the crowns the patient was not at all pleased. Indeed she was clearly dissatisfied. Although the buccal aspects of the teeth were now aligned, any view from above the incisal edges would reveal a strikingly excessive lingual to buccal width of the two teeth, which had previously been in-standing. The patient, who was rather short in stature, was particularly upset by this increase in the width of the incisal tip. She felt that people already looked down on her and her crowns would now be the focus of their attention.

Not only did the patient refuse to pay for the crowns, she also threatened legal action. On investigating the background to the case,

it transpired that the driver for her agreeing to the treatment was the before and after photos. However, none of those had included cases similar to hers where the treatment was only achievable by using crowns with an increased buccal to lingual width. Significantly, there had been no discussion of this fact in the pre-treatment consultation between dentist and patient.

An expert opinion was sought, which stated that, given the original position of the teeth, the only possible way to create a series of crowns with the appearance of well-aligned teeth of normal dimensions would involve devitalising the teeth prior to the use of posts and cores.

This option had not been considered or discussed with the patient and as a result the consent process was flawed and the dentist was vulnerable to a successful claim. Dental Protection assisted the dentist to achieve an amicable settlement with the patient without the involvement of solicitors.

Learning points

- Spend time with each patient to ensure that their expectations are properly understood and managed; confirm what can and – perhaps more importantly – what cannot be achieved.
- When using before and after photos to illustrate what can be achieved, be careful to explain any circumstances that might complicate the outcome for the particular patient in front of you.
- The use of computer-generated images is not without risk because such images can sometimes suggest outcomes that cannot be achieved in reality.
- The old adage of 'under promise and over deliver' still holds true in dentistry.

David Croser is Communications Manager at Dental Protection.

Classified advert procedure

Please read these instructions prior to sending an advertisement. Below are the charges for placing an advertisement for both members and non-members. Advertisements will only be accepted in writing via fax (01- 295 0092), letter or email (fionnuala@irishdentalassoc.ie). Non-members must pre-pay for advertisements, which must arrive no later than January 9, 2015, by cheque made payable to the Irish Dental Association. If a box number is required, please indicate this at the end of the ad (replies to box number X). Classified ads placed in the *Journal* are also published on our website www.dentist.ie for 12 weeks.

Advert size	Members	Non-members
up to 25 words	€75	€150
26 to 40 words	€90	€180

Non-members must send in a cheque in advance with their advert. The maximum number of words for classified ads is 40.

Only if the advert is in excess of 40 words, then please contact: Think Media

The Malthouse, 537 North Circular Road, Dublin 1.

Tel: 01-856 1166 Fax: 01-856 1169 Email: paul@thinkmedia.ie

Please note that all classified adverts MUST come under one of the following headings:

- ▶ Positions Wanted
- ▶ Positions Vacant
- ▶ Practices for Sale/To Let
- ▶ Practices Wanted
- ▶ Unwanted/Second Hand Equipment for Sale

Classified adverts must not be of a commercial nature. All commercial adverts must be display advertisements, and these can be arranged by contacting Paul O'Grady at Think Media, Tel: 01 856 1166.

POSITIONS WANTED

Very experienced locum Irish dentist (TCD graduate) available till the end of January 2015. All areas in the west/east/south, part/full-time, week holiday cover considered once busy book guaranteed. Please reply to locumdentist1@gmail.com.

Experienced dental hygienist available for work in the south west of Ireland. Registered and indemnified. Suitable for maternity leave, sick cover, etc. Replies to Tel: 087-109 0324, or Email: rosco1@eircom.net.

Dental hygienist available on short notice. Currently based in the west of Ireland. Registered and indemnified. Suitable for sick cover, emergencies, etc. Willing to travel. Tel: 085-154 0455, or Email: barygillp@gmail.com.

POSITIONS VACANT

Caring, friendly general dental practice welcomes part-time associate. Saturdays, and one other weekday available to a caring dentist with experience. Situated in a commuter town 30 minutes north of Galway. Associate may have opportunity to extend days. Email: dentalsurgery111@yahoo.ie.

Caring, friendly, part-time associate required for busy modern family practice on Dublin's northside. Fully computerised, digital x-rays. Interest in endodontics and oral surgery an advantage. Minimum of two years' experience. Please email CV to chris.ohanlon@hotmail.com.

Associate required – Midlands, Co. Galway. Ambitious, dynamic, flexible and experienced associate required. Immediate start. Employee/self-employed status. Busy, modern practice. Well equipped, computerised. Knowledgeable, supportive staff. Excellent figures. Flexibility for the most suitable candidate. Tel: 086-807 5273, or Email: niall@innovatedental.com.

Dental associate required part-time, very flexible hours in a modern, well-

established surgery in South West Dublin. Please forward CVs to wmunroe@eircom.net.

Experienced associate dentist required in Galway City in modern, well-equipped computerised practice. This is an opportunity for a dentist to become established, with a possible long-term view. Please submit applications to reception@galwaydentist.com.

Experienced associate required. Ravat & Ray are opening in Douglas, Isle of Man, a proactive, forward-thinking organisation keen to progress the oral health agenda via the delivery of UDAs and a range of promotions/outreach programmes. Log on to www.ravatandray.com, or Email: mandy.bishop@nhs.net.

Cork City. Associate required to cover maternity leave part-time from the middle of November. CV to corkcityassociate@gmail.com.

Associate required Galway City, Gate Clinic. Cerec 3D, hygienists, digital x-rays, I-Cat scanner, intra-oral microscope. Good potential, motivated patients, wonderful support staff. Part-time initially, working up to full-time. Please forward CV to drpmoore@mac.com.

Associate required – Dublin North. Ambitious flexible associate required. Needs clear view to full integration, purchase. Employee/self-employed status. Busy modern practice. superb location. Excellently equipped. Ample opportunity to grow. Knowledgeable staff. Low overheads. December/January start. Tel: 086-807 5273, or Email: niall@innovatedental.com.

Associate required – Dublin. Ambitious flexible associate required. Busy practice with top-class facilities. Excellently equipped. Fully computerised. Knowledgeable staff and strong support system. Employee/self-employed status. Excellent profits. Start January 2015. Experience essential. Email: surgeriesavailable@yahoo.ie.

- Full-time associate required for Eyre Square Dental, Galway City, to replace departing colleague. Excellent opportunity for an enthusiastic and dedicated candidate. Modern facilities and experienced support staff. Applications in the form of CV and cover letter to paula@eyresquaredental.ie.
- Part-time dental associate wanted for a busy practice in Ennis. Please reply to gbrowne.ennis@eircom.net.
- Part-time associate, Galway City. Must be warm, friendly, outgoing with great people skills. Interest in advanced restorative dentistry an advantage. Email: galwayassociate1@gmail.com in confidence.
- Associate dentist required for four days per week in Dublin south city practice. Minimum three years' experience. Email CV to newdentistwanted@gmail.com.
- Dental associate wanted for busy, modern Limerick City dental practice. Modern, fully-equipped surgery. Would suit new graduate. Email: info@no8.ie.
- Full-time experienced associate required for busy Dublin 3 practice. Replacing departing colleague for immediate start. Mixed private/medical card. Please email CV to northdublinassociate@eircom.net.
- Dental associate required to replace outgoing colleague for our dental practice in Ballinasloe, Co. Galway. Associate must be experienced. Full support staff available. We operate private, medical card and PPS schemes. Please reply by email to rothwellauct@eircom.net.
- Dentist required for surgery in west side of Cork City with a view to full-time. Must have a special interest in some aspect of dentistry. Replies to Box No. 911.
- Dublin – exciting opportunity for a strong, enthusiastic general dentist to join our busy Smiles O'Connell Street practice in Dublin 1. Full-time basis five days per week. Candidates must have strong general private and public experience and be IDC registered. Email: recruitment@smiles.co.uk.
- Dundalk – Smiles Dental is looking for an enthusiastic, passionate dentist to join our well-established Smiles Dundalk dental practice. Candidates must have strong general private and public experience and be IDC registered. Working days required are three to four days per week. Email: recruitment@smiles.co.uk.
- Drogheda – Smiles Dental is looking for an enthusiastic, passionate dentist to join our well-established Smiles Drogheda dental practice. Candidates must have strong general private and public experience and be IDC registered. The working days required are five days per week. Email: recruitment@smiles.co.uk.
- Clonsaugh – Smiles Dental is looking for an enthusiastic, passionate dentist to join our well-established Smiles Clonsaugh dental practice in Dublin 17. Candidates must have strong general private and public experience and be IDC registered. Part-time position available. Email: recruitment@smiles.co.uk.
- Tallaght – Smiles Tallaght dental practice in Dublin 24 is looking for an experienced general private and public dentist to join the team on a full-time basis, Monday to Friday and bi-weekly Saturday. Candidates must be IDC registered. Email: recruitment@smiles.co.uk.
- Dublin – Smiles Dental is looking for a passionate dentist to join our well-established, busy Smiles South Anne Street dental practice in Dublin 2. Must have strong general private and public experience and be IDC registered. Five days per week. Email: recruitment@smiles.co.uk.
- Waterford – Smiles Dental is looking for an enthusiastic, passionate dentist to join our well-established Smiles Waterford dental practice. Candidates must have strong general private and public experience and be IDC registered. The working days required are five days per week. Email: recruitment@smiles.co.uk.
- Busy practice in Cork City looking for a warm and friendly, outgoing dentist with great people skills and prosthetics experience full/part-time. Modern five surgeries, all digital. Immediate start/long-term view. Email CV with photo to hr@smilestore.ie.
- Enthusiastic dentist required for a bright, new, modern, busy practice in Carlow Town. Part-time but real scope to increase days. Fun working environment, top notch staff and equipment. Please Email: cazzakeogh@gmail.com.
- Dental surgeon required for state-of-the-art clinic in Dublin. 2.5 years' general practice experience required. Immediate start. Please email CV to carol.moroney@redmondmolloy.ie.
- Locum position available February to August 2015 in Limerick City Centre. Replies to Fiana at cornmarketdental@eircom.net.
- Full-time locum position available for experienced, friendly dentist. Position to cover maternity leave from early February in Galway commuter town. Email: dentalsurgery111@yahoo.ie.
- Endodontist required for busy Dublin specialist practice. Enquiries to endodontistrequired@gmail.com.
- Orthodontist wanted to join superb, busy Dundalk specialist orthodontic practice. Contact Hugh, Tel: 086-838 3483, or Email: hughbradley@gmail.com.
- Excellent opportunity for an orthodontist to join south Dublin clinic, multi-surgery practice, state-of-the-art, modern equipment, OPG, etc. Please send CVs to support@deansgrangedental.ie.
- Part-time orthodontist required to replace retiring colleague who is finishing treatments. Long-established south Dublin family practice. New patient waiting list! Reply to info@dentalclinic.ie.
- Dental technician required to work on site, part-time in a busy Cork City practice. Opportunity to design new denture lab from scratch in an excellent working environment. CVs to corkcityassociate@gmail.com.
- Hygienist required in Co. Meath for immediate cover, Wednesday, Thursday and Saturday. Please send CV to surgerydental24@gmail.com.
- Hygienist required, initially one day per week, Dublin 6. Start November. Please send cover letter and CV to: dublinsouthdentist@gmail.com.
- Hygienist required for busy Westmeath practice, 1.5 days a week Friday/Saturday. Needed to cover maternity leave. Immediate start. To apply, please send CV and cover letter to info@kinnegaddental.ie.
- Locum dental hygienist required, one day per week, general practice in Drogheda, to cover sick leave and maternity leave, immediate start. Experience desirable. Apply with CV to info@angelakearney.ie.
- Dental hygienist required for immediate start in Greystones, two days per week. Please send CV and cover letter to reception@roseairdental.ie.
- Hygienist required for Tuesday and Thursday, 2.30pm to 8.00pm, to replace departing colleague. To start December 9. Great terms. Email: hello@phoenixdental.ie.
- Northern Cross Dental is a busy, friendly specialist dental practice that requires an experienced, motivated dental nurse to join our team. Email: mags@ncdental.ie.

Dental nurse required for part-time maternity cover to start mid October. Experience essential. Tel: 042-933 7033, or Email: care@dublinstreetdental.ie.

Experienced dental nurse required for general practice in Rathcoole. Immediate start. Please send CV to info@rathcooledental.ie.

Fully qualified, friendly nurse required for expanding practice in Blackrock. Immediate part-time. Full-time after Christmas. Must be flexible including some evenings. Email: dentistblackrock@gmail.com.

Mixed general/specialist practice looking for qualified dental nurse for maternity leave. Possible immediate start. Please forward CV if interested to info@berkeleydentalcentre.ie.

Practice manager required – Dublin/Leinster. Highly experienced, capable, self-motivated. Dynamic, ambitious, personality. Fully computer literate. Knowledge of modern clinical risk management. Excellent interpersonal and HR skills, a must. Own car and flexibility crucial. Superb remuneration. Tel: 086-807 5273, or Email: niall@innovatedental.com.

PRACTICES FOR SALE/TO LET

Practice/property for sale. 40 mins Dublin. Long-established, computerised, OPG, hygienist, visiting implantologist. Owner retiring. Rental income from property. Email: practice.property@gmail.com.

Freehold dental practice for sale, with two modern dental surgeries. Good value. Tel: 086-104 2828.

Practice for sale. West of Ireland. Busy, long-established, modern, fully equipped, walkable two-surgery practice. Digitalised. Hygienist. Excellent loyal staff. Strong profits. Huge potential for growth, area wide open. Price negotiable, speedy sale. Suit ambitious personality. Tel: 086-807 5273, or Email: niall@innovatedental.com.

For sale – south Dublin. Long-established practice in an affluent location beside busy town. Flexible options; leasehold property. Very low overheads. On site parking. Potential to expand. No medical card. Good profits. Very competitively priced – dentist retiring. Tel: 086-807 5273, or Email: niall@innovatedental.com.

Excellent opportunity for dental specialist to rent room in general dentistry practice in Blackrock Clinic. Would suit orthodontist, endodontist, periodontist, maxillofacial surgeon or other. Email: rfehily@hotmail.com.

For sale – South Dublin. City Centre 10km. Practice in well-established

residential area. Walkable, well-maintained, apartment included in the sale. Two surgeries. Fully private – ripe for expansion. Realistic practice price. Dentist retiring. Tel: 086-807 5273, or Email: niall@innovatedental.com.

For sale – Dublin 9. Long-established practice with residential accommodation. Three fully equipped modern surgeries, OPG, office, waiting room, tea room. Private only. Full planning permission. Excellent decorative order. Good location. Potential for expansion. Parking at rear. Replies to Box No. 969.

Orthodontic practice for sale – south Dublin. Excellent orthodontic practice. Superb opportunity. Long-established. Two surgeries. Expansion possible. Flexible purchase options – goodwill only available to purchase. Fully computerised. Tel: 086-807 5273, or Email: niall@innovatedental.com.

For sale, endodontist retiring, entire building available extending to c.135 sq m. Two fully-equipped surgeries, spacious office/reception area, customer toilet. Upstairs suits a variety of uses. Sale with/without equipment. Ample parking, six to seven spaces. Immediate sale. Clonskeagh area. Email: barry@eddempsey.ie.

EQUIPMENT FOR SALE

For sale. Lisa 500 autoclave – cycle count 3362. Full working order, new door seal, water separator fitted. For collection, D7. €1,500. Please email for photos/questions. Email: onemanorplace@eircom.net.

Equipment for sale – Dublin. For sale as one package – full surgery equipment/instruments. Chair, compressor, suction motor, licensed intra-oral x-ray, HealOzone. Reasonable offer secures. Can be viewed in operation. Available December 2014. Tel: 086-807 5273, or Email: niall@innovatedental.com.

Equipment for sale. Dental chair, x-ray machine, generator and pump. Equipment is based in premises in Loughrea, Co. Galway. Tel: 091-872111, or Email: michael@michaelfdolan.ie.

PREMISES WANTED

Premises required. South Dublin. Modern, bright facility. Easily accessible. Planning permission – medical/dental. Busy area with parking available. Minimum 1,000 sq ft. Existing premises/shopping centre unit, all areas considered. Flexible lease options. Everything confidential. Tel: 086-807 5273, or Email: niall@innovatedental.com.

Diary of events

JANUARY 2015

Dental Protection Horizons Workshop

Tuesday 13 *Hilton Hotel Charlemont, Dublin*

Munster Branch IDA meeting

Wednesday 14 *Maryborough House Hotel, Cork*

IDA MEMBERS ONLY

Dental Protection Horizons Workshop

Thursday 22 *Maryborough Hotel, Cork*

Dental Protection Horizons Workshop

Wednesday 28 *Harbour Hotel, Galway*

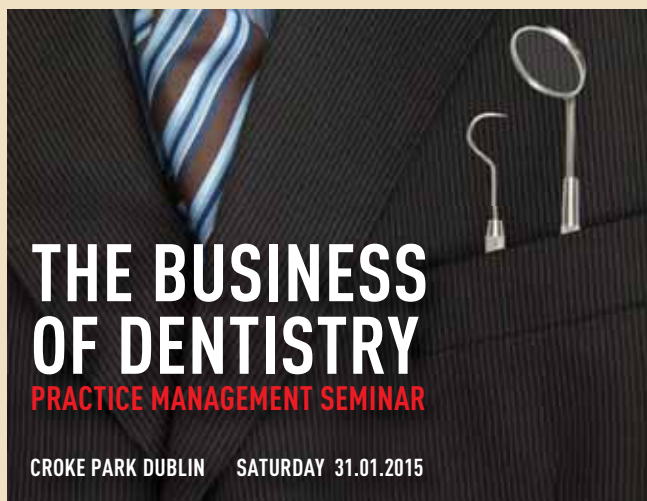Metropolitan Branch Meeting

Thursday 29 *Hilton Hotel, Dublin*

IDA MEMBERS ONLY

Practice Management Seminar

Saturday 31 *Croke Park, Dublin*



FEBRUARY

Southern Cross Dental Practical Day

Saturday 7 *Dublin Dental Hospital*
Guide to Direct and Indirect Restorations in the Aesthetic Zone, presented by Dr Subir Banerji. Log on to <https://www.scdlab.com/ir/> event for details.

Metropolitan Branch Meeting

Thursday 12 *Alexander Hotel, Dublin 2*

IDA MEMBERS ONLY

Southeastern Branch – Annual Scientific Meeting and AGM

Friday 20 *Faithlegg House Hotel, Waterford*

IDA MEMBERS ONLY

MARCH

Irish Society for Disability and Oral Health – Spring Evening Meeting

Thursday 5 *DDUH*
Theme: 'We're older but are we wiser? Ageing and its implications for general and special care dentistry in Ireland'
Log on to www.isdh.ie for further details.

Metropolitan Branch Annual Scientific Meeting

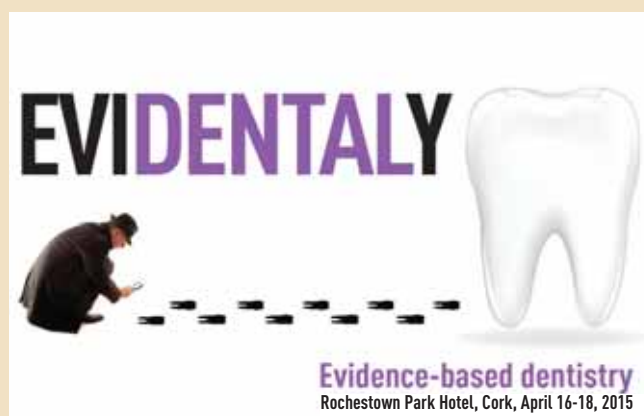
Friday and Saturday 6-7 *Alexander Hotel, Dublin 2*



APRIL

IDA Annual Scientific Conference 2015

Thursday to Saturday 16-18 *Rochestown Park Hotel, Cork*
Please see Conference Brochure for further details.



NOVEMBER

Irish Society of Dentistry for Children –

Get Ready: dental and medical emergencies in children

Thursday 14 *Louis Fitzgerald Hotel, Dublin*

DeCare introduces new payment option for members

At DeCare Dental, we have been processing member claims in Ireland since 2004 and our priority is to make this process as fast and simple for our members as possible, while ensuring the security of their information.

We are now offering two flexible claiming options:

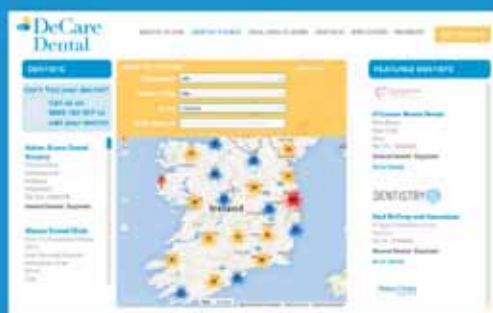Option 1: Direct Pay

- DeCare now offers a direct pay facility with participating dental practices.
- DeCare pays the dentist directly for the costs covered by the member's policy, meaning they have less out-of-pocket expense.
- Where this service is available, it is operated using advanced technology ensuring secure transmission of patient information.

Option 2: Pay and Claim

- Members can also attend any dentist listed on our Dental Directory, pay the dentist as normal and then claim back the costs covered by their policy.
- Claims are processed within ten working days and members can be assured of accurate claims assessment thanks to DeCare's expertise in this area.

Check your
details on
our Dental
Directory



DeCare Dental's Dental Directory is an online directory listing dentists throughout Ireland that are happy to provide our members with the relevant information they need for their claim form.

Queries?

Contact: Regina Brady

☎ 094 9372277 ✉ rbrady@decare.com

DeCare Dental Insurance Ireland Limited trading as DeCare Dental is regulated by the Central Bank of Ireland

Get in touch

T: 1890 130 017


E: query@decaredental.ie

W: www.decaredental.ie

new

1 COMPLETE SENSITIVITY TOOTHPASTE

SPECIALLY DESIGNED WITH 7 BENEFITS*



Powered by NovaMin®



*With twice daily brushing

SENSODYNE, NOVAMIN and the rings device are registered trade marks of the GlaxoSmithKline group of companies.

SENSODYNE®