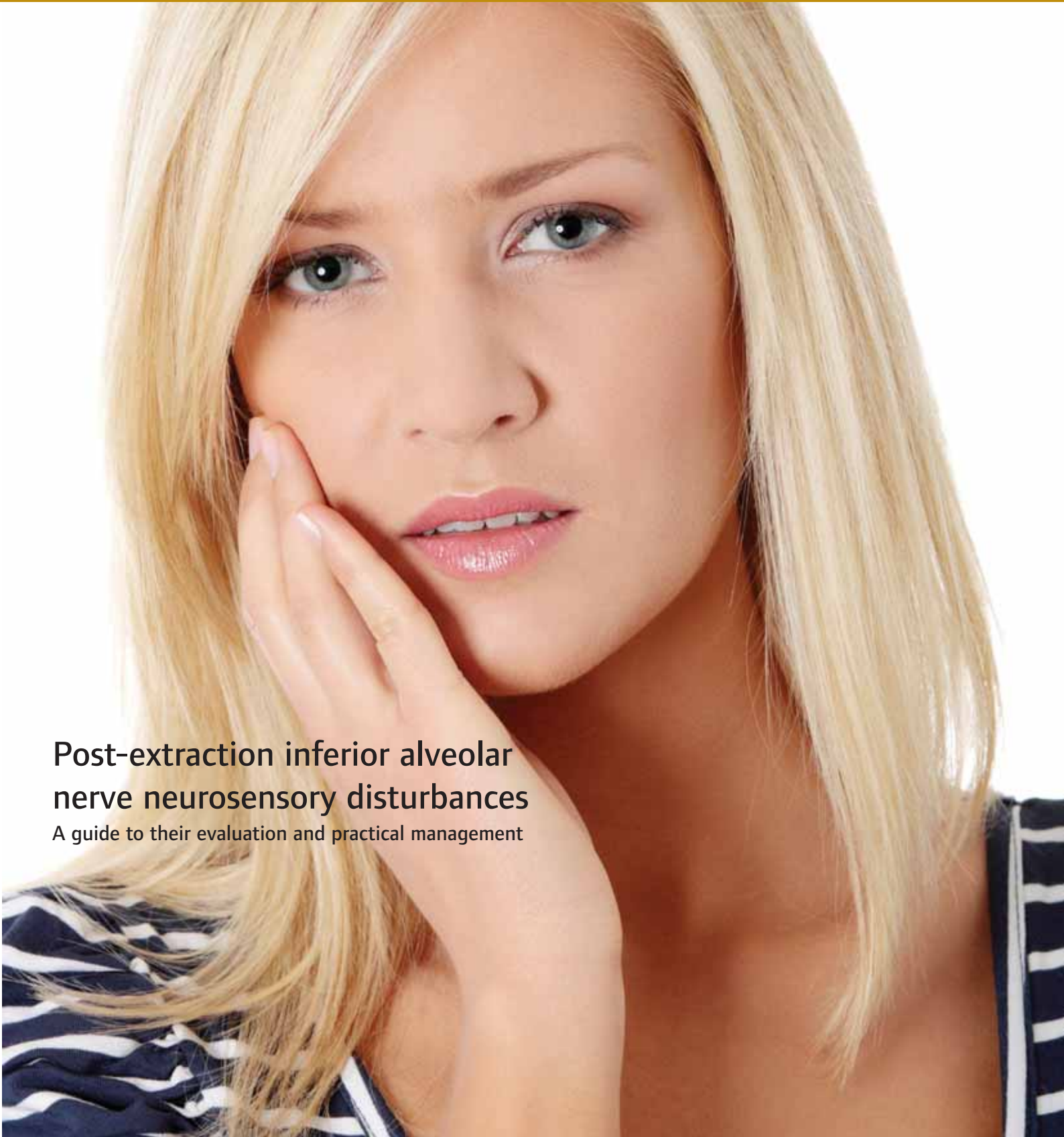


Volume 60 Number 5
October/November 2014


irish dental association

Journal of the Irish Dental Association

Iris Cumainn Déadach na hÉireann



Post-extraction inferior alveolar nerve neurosensory disturbances

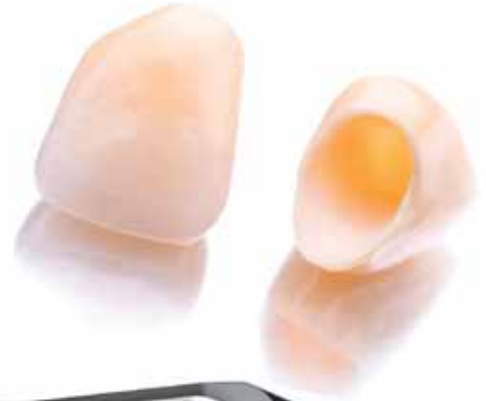A guide to their evaluation and practical management

ZIRCONIA

MILLED AND HANDCRAFTED TO PERFECTION

89.00 € Per unit

Special price for the month of October 2014



Try us once, Love us forever

TEETHRUS

TeethRus Ireland Limited.
Rose Cottage, Main Street/Adare, Co. Limerick
Phone: 061 395688/395689 infoirl@teethrus.us . www.teethrus.us

IDA PRESIDENT **Dr Peter Gannon**
 IDA CHIEF EXECUTIVE **Fintan Hourihan**
 JOURNAL CO-ORDINATOR **Fionnuala O'Brien**

EDITOR
Professor Leo F.A. Stassen
 FRCS(Ed), FDSRCS, MA, FTCD, FFSEM(UK) FFDRCSI

DEPUTY EDITOR
Dr Dermot Canavan
 BDentSc, MGDS(Edin), MS(UCalif)

EDITORIAL BOARD
Dr Iseult Bouarroudj BDS NUI
Dr Michael Crowe BSc BDentSc DPDS (Bristol)
Tina Gorman RDN, FAETC, Cert Conscious Sed.

Dr Mark Kelly BA BDentSc
Dr Christopher D. Lynch BDS PhD MFDRCISI
 FDS (RestDent)RCSI FACD FHEA

Donna Paton RDH
Dr Ioannis Polyzois
 DMD, PhD, MDentCh, MMedSc

Dr Ciara Scott
 BDS MFD MDentCh MOrth FFD (RCSI)

Dr Seamus Sharkey BDS NUI FRACDS (Syd)
 MFDSRCS DChDent (Prosthodontics) FFDRCSI

Dr Simon Wolstencroft
 BDS FDSRCS MScD MOrth FDSOrth

Dr Alastair Woods BA BDentSc

The *Journal of the Irish Dental Association* is the official publication of the Irish Dental Association. The opinions expressed in the Journal are, however, those of the authors and cannot be construed as reflecting the Association's views. The editor reserves the right to edit all copy submitted to the Journal. Publication of an advertisement does not necessarily imply that the IDA agrees with or supports the claims therein.

For advice to authors, please see:
www.dentist.ie/resources/jida/authors.jsp

Published on behalf of the IDA by
 Think Media, 537 NCR, Dublin 1

T: 01-856 1166
www.thinkmedia.ie

EDITORIAL
Ann-Marie Hardiman, Paul O'Grady

DESIGN AND LAYOUT
Tony Byrne, Tom Cullen, Ruth O'Sullivan

ADVERTISING
Paul O'Grady

DID YOU KNOW? IDA members can save thousands of Euro with our affinity deals

213 EDITORIAL
 Fluoride facts

215 PRESIDENT'S NEWS
 Collaboration and celebration

216 LETTER TO THE EDITOR

216 NEWS

222 QUIZ

226 IDENTEX
 IDA and IDTA join forces

230 CLINICAL FEATURE
 Delivering painless and effective inferior alveolar nerve block anaesthesia

233 IDA NEWS **MEMBERS ONLY**
 Dental School heads promote fluoridation
 Association meets Health Minister HR: Probationary periods

238 INTERVIEW
 Implants in Ireland – Prof. David Harris

241 PEER-REVIEWED
 Post-extraction inferior alveolar nerve neurosensory disturbances – A guide to their evaluation and practical management
N Mahon, LFA Stassen

252 ABSTRACTS

254 PRACTICE MANAGEMENT
 Best Practice – a vital new resource for Irish dentists

256 CLASSIFIED

258 DIARY OF EVENTS



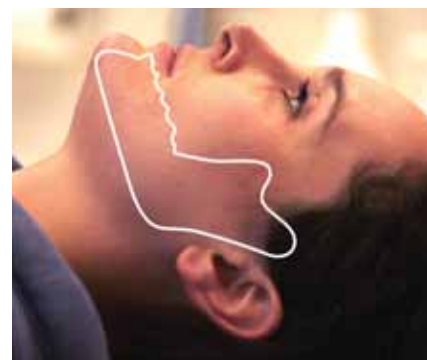Gala Ball 218

Sensodyne Sensitive Dentist of the Year 2014



Identex 226

IDA and IDTA join forces for trade and CPD



Clinical 230

Painless and effective anaesthesia

Irish Dental Association Unit 2 Leopardstown Office Park, Sandyford, Dublin 18.
 Tel: +353 1 295 0072 Fax: +353 1 295 0092 www.dentist.ie
 Follow us on Facebook (Irish Dental Association) and Twitter (IrishDentists).



Total average net circulation 01/01/13 to 31/12/13:
3,499 copies per issue. Circulated to all registered dentists in the Republic of Ireland and Northern Ireland.

Colgate®

INTRODUCING A BREAKTHROUGH IN EVERYDAY CAVITY PROTECTION

PROVEN BY 8 YEARS OF CLINICAL RESEARCH
INVOLVING 14,000 PEOPLE



**Sugar Acid
Neutraliser™
Technology**
powered by Arginine



Fluoride

Unique mode of action to
complement the power
of fluoride

- 4 x greater remineralisation¹
- Directly fights sugar acids
in plaque – the #1 cause
of cavities^{2,3}
- Up to 20% fewer new
cavities in 2 years^{4,5}

Fluoride



**Maximum
Cavity Protection**
plus SUGAR ACID NEUTRALISER™

¹versus a regular fluoride toothpaste with 1450 ppm fluoride.

References

1. Cantore R et al. *J Clin Dent*. 2013;24 (Spec Iss A):A32-A44. 2. Wolf M et al. *J Clin Dent*. 2013; 24 (Spec Iss A):A45-A54. 3. Santarpia P, Lavender S, Gitins E et al. Submitted for publication in *Am J Dent*. 2013. 4. Krasvophon P et al. *Caries Res* 2013;47:582-590. 5. Hu DY et al. Data on file. Colgate-Palmolive Company, 2013.

COLGATE. COMMITTED TO A CAVITY-FREE FUTURE

www.colgateprofessional.ie

Fluoride facts

Honorary Editor, PROFESSOR LEO F.A. STASSEN, regrets the implications of a vote by Dublin City Councillors and calls for the voice of science to be heard.

Just as we go to press comes the word that the members of Dublin City Council have passed a motion calling for fluoride or any derivative of it to be removed from the Irish water supply and to make it a crime for anyone to put it into the water supply. One online commentator on *TheJournal.ie* described it as a victory for ignorance over science. And while arguments should always be aired and issues debated in society, it is hard to disagree with the commentator's sentiment. Indeed, this vote is depressing on several levels.

First of all, it clearly identifies the fact that a majority of elected representatives in our capital city cannot distinguish between serious research and pseudo-research. Secondly, it demonstrates that even in 2014, scaremongering remains a viable tool to be used against evidence-based practice. Thirdly, perhaps the finest public health measure ever enacted by this State in its less than 100-year history (one which has protected the least well off disproportionately well) can be undermined by a combination of fear and political sophistry. The facts on fluoridation are simple. At the rate that it is applied to Irish drinking water: it provides a protective effect against dental caries, even when allowing for brushing with fluoride toothpaste; and, there is no harm done to any aspect of human health.

Fluoride is a proven and highly cost-effective way of protecting health and preventing pain. There is an onus on our politicians to acquaint themselves with these facts and protect the weak and poor in our society. There is also an onus on all leaders in our profession to speak out strongly against the pseudo-science masquerading as counter arguments to fluoridation. We need to hear those voices now.

CPD and the *Journal*

There is good news for the *Journal* in this issue. Readers will see in the news pages that the Dental Council has approved the award of two points of verifiable CPD for those dentists who review papers for publication in the *Journal*. We are most grateful to the Council for recognising the learning and contribution to professional development that is inherent in the act of reviewing a colleague's paper. The mechanism will be simple: we will write to the Dental Council to confirm that a dentist has reviewed a paper for publication and the Council will then award the points.

Implant dentistry in Ireland

Thirty years ago there was a significant development in dental science: osseointegrated implants offered solutions to problems that had challenged dentists for centuries. Previous experiences with attempts at dental implants had left the idea tarred with the whiff of the charlatan. The work of Professor Per-Ingvar Brånemark in Sweden was meticulously researched and to the highest standards of science. It took time, but dental implants became a treatment of choice in Ireland and elsewhere. The Irish dental profession was an early adopter and the Professor and his colleagues came to Ireland to demonstrate their work, resulting in honorary memberships in the Faculty of Dentistry of the Royal College of Surgeons in Ireland. The story is very well related by one of the pioneers, Professor David Harris, in his interview in this edition of the *Journal*.

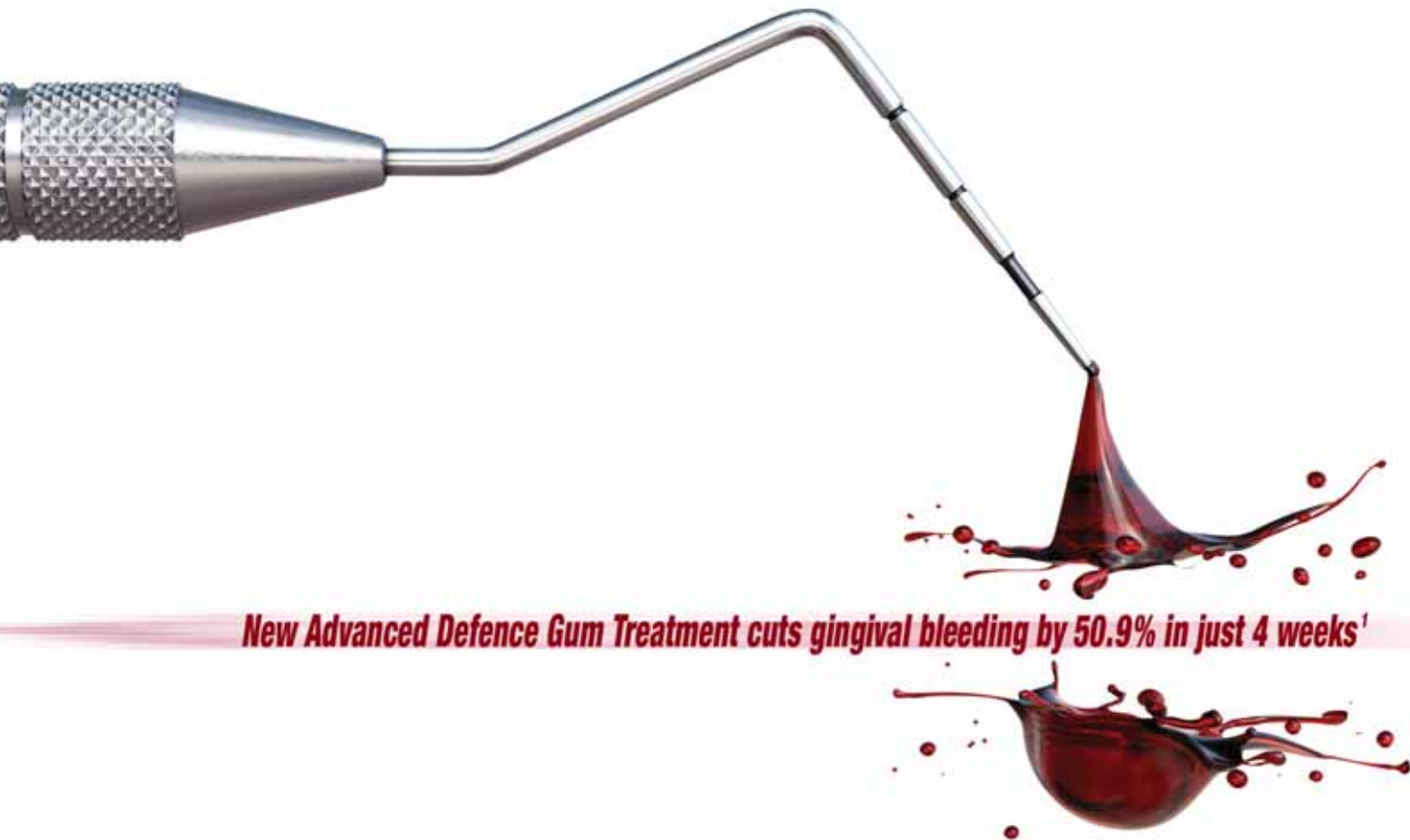Packed edition

As always, we receive far more contents for the *Journal* than we can accommodate – but we are always keen to receive material. In this edition, there is an excellent clinical feature from Dr Dermot Canavan, an excellent feature on the Best Practice content in the members' only section of the Irish Dental Association website, and a paper on post-extraction inferior alveolar nerve neurosensory disturbances from Dr Nicola Mahon. That is in addition to the usual news, views, abstracts and reports.



Prof. Leo F. A. Stassen
Honorary Editor

A handwritten signature in blue ink that reads "Leo F. A. Stassen".



New Advanced Defence Gum Treatment cuts gingival bleeding by 50.9% in just 4 weeks¹

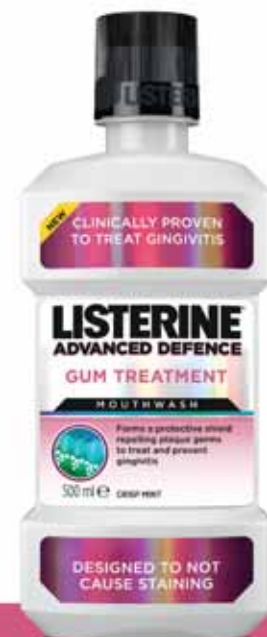Introducing the latest in the professional range from LISTERINE® – a twice-daily mouthwash **clinically proven to treat gum disease as an adjunct to mechanical cleaning.**

Advanced Defence Gum Treatment is an alternative to chlorhexidine-based remedies. It's formulated with unique LAE (Ethyl Lauroyl Arginate) technology that forms a physical coating on the pellicle to prevent bacteria attaching, and so interrupts biofilm formation.

When used after brushing it treats gum disease by reducing bleeding; 50.9% ($p < 0.001$) in only 4 weeks.¹

In addition, Advanced Defence Gum Treatment is **designed to not cause staining.**²

PART OF THE
LISTERINE[®]
ADVANCED DEFENCE RANGE



References:

1. Bleeding Index Reduction DOF 1 – 2013 (LAEBBA0001).
50.9% reduction in whole-mouth mean Bleeding Index at 4 weeks.
2. DOF 2 – 2013 (LUNKPLT0006).

NEC/LI/13-0240b

Advanced Defence against gum disease

Collaboration and celebration

Association President DR PETER GANNON has been busy representing members.

Meeting the Minister

Our meeting with the new Minister for Health, Dr Leo Varadkar, provided an opportunity to brief the Minister on the many difficulties facing our patients and the dental profession. With a strong delegation we explained that action is needed now rather than more plans or more delays. We stated very clearly the shortfalls in both dental schemes (DTBS and DTSS) for adults and outlined our requirements for any new scheme in the future. We repeated our calls for the restoration of the basic dental treatments cut from both schemes, needed by those with medical cards and earned by those qualified by their PRSI contributions. We spoke of the crisis in the public service, which has seen huge cuts in the numbers of dental staff available to care for young and very vulnerable patients. We stressed the need to return to a point, in the Public Dental Service and with the State dental schemes, where prevention was once again possible, rather than the current focus on emergency treatment and pain relief.

Our delegates from different branches of the profession worked in a united and cohesive way before and during the meeting. Our strength as a representative body reflects our willingness to stand together in advancing our shared interests.

Identex

This year saw the first collaboration between the Irish Dental Association and the Irish Dental Trade Association where we organised workshops at the recent Identex exhibition. It is important for dentists that there is a vibrant and competitive dental trade in Ireland. Individually we all have relationships with dental suppliers and service companies and they depend on us to survive and succeed. The IDA benefits from trade sponsorship at many events, in particular at our Annual Conference. This allows us to have a wide and varied education programme and allows the trade to interact with large numbers of dentists.

Sensitive Dentist Awards

These Awards are unique in Ireland in that the winners are nominated by their patients. There are inspiring stories each year where dentists have given outstanding care and attention to their patients. This year, we have decided to seek a higher profile and attention for this unique awards ceremony where the true spirit and ethos of the profession shines through. The Gala Dinner in the Royal Hospital, Kilmainham, promises to be a great evening and I believe some practices are planning to combine this with their annual Christmas party. I look forward to a great night for patients, the dental team and especially the dental profession.

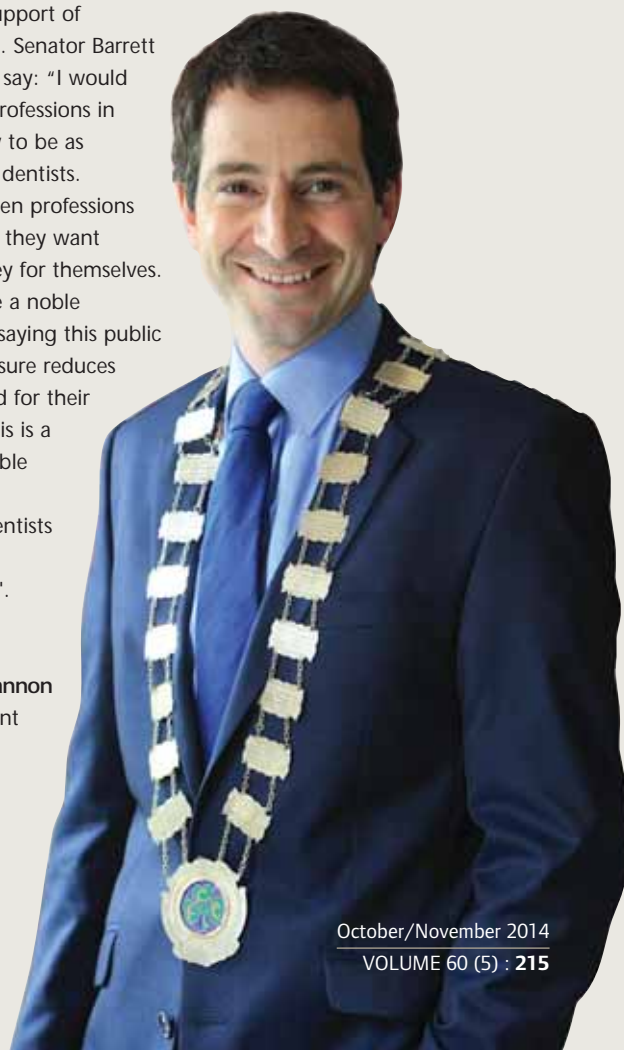Mouth Cancer awareness

Many thanks again to the hundreds of dentists around the country who participated in Mouth Cancer Awareness Day once more. We can never underestimate the huge positive impact this initiative has for the profession and we can be proud that lives have been saved by raising the awareness of mouth cancer among the general population and among ourselves.

Fluoride

It may be dispiriting to read and hear so much misleading information being advanced by the opponents of fluoridation as they campaign in local government and in the Oireachtas. It is to be hoped that the forthcoming review from the Health Research Board will offer clarity and assurance on the value of fluoridation. While welcoming the support for fluoridation in the Seanad, I was particularly gratified to read the comments of Senator Sean Barrett, who commended dentists for their stance in support of fluoridation. Senator Barrett went on to say: "I would like other professions in the country to be as patriotic as dentists. Usually, when professions come here, they want more money for themselves. Dentists are a noble exception, saying this public health measure reduces the demand for their services. This is a commendable difference between dentists and other professions".

Dr Peter Gannon
IDA President



Dear Editor,

The book which I recently read should be of interest to all the dental team. It's called *To Rise Again at a Decent Hour* by Joshua Ferris and is on the Man Booker long list this year.

There are plenty of examples of dentists in literature and patients tend to remember the mainly infamous and dysfunctional characters. At last, we have a 'normal' dentist in Paul O'Rourke, the main character. The novel is set in a thriving, five-chair practice in a fashionable address in New York. The main characters are dentist and certified prosthodontist Paul; Connie, the office manager; Betsy Convoy, the hygienist; and, Abby, the dental assistant. So, there is something for everybody here. The book opens with 'The mouth is a weird place'. This opening sets the scene for some strange and amusing happenings. Paul is a complex character with contradictory views on dental nurses, hygienists, food, sport and dental CPD! Some of the comedy for me in this book lies in how Paul can run five chairs, sneak out for a smoke, spend a lot of time on his smartphone, hide in the waiting room and disappear to the toilet. But there is more than comedy in this book; Ferris is also very insightful on modern society.

I wonder how a narrative set in a dental surgery will go down with the general public, but it should be a big hit with the dental profession.

Yours sincerely,

Brendan Fanning 174, Stillorgan Road, Donnybrook, Dublin 4

CPD accreditation for *Journal* reviewers

2 POINTS

The *Journal of the Irish Dental Association* is delighted to announce that the Dental Council has agreed to award verifiable CPD points to dentists who review clinical articles for the *Journal*. In correspondence with *Journal* editor Prof. Leo Stassen, the Council's Education and Training Committee has confirmed that reviewers will be entitled to two CPD points per paper reviewed.

Dr Chris Lynch receives award from ADEE



Dr Chris Lynch received an 'Excellence in Dental Education' Award at the recent Association for Dental Education in Europe (ADEE) Annual Conference in Riga. From applications from all over Europe, three awards were made in the 'Mature' (Senior) Educator section, of which Dr Lynch was one recipient.

The aim of the award is to provide international recognition of excellence in dental education. Chris is a Reader/Consultant in Restorative Dentistry at Cardiff. He is Editor-in-Chief of the Journal of Dentistry and an elected Board Member of the Faculty of Dentistry at RCSI. Chris is pictured receiving his award from Professor Damien Walmsley, President of ADEE (Photograph courtesy of ADEE).

NOT ONLY MEDICINES – MUCH MORE



The new name for the Irish Medicines Board (IMB) is the **Health Products Regulatory Authority (HPRA)**.

Why change? Since 1996 our role as a regulator has expanded to include a number of additional products and functions.

The HPRA name reflects our wider remit which includes the regulation of:

- Human and veterinary medicines
- Clinical trials
- Medical devices
- Controlled drugs
- Blood and blood components
- Tissues and cells
- Cosmetic products
- The protection of animals used for scientific purposes
- Organs intended for transplantation

A new name – but our focus and mission hasn't changed:

To protect and enhance public and animal health through the regulation of medicines, medical devices and other health products.

Find out more on www.hpra.ie





SENSODYNE SENSITIVE DENTIST OF THE YEAR AWARDS 2014


Will you be going to the Ball?

This year, the winners in the Sensodyne Sensitive Dentist of the Year Awards will be announced at a black tie Gala Ball in the Royal Hospital Kilmainham on December 6, hosted by the Irish Dental Association. If you are nominated by a patient, you will receive a letter inviting you and your guests to attend and giving all details on how to book your place.

Your patients can nominate you for an Award at www.sensodynesensitivedentist.ie, where all terms and conditions can also be found.



Are you coming to the Gala Ball to celebrate Sensitive Dentists?



The big dental event of the year – the Sensodyne Sensitive Dentist of the Year Awards – takes place at the Royal Hospital Kilmainham on Saturday, December 6, with host Colette Fitzpatrick of TV3. The Gala Ball is being organised by the Irish Dental Association, in association with the *Journal of the Irish Dental Association* and the generous sponsors of the Awards, Sensodyne.

Celebrating the best in Irish dentistry

In previous years, the Awards were presented at a lunch ceremony only attended by the winners. However, with nominations more than doubling to over 1,000 in recent years, the decision was made to honour all that is great about Irish dentistry with this terrific event. All nominees will be entitled to attend – and to bring the whole dental team as well.

Once again, the judges for the Award are Drs Barry Harrington, Seton Menton, and Anne O'Neill. Nominees will shortly receive a letter from Association President Dr Peter Gannon and Honorary Editor of the *Journal*, Prof. Leo Stassen, inviting them to attend.



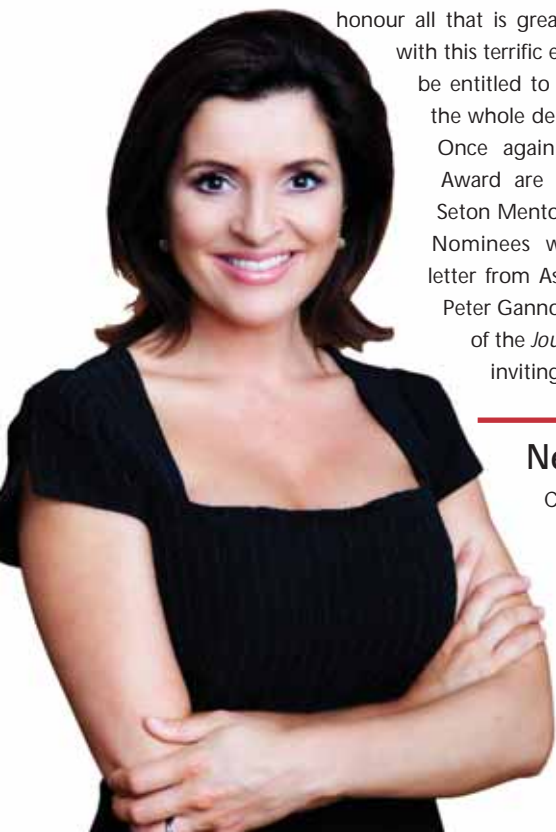Sensitive Dentist of the Year

Make sure you're nominated for this year's awards by displaying this form prominently in your surgery.



A glamorous night

The event will commence with a drinks reception in the Baroque Chapel, followed by a five-course meal. The four regional award winners and the overall Sensitive Dentist of the Year will then be announced, followed by dancing to the ever popular 'Johnnie be Good' band. If you are a nominated dentist, why not make this the Christmas Party for your practice?



News anchor to host Awards

Colette Fitzpatrick is one of the main news anchors at TV3 News for TV3 Ireland. A native of Holycross, Thurles, Co. Tipperary, Colette began her broadcasting career with East Coast FM in Co. Wicklow. She joined the TV3 newsroom in 2001. She has edited and anchored bulletins for Ireland AM and reported on a range of issues for the main evening news. She has also worked with Today FM, where she edited and presented hourly bulletins and reports.

ASTRA TECH IMPLANT SYSTEM

Thank you.
We couldn't have
done it without you.



Clinically
documented
success
over three
decades

We asked how the
ASTRA TECH Implant System
could be improved.
We listened to what you
said you wanted.
We delivered much more.

Simplicity without compromise

The next step in the continuous evolution
of the ASTRA TECH Implant System

- Surgical flexibility
- Restorative ease
- Maintenance of marginal bone

Join the **EVolution!**
44 (0)845 450 0586

implants.uk@dentsply.com www.dentsplyimplants.co.uk
Education – www.courses4implants.com
Surgical partners and GDP restoration – www.dentists4implants.com
Practice growth support – www.goodbyegaps.com



CPD on the road

The CPD roadshows continue. Sessions took place in Cork and Sligo during October, and will be held in Dublin, Galway, Kilkenny and Limerick during November. All workshops are CPD verified and take place from 10.00am to 1.00pm. This is a fantastic opportunity to gain verifiable CPD points in a timely and cost-effective manner. To book your place, call IDA House, Tel: 01-295 0072.

MCAD 2014 success



Almost 600 dental surgeons registered for Mouth Cancer Awareness Day (MCAD) 2014. The event was again a great success and the MCAD committee thanks all dental practices for getting involved again this year.

To date, 22 mouth cancers have been detected as a result of MCAD. The day would not be possible but for the goodwill and assistance of the dental profession.

On behalf of the committee, we sincerely thank you and your dental teams for getting involved in such a worthy cause.

Oral surgery – hands on course



Drs Seamus Rogers and Naomi Rahman, who are both oral surgeons, will give a hands-on course entitled 'Oral Surgery for the General Practitioner' in November. The course will cover practical tips for the GDP in minor oral surgery. It aims to

improve dentists' skills in surgically removing teeth or roots.

The course takes place in the Radisson Hotel, Dublin Airport, on Saturday November 8, from 10.00am to 2.00pm.

To book your place, contact IDA House, Tel: 01-295 0072.

International College of Dentists Meeting Ljubljana



From left: Mrs Marina Mullane; Dr Jerome Mullane; Dr Claudette Graham; Dr Richard Graham; Mrs Joan Feeney; Dr Cecil Linehan; Dr Tom Feeney, European President, ICD 2014-2015; Mrs Pat Corcoran; Dr Declan Corcoran; Dr Paula McHenry, Irish Inductee 2014; Dr Andrew Linton.

The International College of Dentists (ICD) held its 59th Annual European Section Meeting in Ljubljana, Slovenia, at the end of June 2014. This was the first European meeting to be held in one of the 'new' countries and President Professor Ljubo Marion and his team were proud to showcase the many positive things that are happening in the world of dentistry in Eastern Europe.

As always the Irish District was well represented, and this year's inductee was Dr Paula McHenry from Newry in Co. Down. Dr McHenry is a director of the South Down Dental Clinic and specialises in oral surgery and implant dentistry.

Next year will be a major year for the ICD in Ireland with the 60th Annual European Meeting, together with the International Council Meeting, being held in Dublin in October 2015.



QSC Medical, owned and operated by Denis Doyle (the most senior tester of decontamination equipment in Ireland), supplies the most competitively-priced decontamination equipment and service contracts in Ireland. The company sells and services autoclaves, washers and specialised heat sealers as well as reverse osmosis units coupled with ultra violet light.


QSC Medical offers a full, nationwide service to its clients with highly competitive pricing. It is one of the very few companies in Ireland which offers a complete validation service to dental practices with detailed reports.

QSC Medical can also independently and professionally commission your new decontamination equipment. Commissioning projects in the past include Cork Dental Hospital and many others nationwide.

A new lease package will shortly be offered which will include a full set of decontamination equipment (ultrasonic cleaner, washer, and autoclave) and will also include service and annual validation.

Contact Denis on 051 348306 or 0863749350 or email service@qsc-medical.ie

BIG EXPENDITURE DOESN'T HAVE TO MEAN BIG DISRUPTION.



Working Capital Finance

Large lump sum payments can stretch any small business. AIB's Insurance Premium Finance and PromptPay products lets you spread these payments over time. Find out about these and other ways We're Backing Brave.

**WE'RE
BACKING BRAVE**



#backedbyAIB

Drop into any branch,
call 1800 47 47 47 or visit www.aib.ie

WARNING: You may have to pay charges if you pay off a fixed rate loan early.

Lending criteria, terms and conditions apply. Credit facilities are subject to repayment capacity and financial status and are not available to persons under 18 years of age. Security may be required. Minimum application of €5,000 required and maximum term of 11 months. A documentation fee of €63.49 applies to all loans. This fee will be charged with the first repayment. Allied Irish Banks, p.l.c. is regulated by the Central Bank of Ireland.

Patriotic dental profession commended in Seanad fluoridation debate

Irish dentists were commended for their patriotism in the recent Seanad debate on fluoridation.



Trinity College Senator Sean Barrett (left) told the Seanad: "I commend the dental profession on being in favour of a public health measure which reduces the demand for the services of dentists. I would like other professions in the country to be as patriotic as dentists. Usually, when professions come here, they want more money for themselves. Dentists are a noble

exception, saying this public health measure reduces the demand for their services. This is a commendable difference between dentists and other professions".

The Association had made contact with all Senators prior to the debate and shared extensive peer-reviewed research, which shows the benefits of fluoridation and shows no evidence to support many of the scares cited by opponents.

The motion received little support and Senator Mary Ann O'Brien, who proposed the motion with Senators Katherine Zappone and Feargal Quinn, asked that it would not be put to a vote, reflecting the limited support apparent during the Seanad debate.

The policy of fluoridation was supported by Fine Gael, Labour and Fianna Fail Senators as well as Senator Sean Barrett while it was opposed by Sinn Fein and some independent Senators. A transcript of the Seanad debate is available on request to IDA House.

Irish dentist receives prestigious award

Dr Ronan Allen is the recipient of this year's Salkin Award. The Salkin Award is presented to the periodontist who attains the highest score on his/her American Periodontal Board Exams to become a Diplomate. To become a Diplomate, entrants must have completed an educational programme in periodontology, which is accredited by the American Dental Association, and also a comprehensive qualifying and oral examination covering all phases of periodontal disease and its treatment, including dental implants.



Over 200 periodontists from around the world sat the examination. Dr Allen flew to San Francisco to be presented with the award at the American Academy of Periodontology Annual Conference on September 19.

Annual Conference 2015

The Annual Conference 2015 returns to the Rebel county and will take place from April 16-18 at the Rochestown Park Hotel.

Our visiting speakers include: Dr Tim Donley, a periodontist from Kentucky, US, who last visited us in 2012 in Killarney; Professor Ken Kurtz, Professor of Prosthodontics in NYUCD; Professor Tara Renton, who is an oral surgeon with a particular interest in trigeminal nerve injuries and orofacial pain; and Professor Terry Donovan, Professor at the University of North Carolina in restoration.

Irish-based speakers include Drs Alison Dougall, Mairead Cashman and Tom Houlihan, Professor Helen Whelton and many, many more. Dr Eanna Falvey, doctor to the Irish rugby team, will also present. *Bad Science* author Dr Ben Goldacre will present to the conference on Friday afternoon, an unmissable presentation for any scientist.

The conference will include a varied and fun-packed social programme including golf, cultural events, our annual dinner and much more.

Quiz

Answers
page 253

Submitted by SARAH GILL, IDA Employment and Communications Officer. Test your knowledge of some basic statutory minimum entitlements.

QUESTIONS

- Under the Organisation of Working Time Act 1997, full-time employees are entitled to how many paid weeks off for annual leave?
 - two weeks
 - four weeks
 - six weeks
- The Maternity Protection Acts 1994 and 2004 entitle an employee to:
 - 26 weeks' maternity leave together with 16 weeks' additional unpaid maternity leave
 - 16 weeks' maternity leave together with 26 weeks' additional unpaid maternity leave
- Under the Organisation of Working Time Act 1997 employees have the right to:
 - A 30-minute break after four hours of work and a 30-minute break after six hours of work
 - A 10-minute break after four and a half hours of work and a 20-minute break after six hours of work
 - A 15-minute break after four and a half hours of work and a 30-minute break after six hours of work
- As per the Minimum Notice and Terms of Employment Act 1973, how much notice is an employee who has worked for you for three years obliged to give you when leaving?
 - four weeks
 - one week
 - three weeks

Dental Implants

Everything
together.
One price,
one provider.

Enjoy certainty of price with our new
all-inclusive implant bundle.



Premium Bundle Fully customised system

Includes:

- ✓ Screw or cement retained crown (choice of Porcelain fused to Metal**, Fully Milled Zirconia, Porcelain fused to Zirconia)
- ✓ Customised Titanium or Zirconia Abutment
- ✓ Titanium Screw
- ✓ Implant analog and soft tissue model
- ✓ Major commercial systems supported

* Terms and conditions apply

** Semi or high precious alloy extra



**Southern
Cross Dental**

To find out more information call us today
on (ROI) 048 8772 7100 or (NI) 028 8772 7100
or email us at ireland@scdlab.com

Inaugural AGM for Irish Association of Oral Surgery

The Irish Association of Oral Surgery (IAOS) recently held a hugely successful inaugural AGM in IDA House. Open to all surgeons on the Register of Dental Specialists, Division of Oral Surgery held by the Dental Council, the AGM was very well attended.



Andrew Norris, newly elected President of the Association.



The officers, management committee and all who attended the inaugural meeting of the Irish Association of Oral Surgery, which met recently in IDA House. From left: Vaidas Varinauskas; David Ryan; Mary Clarke; David Harris; Darren McCourt; Seamus Rogers; Peter Cowan; Catherine Gallagher; Andrew Norris; Dermot Murnane; Niamh Boyle; Michael Freedman; Sharif Nayyar; Andrew Bolas; Fintan Hourihan; Gary Leonard; Antal Roka; Mary Collins; and, Justin Maloney.

The Association aims to promote dentistry and in particular the specialty of oral surgery. With the help of the IDA and IDU it hopes to represent the interests of its members and their patients in discussions with Government bodies and insurance companies, and to encourage undergraduate and postgraduate training and professional development in the field of oral surgery.

Congratulations are due to all those who attended the AGM and adopted the constitution. Drs Michael Freeman and Seamus Rogers were most deserving of their respective elections as Secretary and Treasurer. Congratulations also to the newly elected non-officer committee. Drs Andrew Bolas, Darren McCourt, Niamh Boyle and Sharif Nayyar are all very accomplished and have a great wealth of experience to call upon. The election of Dr Peter Cowan and Mr David

Ryan as Trustees of the Association speaks volumes of the calibre of the IAOS membership. Mr Fintan Hourihan, as Chief Executive of the Irish Dental Association, had already made an invaluable contribution to the setting up of the Association. The IAOS will benefit hugely from his election as another of the Trustees. On a personal note, I am of course delighted and greatly honoured to have been elected President of the Association. With the support of the membership, officers, committee members, trustees, and the broader dental community, I am sure we will make great progress.

Just as all boats rise on the incoming tide, we can all benefit from co-operation and unity of representation, and thus help shape the future of not only oral surgery, but dentistry in Ireland. Carpe diem!

Dr Andrew Norris

New all-inclusive premium implant bundles

Southern Cross Dental has introduced a variety of set price all-inclusive implant bundles. All major commercial implant systems are supported, with both cement and screw-retained options available. The company says that introducing fixed pricing will greatly help the dentist when estimating patient fees. "Providing our customers with a fixed price implant bundle removes the guesswork for the dentist when it comes to implant costs. This makes it easy for the dentist to determine their fee when discussing treatment options with patients," says Dr David Reaney, General Manager, Southern Cross Dental.

Coming under the banner of 'One price, One provider' Southern Cross Dental views these competitively priced implant bundles as a welcome addition to the marketplace. "Fixed priced implant bundles

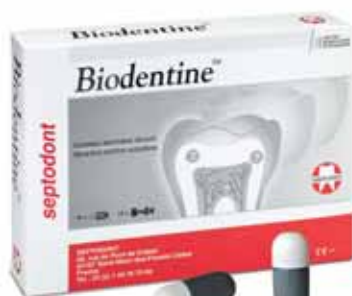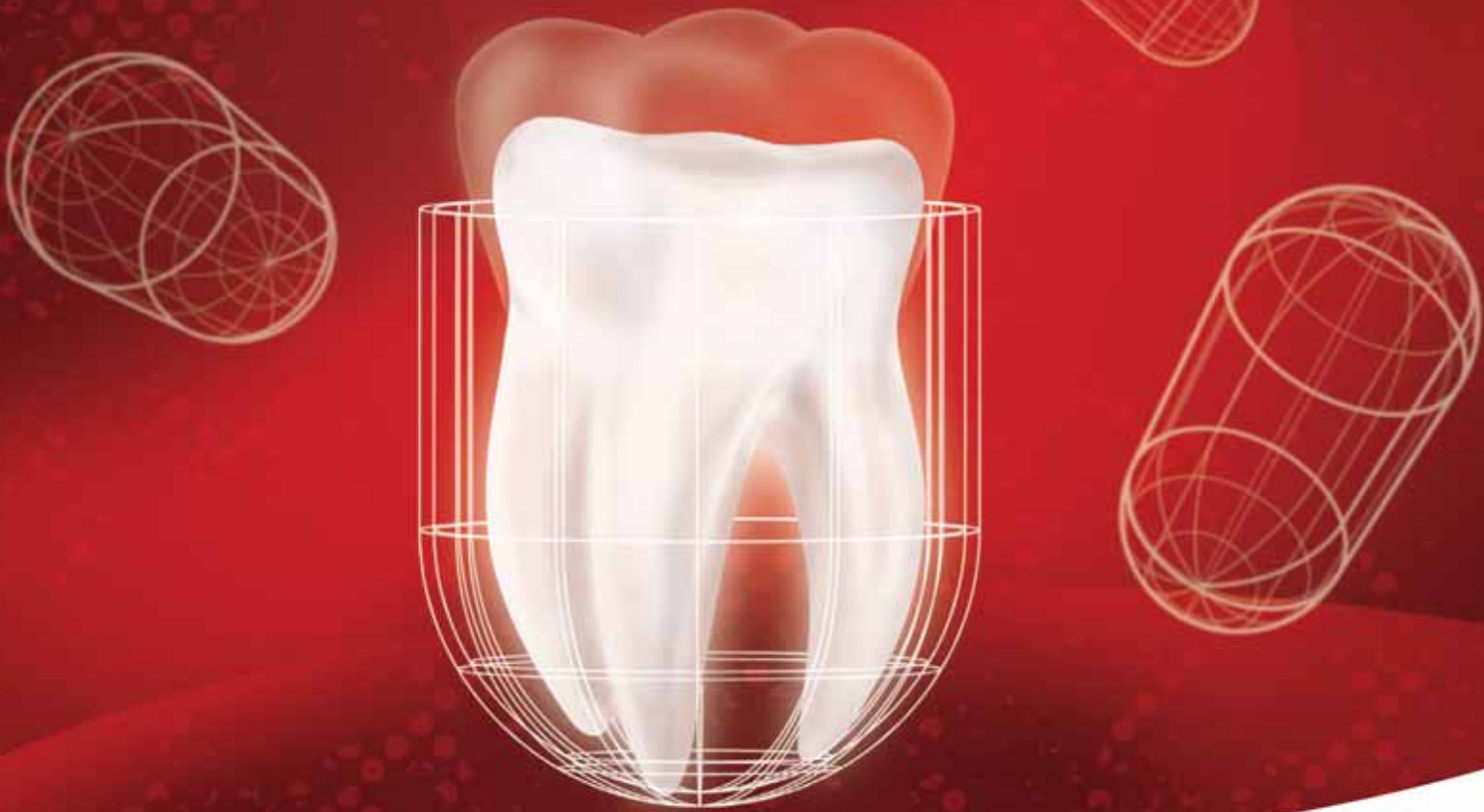are clear and transparent, and avoid any costly surprises when the lab bill arrives," continues Dr Reaney.

Guarantee of fixture

According to Southern Cross Dental, with fixed price implant bundles both the restoration and the fixture are guaranteed. The bundles will include a screw/cement-retained crown, customised titanium or zirconia abutment, titanium screw, implant analogue and implant model. Dr David Reaney says: "Guaranteeing the fixture is an indication of the confidence we have in our product. We understand that the reputation of a dentist relies on the quality of the prostheses received from their laboratory partner". A brochure entitled 'Guide to Implant Retained Prostheses' is available from Southern Cross Dental.

Biodentine™

The first and only dentine substitute in a capsule



ACTIVE
BIOSILICATE
TECHNOLOGY

As the first all-in-one biocompatible and bioactive dentine substitute, Biodentine™ fully replaces dentine wherever it is damaged.

Biodentine™ helps the remineralization of dentine, preserves the pulp vitality and promotes pulp healing. It replaces dentine with similar biological and mechanical properties.

Improving on Biodentine™ clinical implementations, you can now bond the composite onto Biodentine™ in the same visit and perform the full restoration in a single session.

To enjoy the clinical benefits of the first and only dentine substitute in a capsule, ask your dental distributor for Biodentine™.

www.septodont.ie

Tel: +44 (0)1622 695520





The Presidents of the IDA, Dr Peter Gannon (left), and IDTA, Gerard Lavery, at the opening of



Thomas Howley (left) and Pat O'Brien (right) of DMI with Dr Leo Burke of the HSE on the DMI stand.



Patrick Bolger, James Way, and Pat Bolger of Henry Schein with Dr Aoife McGinley from Kilkenny on the Henry Schein stand.

IDA and IDTA join forces

Identex and the IDA Autumn Meeting were staged together in Citywest Hotel, Dublin in September.

"The Irish Dental Association and the Irish Dental Trade Association collaborated to very good effect in the presentation of the IDA Autumn Meeting at the Identex trade show. We were pleased to be involved and hope that our work with the Irish Dental Trade Association will continue," said IDA President Dr Peter Gannon after Identex closed.

President of the Irish Dental Trade Association, Gerard Lavery, said that Identex had been a success with increased numbers attending and more companies exhibiting than the previous year. "The inclusion of the IDA Autumn Meeting at Identex was very welcome. From our point of view it worked because everyone in the dental profession and business benefits from it."



Claire Austin and John Fanning of Voco on their stand.



John McEvoy of Ardagh Dental.



Nick McKelvie and Stephen Ginn on the McDowell+Service stand.



Lesley McKenzie and Peggy Rochford of SDI demonstrate their products to Dr Peter Gannon of the IDA.



Tommy Maguire on the Kerr stand.



Chief Executive Fintan Hourihan and Assistant Chief Executive Elaine Hughes of the Irish Dental Association with the first two speakers at the IDA Autumn Meeting, John O'Connor of Omega, and David McCaffrey of MedAccount.



Peter Morris of Morris Dental.



Karl Ronan and Berty O'Neill of Swordfish Medical.



Dr Hugh Harvie of DPL speaking at the IDA Autumn Meeting.

CPD at Identex

This year, the IDA's Autumn Meeting was held alongside Identex.

David McCaffrey of MedAccount and John O'Connor of Omega Financial Management gave a joint presentation on tax and pension issues for the dental practitioner. Both David and John have extensive specialist knowledge of the dental sector, and offered important information and advice on getting your tax affairs in order, and providing for retirement.

Meanwhile, Dr Hugh Harvie of DPL asked: 'Are you a good dentist? Could you prove it?' In an increasingly litigious society, it is important to be aware of the issues that are of concern to patients, such as confidentiality, consent, and the importance of having a complaints procedure. For dentists, this means being meticulous about record keeping, being aware of patient expectations, and knowing the difference between dental treatment and dental care.

Dr Nick Armstrong, a member of the Patient Safety Committee of the IDA, presented on developments in infection control, a very topical issue for dentists as regulations and legislation change and new guidelines are issued.

Breda O'Malley of Hayes Solicitors gave a very interesting presentation on employment law, including: the importance of a fair and open recruitment process, followed by a probation period; negotiating the minefield of self-employed versus employee in the dental practice; and, what a contract of employment should cover. IDA CEO Fintan Hourihan pointed out that *pro forma* contracts can be accessed via the IDA's website.

After lunch Brid Hendron offered some fascinating insights into how dentists can motivate their patients. She demonstrated the different motivation filters that affect us, and showed the importance of motivating patients in the way that will work for them, trying both positive and negative reinforcement to successfully motivate a patient to, for example, improve their oral hygiene.

Dr Brendan Fanning took the audience through the process of carrying out a radiology audit, and demonstrated that it can be a simple and straightforward process. He pointed out that audits are good for business, as good, safe, clean treatment is extremely important to patients, and advised the audience to let patients know, through websites and marketing literature, that radiology in the practice is audited and quality assured.

Brian Rodgers offered some important information on the safe management of hazardous waste, another topical issue for dentistry. He drew attention in particular to new legislation regarding sharps disposal, and advised dentists to inform themselves about all relevant legislation.

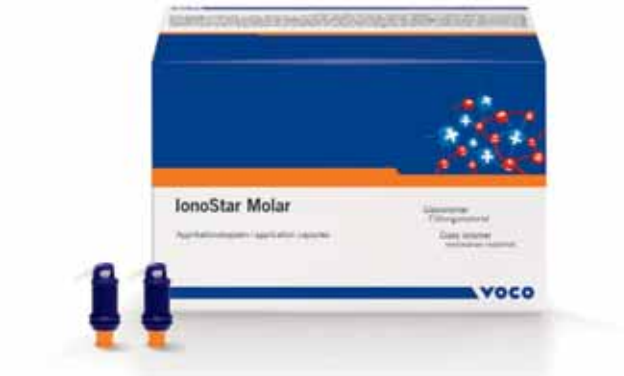IONOSTAR® MOLAR

New glass ionomer restorative material in an innovative application capsule

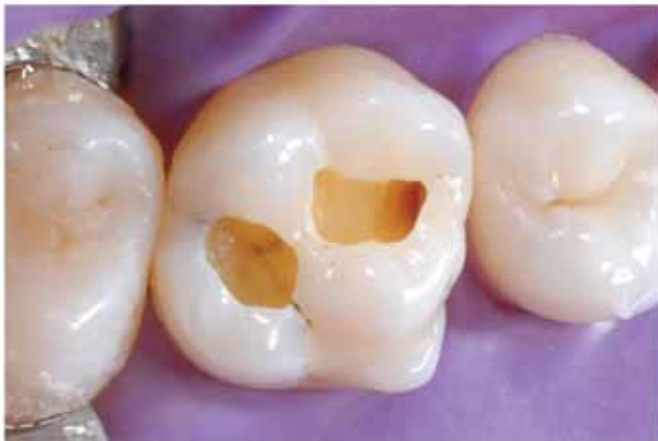IonoStar Molar is a newly developed glass ionomer restorative material which comes in the new VOCO application capsules. The material is applied without conditioner or adhesive and scores particularly highly thanks to its non-sticky consistency and perfect marginal adaptation. IonoStar Molar can be modelled immediately after insertion and cures within four minutes. Its lastingly high level of fluoride release counteracts postoperative sensitivity. In conjunction with Easy Glaze, the nano-filled protective coating for surface sealing, IonoStar Molar can be used to quickly and easily create restorations which are as aesthetic as they are durable.

New type of formulation for optimal material and handling properties

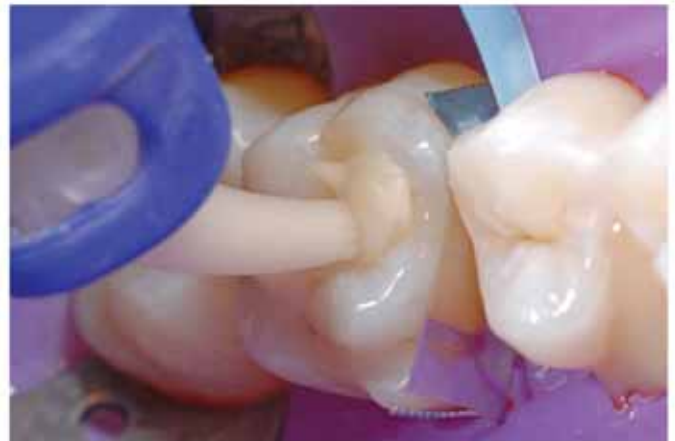IonoStar Molar is based on VOCO's decades of experience in developing glass ionomer cement materials, which have proved themselves a million times in everyday clinical application. Its new type of formulation gives IonoStar Molar its exceptionally good material properties as well as its high



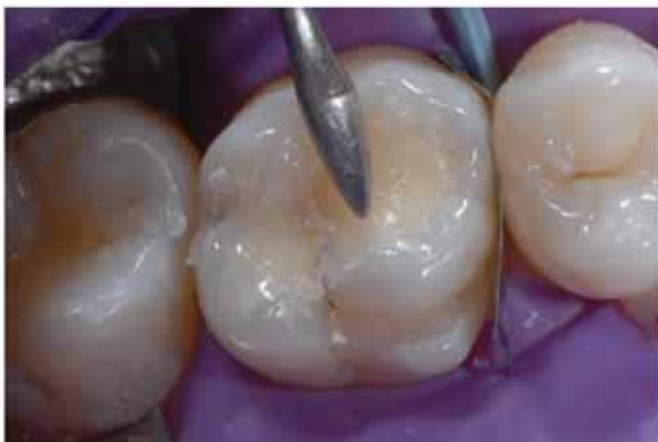compressive strength and abrasion resistance. Furthermore, the new formulation ensures good handling properties and creates the possibility for a certain degree of adjustment of the material's consistency by variation of the high-frequency mixer's mixing duration. Depending on the given situation, the consistency can thus be adjusted to be either firmer or softer.



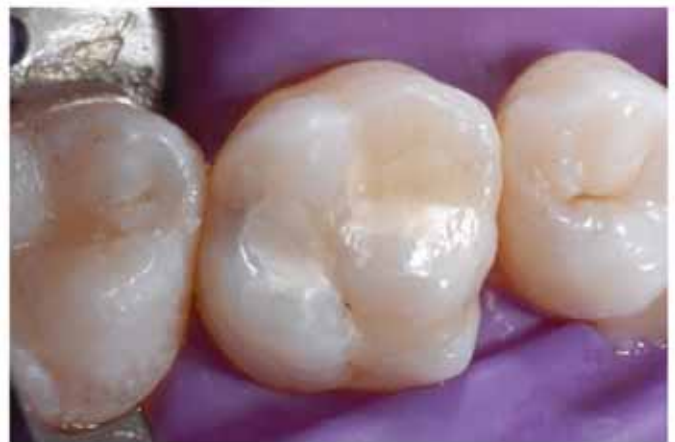View into the cavity displaying deep caries.



IonoStar Molar A3 is applied with the aid of an applicator.



Adaptation and modelling of the material.



View of the finished filling. Photos: Dr Sanzio Marques, Passos/Brazil

Suitable for a variety of indications

IonoStar Molar is suitable for restorations of non-occlusion bearing class I cavities, semi-permanent restorations of class I and II cavities, restorations of cervical lesions, class V cavities, treatment of root caries, restorations of class III cavities, restoration of deciduous teeth, for use as a base or liner and for core build-up as well as temporary restorations. This makes IonoStar Molar a versatile choice providing the required results for many indications, not least thanks to the handling advantages offered by VOCO's new application capsule.

Advantages of the new VOCO application capsule

One special characteristic of the new VOCO application capsule is that an activator is no longer required. The capsule is merely pressed down onto a firm surface, pushing the coloured piston inside the capsule, which is then mixed as usual in a high-frequency mixer. Lift up the application tip of the capsule, insert into a conventional applicator, and the material

is ready for application. Moreover, the new capsule design reaches smaller cavities and difficult-to-access areas in the mouth better than conventional application capsules.

Indications

- Restorations of non-occlusion-bearing class I cavities
- Semi-permanent restorations of class I and II cavities
- Restorations of cervical lesions, class V cavities, root caries
- Restorations of class III cavities
- Restoration of deciduous teeth (permanent)
- Base/liner
- Core build-up
- Temporary restorations

Advantages

- Variable mixing time for adjustment of consistency
- Perfect marginal adaptation and easy application
- Can be modelled immediately after insertion without sticking to the instrument
- In VOCO's new application capsule, thus simple to use without an activator
- The new capsule design reaches smaller cavities and difficult-to-access areas in the mouth
- High compressive strength and abrasion resistance
- With proven VOCO glass technology



1 For activation the capsule is simply placed on a firm surface and pushed down by hand. An activator device is not required.



2 After conventional mixing using a capsule mixer the application nozzle is turned upwards.



3 After placing the activated capsule in an applicator the material is ready for use.

Delivering painless and effective inferior alveolar nerve block anaesthesia

Introduction

The ability to provide painless and effective local anaesthesia is a critical aspect of pain control in dentistry. The success of any practice is at least partly dependent on the reputation of the dentist in terms of delivering painless injections. Mandibular anaesthesia is important for two reasons: anaesthetic failures are most common in this region; and, post-injection complications are more frequently associated with mandibular anaesthesia. In this regard, assessment of the patient should focus in part on identifying previous difficulties with local anaesthesia. Possible problems might include failure to achieve satisfactory local anaesthesia, an unreasonably brief duration of anaesthesia, or significant postoperative pain or stiffness. This short article focuses on the following three areas:

1. Providing a painless injection.
2. Achieving safe and effective local anaesthesia.
3. Identifying and managing post-injection complications.

Providing a painless injection

Step one – control patient anxiety with good verbal communication.

Almost all patients experience anxiety in the dental setting, while some are 'needle phobic'. Heightened anxiety increases our responses to potentially painful stimuli. Validation or recognition of the patient's anxiety by reference to previous uncomfortable or unsuccessful dental visits should be completed during the initial assessment. Time spent on explanation and reassurance will help. During the treatment visit, it is imperative that an anxious patient does not feel rushed.

Step two – position the patient correctly in the dental chair.

For almost all local anaesthetic injections (and particularly inferior dental nerve block injections), it is preferable to place the patient in a semi-supine position with the

head slightly extended backwards (Figure 1). The advantages are: (1) we can rapidly deal with vasovagal syncope (a fainting attack) if it occurs; and, (2) the semi-supine position allows the patient to open the mouth comfortably and widely so that we can visualise the position of entry and path of insertion of the needle (Figure 2).

Step three – preparation of equipment to be used and the site of the injection.

Choose the correct needle length and gauge (Figure 3). Most clinicians use a 27-gauge long needle for inferior alveolar nerve block (IANB) anaesthesia. 25-gauge long needles are not often used in dentistry but are extremely effective. Avoid using 30-gauge short needles. The narrow gauge makes aspiration difficult. In addition, the flexible nature of these needles allows them to bend or break too easily.¹ The assumption that narrow gauge needles are less painful for the patient is false. Clinical studies show that if the injection technique is good, patients cannot differentiate between the width of the needle bores.

Visually inspect the tip of the needle to ensure that it is not 'barbed'. When in doubt, the needle tip may be drawn backwards across a piece of gauze to see if it snags. However, with modern manufacturing techniques this rarely occurs. Needles that have been used two or three times previously for the same patient should be discarded. Dentists should ensure that the local anaesthetic syringe (and cartridge) is self aspirating. The local anaesthetic solution should be stored at room temperature. Warming is unnecessary and may result in increased discomfort for the patient. Avoid using local anaesthetic that is close to its expiration date, as oxidation of the vasoconstrictor may occur (Figure 4). This lowers the pH of the solution and increases discomfort on injection.

Dr Dermot Canavan
BDentSc MGDS MS
Diploma in Conscious Sedation

Address for correspondence:
69 Eglinton Road, Donnybrook,
Dublin 4

Email: dcanavan@iol.ie

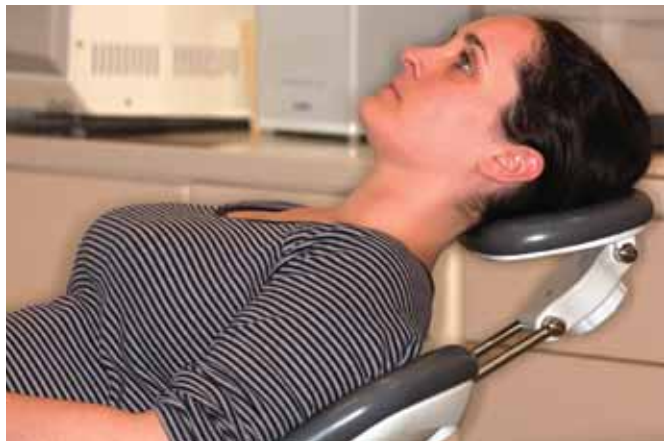

FIGURE 1: For almost all local anaesthetic injections, it is preferable to place the patient in a semi-supine position with the head slightly extended backwards.

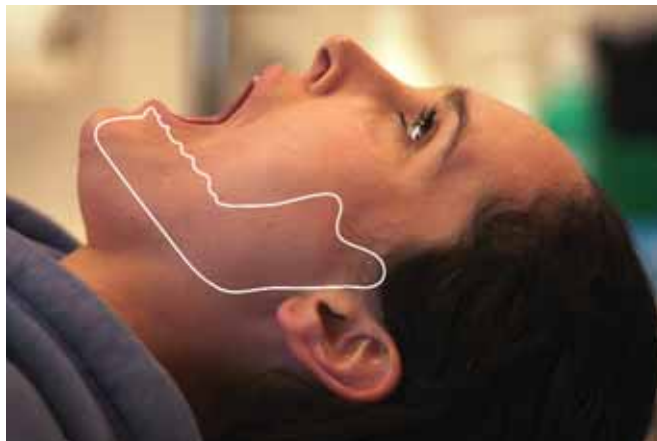

FIGURE 2: The semi-supine position allows the patient to open the mouth comfortably and widely.

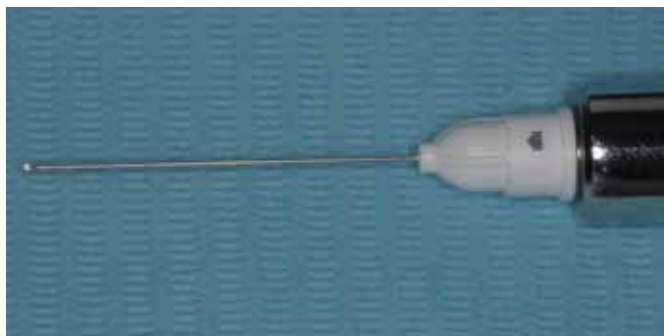
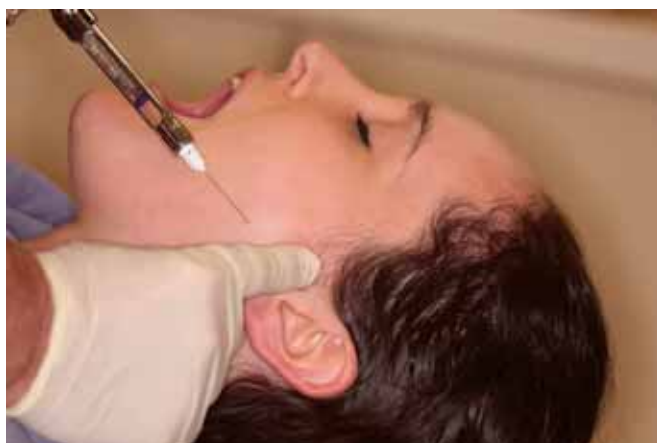
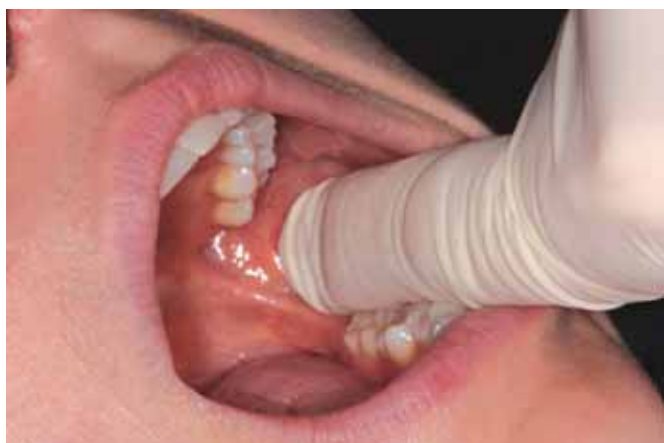
FIGURE 3: Choose the correct needle length and gauge. Note that the black mark on the hub denotes the orientation of the bevel.



FIGURE 4: Avoid using local anaesthetic that is close to its expiration date, as oxidation of the vasoconstrictor may occur.



FIGURES 5 and 6: The objective of IANB injections is to place local anaesthetic as close as possible to the nerve on the lingual aspect of the ramus at a point just above the lingula.

Achieving safe and effective local anaesthesia

The objective of IANB injections is to place local anaesthetic solution as close as possible to the nerve on the lingual aspect of the ramus at a point just above the lingula (Figures 5 and 6). It is essential to aspirate to avoid intravascular injection. Only about 60% of dentists

aspirate routinely, despite the potential dangers to the patient. The rate of injection should be slow, particularly for anxious patients. The recommended rate of injection is about 1ml per minute. Injecting too quickly may cause immediate and/or long-term pain at the site.

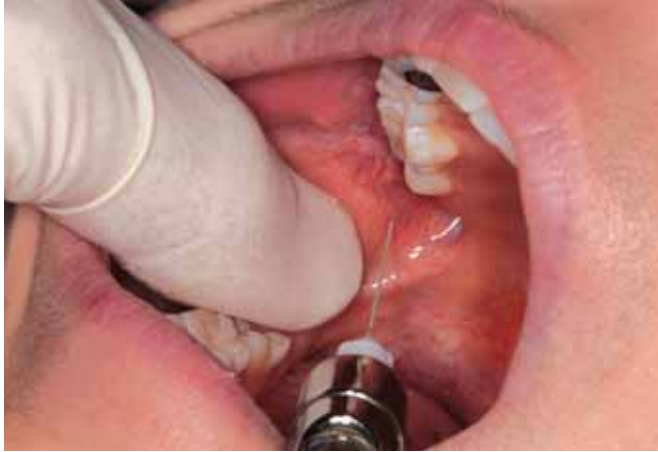

FIGURE 7: The point of needle insertion is normally medial to the border of the pterygomandibular raphe, about one finger width (6-10mm) above the lower occlusal plane. The traditional approach places the barrel of the syringe across the premolar teeth of the opposite side.

Although we use landmarks for needle placement, it is essentially a 'blind approach'. The natural variation in the position of the mandibular foramen may vary from one individual to another. Most failures occur because we have injected too low (beneath the mandibular foramen) or too far forward (too close to the anterior border of the ramus). These difficulties may be overcome by palpating important landmarks such as the anterior border of the ramus (intraorally) and the posterior border (extraorally), to get a sense of the width of the ramus anteroposteriorly. The height of the ramus may be estimated by palpating the angle of the mandible and the lateral pole of the condyle.

The point of needle insertion is normally medial to the border of the pterygomandibular raphe, about one finger width (6-10mm) above the lower occlusal plane. The traditional approach places the barrel of the syringe across the premolar teeth of the opposite side (Figure 7). The trajectory of needle insertion is upwards, backwards and outwards. This is much easier to achieve if the head is extended backwards and the mouth is open widely. Problems arise when mouth opening is limited due to trismus or infection, or when head position is incorrect and the chin is too close to the chest.

Failure to achieve pulpal anaesthesia may occur for a number of reasons, which include poor placement of the needle and the anaesthetic solution, lowered pH due to infection or inflammation, which limits absorption of the solution, accessory innervation from other branches of the mandibular nerve, and possibly expression of sodium channels, which are resistant to local anaesthesia (triggered by nerve injury or infection). Apparent numbness of the lip and chin does not guarantee pulpal anaesthesia. It has been suggested that large myelinated nerve fibres may be more sensitive to local anaesthetic than small myelinated fibres (which generally serve pain transmission). Another possibility is that local anaesthetic solution may fail to adequately penetrate through the nerve into its core fibres, leaving patients feeling numb but still feeling pain.

Identifying and managing post-injection complications

When failure to achieve adequate anaesthesia is attributed to infection or inflammation, the easiest approach is to prescribe antibiotics and/or anti-inflammatories for a period of four or five days. The chances of success with a subsequent inferior nerve block are increased significantly. In situations where the anaesthetic apparently fails due to accessory innervation, options include a complete mandibular division block (aka Gow Gates Block), intraosseous injections or intra ligamentary injections. A popular clinical choice is to add an infiltration injection in the buccal sulcus with articaine (Septanest). The belief is that the articaine is absorbed through tiny foramina in the buccal bone.

Theoretically, there are many potential complications of IANB anaesthesia, but the most common problems are pain with or without limited mouth opening (trismus). Post-injection pain may be due to the development of a small haematoma in the medial pterygoid muscle, and this may also limit mouth opening. As the initial pain experience is quite severe, patients may require non-steroidal anti-inflammatory medications for periods of up to five days. Options include Vimovo (one tablet twice per day), ibuprofen 800-1,200mg per day in divided doses and Keral sachets (25mg per sachet, three times per day). As the haematoma resolves mouth opening generally recovers spontaneously. Once the acute pain phase has passed the patient should be encouraged to stretch the mouth open as frequently as possible.

A less frequent consequence of IANB injections is injury to the inferior dental nerve. This may occur when the tip of the needle inadvertently touches the neurovascular bundle. It may also occur as a result of chemical toxicity. In this regard, there is continued controversy about the use of articaine for IANB injections. However, the evidence regarding the neurotoxicity or otherwise of articaine remains inconclusive. Patients usually experience a sharp 'shock' of pain in the face at the time the injection is being given. A variable degree of post-injection pain may be experienced, but it is generally short lived and responsive to anti-inflammatories. In exceptional cases patients may develop neuropathic pain, which is characterised by unrelenting pain in the distribution of the inferior dental nerve. Management of these rare cases is challenging and referral to a specialist clinic should be considered.

Reference

1. Rahman, N., Clarke, M., Stassen, L.F.A. Case report: management of broken dental needles in practice. *Journal of the Irish Dental Association* 2013; 59 (5): 241-245.



With Colgate MaxWhite One Professional, busy patients can enjoy visibly whiter teeth in just 3 days.¹ Also, they only need as little as 30 minutes a day for home treatment.

Order today from your dental wholesaler.

Results at the Speed of White

Visibly whiter teeth
in just 3 days

From **30** minutes per day

Colgate

MAX
WHITE
ONE
PROFESSIONAL



1. Mohan et al. J Dent 2008; 36:21-26.

Implants in Ireland

Thirty years ago, the first osseointegrated dental implant was placed in a patient in Ireland by Professor David Harris. PAUL O'GRADY asked him about the history of implants in Ireland.

Implants were once the snake oil of dentistry. After centuries of failure resulting in rejection by the body and frequently leaving behind scarred gums and wrecked mouths, reputable dentists were dismissive of the notion of dental implants. During his own time training to be an oral surgeon at University College Hospital in London in the 1960s and early 1970s, Professor David Harris saw the disastrous effects of screws, vents and blades being used as implants. These had appeared without clinical trials and left behind mouths so scarred that not even dentures could be used.

Implants in Ireland

And so in the late 1970s, David found himself working in Dublin with, among his patients, a pool of 10 edentulous people to whom he felt he had nothing to offer. Then word began to emerge of a Swedish system that was proving quite successful. Results of a 10-year study undertaken by the pioneer of this research, Professor Per-Ingvar Brånemark, had been published in a reputable Scandinavian journal. The world of dentistry remained, for the most part, deeply sceptical. Professor George Zarb of Toronto, however, was intrigued. He visited Sweden and then conducted studies to replicate Professor Brånemark's work. Zarb's independent study also had 98% success with dental implants in the lower jaw. He invited Brånemark to present his work at a global conference in Toronto in 1982, at which he described the process of osseointegration whereby metal integrates



Professor David Harris.

into bone to provide the stable base for an implant. The proceedings in Toronto provided weighty evidence of success and the possibility of treatments for patients who had no prospect of treatment up to that point. Prof. Harris decided to see if he could undertake such work and says: "It was not easy to get training as Professor Brånemark was very protective of his technique. You had to provide evidence that you were an oral or periodontal surgeon and work with a prosthodontist". David went to Sweden on one of the very early courses and examined patient after patient that had implants. He says: "The integrity of the team treating patients with Brånemark – the oral surgeon Ulf Leckolm and the prosthodontist Torsten Jemt – was apparent and convincing". However, the cost was huge. At the time the Ir£9,000 required to

A life in dentistry

David Harris was born and raised in Dublin, where he attended Wesley College. He entered medicine after leaving school, but switched to dentistry after the shared first year "because my dental student friends seemed to have more fun". He graduated in 1964 from RCSI and spent six months as a house surgeon in the DDUH. He went to England and got his primary FDS exams and returned to Dublin, where he worked part-time in both practice and the DDUH. Then he got a break: he got a place as a registrar in University College Hospital (UCH) London Dental School. He trained for two years and sat his final FDS, after which he decided to complete his medical studies. UCH London accepted him and, with credit for his training to date, within two years he had qualified.

By this time he was married to Pam Cowan, daughter of the well-known oral surgeon Adrian Cowan, and they had two small children, Paul and Abbe. They wanted to bring their children up in Ireland with their extended family close to them, so they returned and he set up in practice in Dublin in the early 1970s. Paul is now an aviation psychologist with a strong interest in photography (a book of his photographs of Cuba is in print) and Abbe is a Feldenkrais practitioner. (Feldenkrais is a method that helps people move with greater ease and effectiveness by means of gentle body awareness.) In his spare time, David walks, reads, swims, flies (he has a share in a single-engine Piper aircraft) and listens to music – mostly modern jazz such as Stan Getz and Keith Jarrett.

purchase the machines and materials would have bought a house in Dublin. However, Professor Harris was convinced and he carried out the first implant in 1983 at the Mount Carmel Hospital. The lady in question, who had been missing her teeth for 20 years, received a lower jaw of teeth (that's all that was possible at that time). She is still alive with functioning implants to this day.

David Harris points out that the reputation of implants was so bad that when his patients went to their regular dentist or even their GP, they were often advised against proceeding, and David says he understands this. Based on all previous evidence, their advice was understandable. Two consultant prosthodontists collaborated from the start with David: Frank Houston of TCD and Gerard Buckley of UCC but, according to David, it took a period of five to six years for many dentists to accept that a reliable, scientific technique was now in place.

The Irish team developed an excellent rapport with the team in Sweden, and in 1986 Professor Brånemark accepted an invitation to speak at the Royal Academy of Medicine in Dublin. Following meetings, including with Derry Shanley, then Dean of the DDUH, Brånemark decided to make Dublin a centre to collaborate with, along with Professor Daniel van Steenberghe and his team in the University of Leuven in Belgium. The newly opened Blackrock Clinic was put at his disposal. In early 1987, Brånemark, at the invitation of Professor Harris and his colleagues, demonstrated advanced bone grafting techniques in operations on Irish patients in the Blackrock Clinic. Colleagues from over 40 countries attended the demonstration, and the patients were treated *pro bono* by Professor Brånemark.

The following year, a major conference on implants was organised at TCD attended by nearly every major international figure in implants in the world and again addressed by Professor Brånemark. This really put Dublin on the map in the world of the science of implants. And while dental implants are now well established in Ireland and globally, early adopters in Ireland (prior to 1986) included the oral surgeons Nicholas Mahon (RIP), Spencer Woolfe, Peter Cowan and Sean Sheridan. Early adopting prosthodontists included Billy Davis, Noel O'Grady, Andrew Woolfe and Ollie Grant (RIP). By 1992, several more teams began providing implant treatment to a very high standard in Ireland. In fact, since then, Ireland has produced a considerable volume of original research in the area at the three dental schools – UCC, TCD and QUB. A seminar to mark 30 years of implant dentistry in Ireland is taking place on November 7 next and is open to all interested parties.

Developments

Since its establishment as a part of mainstream dentistry, the science of implants has continued to advance. These developments have made implants available for the upper jaw, for the partially dentate and for the single tooth. "In fact, TCD was part of the first multi-centre trial for single tooth implants with myself and Frank Houston. Other major advances have been made in bone augmentation, soft tissue grafting and guided tissue regeneration", says David, who was appointed as a Senior Lecturer in Implant Dentistry at Trinity College Dublin in 2000.



Professor Per-Ingvar Brånemark (centre) with Professor Daniel van Steenberghe (left) and Professor Harris outside the Blackrock Clinic in 1986. Both Professors Brånemark and van Steenberghe were awarded Honorary Fellowships of the Faculty of Dentistry of the Royal College of Surgeons in Ireland as a result of their contribution to the development of implant dentistry.

The other major advance has been in the shortening of the delay between the placing of the implants and the fixing of the prosthetics. "In the past 10 years, with the further development of implant surfaces, the gap has been reduced and in suitable cases, the prosthesis can be fitted on the same day as implants, says David. He also noted the use of CT technology, which allows planning of implant cases in virtual reality and transferring that information to the operative site.

A challenge for the future, he continues, is to understand the role of peri-implantitis: its aetiology, prevention and treatment; and to understand the role of stem cells and growth factors in achieving implant success.

The Dental Amputee

The Dental Amputee is the title of a book written by David Harris in which he explores and explains the fate of the edentulous patient. The bad news is that being toothless is a great deal worse than most people imagine; the good news is that dental implants offer a solution that, in some instances, the patients regard as transformational. The book is being published by Londubh and is due out in late autumn.

Preventing patient caries with sugar-free gum

Dental caries is a prevalent condition in Ireland and throughout the world. The majority of adolescents, and almost all adults, have experienced caries to a greater or lesser extent. The latest global statistics from the World Health Organisation underline the issue: 60–90% of school children and nearly 100% of adults have dental cavities; severe periodontal disease is found in 15–20% of middle-aged (35-44 years) adults; and almost 30% of people aged 65–74 have no natural teeth.

Patients with high caries activity may benefit from chewing sugar-free gum three times a day, preferably after meals to provide an additional preventative effect. This advice should be delivered as part of a complete oral care routine:

- Brushing twice daily with fluoride toothpaste
- Flossing daily
- Ensuring regular dental check-ups
- Chewing sugar-free gum after eating and drinking

Recognition of the benefits of sugar-free gum

The role of sugar-free gum in oral care is recognised and accepted by experts as an important part of an overall oral care routine.

What is the evidence to support the sugar-free gum anti-caries claim?

There are multiple studies to support the anti-caries benefits of sugar free gum when chewed after eating, with the majority indicating reductions in the range of 20–60%.¹⁻³

These peer-reviewed studies have resulted in supporting statements from regulatory and authoritative bodies including the EC (the European Commission), the European Food Safety Authority (EFSA), the IDA (Irish Dental Association), the FDI (the Fédération Dentaire Internationale), the ADA (American Dental Association) and the CSA (Chinese Stomatological Association.)

General Function

Sugar-free chewing gum contributes to:

- the neutralisation of plaque acids
- the maintenance of tooth mineralisation
- the reduction of oral dryness

Disease Risk Reduction

- Chewing sugar-free gum helps neutralise plaque acids. Plaque acids are a risk factor in the development of dental caries.
- Chewing sugar-free gum helps reduce tooth demineralisation which is a risk factor in the development of dental caries.

How does Wrigley collaborate to advance science?

We also collaborate with oral health experts to advance science in this area, for the mutual benefit of consumers and scientific and public health communities. Wrigley supports independent research through organisations such as the European Organisation for Caries Research (ORCA) and the International Association for Dental Research (IADR). Wrigley joined the Dutch Top Institute for Food and Nutrition (TIFN) in a private-public partnership to better understand, maintain and promote oral health.

PLEASE VISIT www.wrigleyoralhealthcare.ie for more information about the programme, together with CPD modules on saliva and the benefits of chewing sugarfree gum.

References

1. **Deshpande A, Jadad AR.** The impact of polyol-containing chewing gums on dental caries: a systematic review of original randomized controlled trials and observational studies. *J Am Dent Assoc.* 2008 Dec;139(12):1602-14
2. **Mickenautsch S, Leal SC, Yengopal V, Bezerra AC, Cruvinel V.** Sugar-free chewing gum and dental caries: a systematic review. *J Appl Oral Sci.* 2007 Apr;15(2):83-8
3. **Rethman MP, Beltran-Aguilar ED, Billings RJ, Hujoel PP, Katz BP, Milgrom P, Sohn W, Stamm JW, Watson G, Wolff M, Wright JT, Zero D, Aravamudhan K, Frantsve-Hawley J, Meyer DM.** Nonfluoride caries-preventive agents: executive summary of evidence-based clinical recommendations. *J Am Dent Assoc.* 2011 Sep;142(9):1065-71



Post-extraction inferior alveolar nerve neurosensory disturbances – A guide to their evaluation and practical management

Précis: This paper focuses on the classification, causes, prevention, management, treatment options and prognosis of inferior alveolar nerve injuries, post dental extraction. Algorithms are provided to guide the practitioner on monitoring or referring these injuries and as to the pros and cons of surgery.

Abstract: Inferior alveolar nerve injuries are a recognised complication of mandibular third molar extractions. This paper describes the different types of nerve injuries that may occur. A differential of possible causes is provided and an approach to the immediate and follow-up management is outlined. The prognosis of such injuries is reviewed so that patients can be informed of the possible postoperative outcome. The algorithm shows the timeline for monitoring/referring and the included tables outline the advantages and disadvantages of surgery versus watchful waiting.

Journal of the Irish Dental Association 2014; 60 (5): 241-250.

Dr Nicola Mahon MFDS MRCS
National Maxillofacial Unit
St James's Hospital
Dublin 8

Prof. Leo FA Stassen
FRCS (Ed) FDS RCS MA FTCD
FFSEM(UK) FFD RCSI
Consultant Oral and
Maxillofacial Surgery

Address for correspondence:
Prof. Leo FA Stassen
National Maxillofacial Unit,
Dublin Dental School and Hospital,
Lincoln Place,
Dublin 2.
Email: leo.stassen@dental.tcd.ie

Introduction

Neurosensory disturbances (NSDs) are a possible side effect of many dental treatments. This study is a review of the current literature on how to manage this complication. The purpose of this paper is to generate an understanding of the mechanisms, causes, management and prognosis of nerve injuries.

Mechanism and classification of nerve injuries

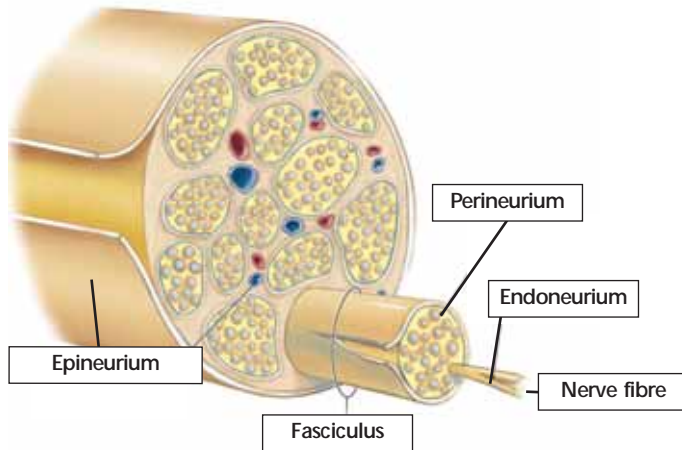
The possible mechanisms of neural injuries are mechanical, chemical and thermal trauma.¹ Nerve injuries were historically classified by Seddon in 1943 based on three types of nerve fibre injury and whether there is continuity of the nerve.²

1. **Neurapraxia** – The least severe form of nerve injury, commonly resulting in temporary numbness/paralysis with subsequent complete recovery within hours to months of the injury (average six

to eight weeks). The structure of the nerve remains intact but the conduction impulses are interrupted by compression/ischaemia of the nerve. The sensory deficit is usually a mild paraesthesia.⁴ A microsurgical intervention is not indicated.⁵

2. **Axonotmesis** – A more severe form of nerve injury. Recovery takes weeks to years and occurs only by the regeneration of axons. There is disruption of the neuronal axon with Wallerian degeneration and yet the myelin sheath remains intact. This injury is usually caused by a severe crush, contusion or stretching of the nerve. The sensory deficit is usually a severe paraesthesia.⁴

3. **Neurotmesis** – The most severe form of nerve injury. There is internal disruption of the architecture of the nerve with perineurium and endoneurium involvement. If the nerve has been completely divided, a neuroma may form



Anatomy of a normal nerve fibre taken from Smith and Lung.³

at its proximal stump and Wallerian degeneration occurs at the distal stump. Causes of neurotmesis include a severe contusion, stretching, laceration, local anaesthetic (LA) toxicity, and transection.

These injuries are likely to be permanent without repair or will only achieve partial recovery. The sensory deficit is characterised by anaesthesia or dysaesthesia.⁴ Thus, a microsurgical intervention may be indicated.⁵ This classification was further developed by Sunderland in 1951.⁶ Sunderland's classification subdivides neurotmesis into a further three divisions (Table 1). Both classifications are still commonly referred to in the literature, but in light of advances in molecular biology, they now have their limitations.

The limitation with these classifications is that they only deal with the anatomical disruption of neural tissue, which we can only presume as we do not see the nerve unless we operate. However, other factors may be involved. When a surgical procedure has been performed, neuronal plasticity occurs. This is the potential of the nervous system to adapt to inputs by changing temporarily or permanently their biochemical, physiological, and morphological characteristics.

Inflammation and injury occurs at the surgical site releasing inflammatory mediators, i.e., prostanooids, which, by activating intracellular pathways, lower the threshold of nociceptors (peripheral sensitisation). This increased excitability of nociceptors can sweep back centrally to the dorsal horn nuclei of the central nervous system (CNS), changing their protein structures, facilitating an increased number of ion channels. This increases excitatory transmitters and reduces inhibitory transmitters, resulting in an abnormal perceptual response to a normal sensory input (central sensitisation). This is usually reversible when the inflammation resolves, but if nerve injury has occurred, both the injured neurons and their non-injured neighbours give action potentials spontaneously – "etopic pacemaker activity".

Alterations in gene expression are produced and this changes the function of neurons. It may be reversible, or non-reversible. If the injured axon and its target are not re-opposed, unmyelinated axons start to die and sensory inflow is permanently disturbed.⁷

Table 1: Comparison between Seddon and Sunderland classifications.

SEDDON 1943	SUNDERLAND 1951
Neurapraxia	First-degree injury
Axonotmesis	Second-degree injury
Neurotmesis	Third-degree injury – Endoneurium disruption but epineurium and perineurium intact
	Fourth-degree injury – Perineurium injury with only epineurium intact
	Fifth-degree injury – Complete transection

Types of sensory nerve impairment

Sensory impairment may be transient or permanent. Nerve damage can be subjectively described by patients as paraesthesia, dysaesthesia, anaesthesia or pain.^{3,5,8,9}

Paraesthesia – represents abnormal sensations.¹⁰ It may be divided into spontaneous paraesthesia or elicited paraesthesia.^{11,12} Patients present with symptoms of "pins and needles", "tingling", "burning", "prickling", "itchiness", or "partial numbness", which may not be particularly unpleasant.^{1,3}

Dysaesthesia – Unpleasant abnormal sensation, whether spontaneous or evoked.^{3,11,12} It includes:

- *hyperalgesia*: exaggerated amplified response to a noxious stimulus.³
- *allodynia*: pain evoked by innocuous stimuli such as light touch or gentle pressure to deep tissue, not normally painful when applied elsewhere in the body.¹¹

Anaesthesia – Total absence of sensation, including pain or an insensitivity to all forms of stimuli that would normally be painful.^{3,11,12} Symptoms that are akin to post-dental injection anaesthesia.

Pain – An unpleasant sensory and emotional experience, associated with actual or potential tissue damage and/or described in terms of such damage.¹²

– *Neuroma pain*: pain aggravated by mechanical stimulation.¹³

Differential of the possible causes of nerve injury

The extraction

It is estimated that 42.9-69% of all iatrogenic injuries to the inferior alveolar nerve (IAN) are caused by third molar surgery, especially those molars impacted in close proximity to the IAN.^{14,15} Renton stated that nerve injury can be temporary in 8% of these cases and permanent in 3.6% of these cases.^{9,16} Rates of paraesthesia are quoted as 0.4-8.4%.^{17,18,19,20,21,22} This may be caused by direct trauma to the nerve (root elevators may cause blunt trauma to the nerve via

Table 2: Factors which initiate or perpetuate disorders of neuronal tissue (systemic diseases which also cause neuropathies).^{1,10,42}

Bacterial infections	Viral infections (herpes zoster)	Arthritides	Neoplasia	Metastases	Haematological diseases (leukaemia and lymphoma)
Multiple myeloma	Cysts	Metabolic disorders (diabetic neuropathy)	Vitamin deficiencies	Alcohol abuse	Drug-induced diseases (chemonecrosis)
Bone diseases (osteomyelitis)	Multiple sclerosis	Sarcoidosis	Epilepsy (seizure may have caused a fracture)	Collagen vascular diseases	Psychological disorders

compression or the nerve may be disrupted by rotating burs).²⁰ It may also be caused by indirect trauma via compression of the nerve, due to oedema or formation of a haematoma post extraction.²³ A minor compression usually only causes a temporary conduction block (i.e., Seddon's neuropraxia/Sunderland's first-degree injury).²⁴ Extraction of a tooth which required elevation of a mucoperiosteal flap adjacent to the mental nerve may cause a more severe type of stretching injury, causing rupture of the endoneurium and perineurium (Sunderland's third- and fourth-degree injuries).²⁴ Neurotmesis can occur if the IAN passed through the root of the tooth and during elevation of the tooth, the nerve may have been subsequently transected.^{20,24} If the patient had severe resorption of the mandible, the position of the inferior alveolar nerve/mental nerve may be at a high level in the bone and easily crushed.

The inferior alveolar nerve block

Pogrel and Thamby in 2000 estimated that every full-time practitioner will have one patient in their lifetime of work who will suffer from permanent nerve involvement as a result of IAN block.²⁵ IAN injury has a lesser incidence than lingual nerve injury because it can be deflected by the needle, unlike the more vulnerable lingual nerve.^{3,25} The causative factor may be: **a)** the needle makes direct contact with the nerve, traumatising it; or, **b)** the needle tip became barbed on contacting the bone especially in the case of multiple injections.^{3,15,25,26} Smith and Lung in 2006 described how these barbs can rupture the perineurium, herniate the endoneurium and cause transection of multiple nerve fibres and even entire fascicles, especially on withdrawal. (Seddon's axonotmesis/Sunderland's second- and third-degree nerve injuries).³ However, due to the small diameter of the needle – 0.45mm – compared to the larger diameter of the inferior alveolar nerve – 2-3mm – it is thought to be impossible for a needle to shear all nerve fibres, thus neurotmesis should not occur and therefore a transient paresis is a high possibility or **c)** the formation of a haematoma caused by trauma to the intraneural blood vessels by the needle.^{3,25,27} This results in epineuritis, which compresses nerve fibres, inducing a reactive fibrosis and subsequent scar formation.³ Thus, a neuropraxia or axonotmesis may occur depending on the amount of pressure applied to the nerve.³ For this type of injury, recovery may take weeks as neurotisation and remyelination must occur.³ Pain or an electric shock sensation is not a definite indicator of having made contact with the nerve.³

Neurotoxicity of the local anaesthetic

If the LA is injected intrafascicularly, or is deposited in the nerve during needle withdrawal, this can induce a localised chemical injury to the nerve.³ Smith and Lung explain how this results in demyelination, axonal degeneration and inflammation of the surrounding nerve fibre within the fascicles.³ Thus, the nerve blood barrier breaks down and endoneurial oedema occurs, followed by ischaemia, and subsequently by the formation of reactive free radicals, which can cause cytotoxic injury to the nerve.³ Haas and Lennon implicated prilocaine and articaine as having a higher incidence of neurotoxicity than lidocaine.²⁷ It is speculated that because these anaesthetics are present at higher concentrations (i.e., 4% articaine), they will produce a larger amount of toxic metabolites after being metabolised.^{3,27} Articaine caused Sunderland class four lesions.¹¹ However, lidocaine has also been implicated in neurotoxicity.²⁸ Conversely, some studies claim that articaine is safe for use, yet still conclude that the most commonly reported drug-related adverse event was paraesthesia.²⁹ In a study by Pogrel and Thamby in 2000, prilocaine was more frequently linked to cases of neurotoxicity (36% of patients developed dysaesthesia after a block).²⁵ In a later study, Pogrel in 2007 showed lidocaine to cause the majority of nerve damage (35%), prilocaine caused nearly 30% and he did not see disproportionate nerve involvement from articaine at 17%.²⁸ A recent report concluded that increased rates of NSDs related to articaine have not been confirmed.³⁰ Paraesthesia related to LA usually resolves in a few days/weeks.^{1,3,29}

Mandibular fracture

Mandibular fractures can occur during or post extraction. The incidence of this is estimated as 37 in 750,000 extractions.³¹ A fracture can cause a partial or total transection, a laceration or a stretch on the nerve, especially if displaced. This stretching results in Sunderland third-degree and fourth-degree injury.²⁴ Libersa *et al.* in 2002 indicate that fractures can occur in all grades of tooth impaction, especially in male patients over 25 years of age.³¹ Woldenberg *et al.* in 2007 implicate the relative volume of tooth in the jaw, pre-existing infection, not maintaining a soft diet in the postoperative period and surgical technique as factors predisposing to mandibular fractures.³²

Post-extraction infections

Delayed onset wound infections are defined as infectious swellings

with onset generally one week after extraction.³³ Figueiredo *et al.* in 2005 estimate their incidence after third molar extraction as 1.5%.³³ Infection was evident between 10 and 84 days post extraction, usually before one month.³³ Haematomas or food debris trapped beneath the flap can also be a nidus for infection.³⁴

Infection can cause:

- 1) mechanical/local pressure due to accumulation of purulent exudate;
- 2) ischaemia associated with inflammatory process; or,
- 3) toxic metabolic products of bacteria, which can breach the perineurium.³⁵ Gram-negative bacteria are often involved in the production of neuropathies.³⁵ In cases of non-persistent episodes of nerve irritation, paraesthesia should resolve within days or weeks as the cause is removed.³⁵

Other possibilities

Concurrent dental treatments at the time of the extraction could also be considered a potential cause, e.g., root canal treatment, implant placement and orthodontic treatment have all been implicated as causing NSDs.^{20,36,37,38,39,40,41,42,43,44}

Management

The management of a patient who presents post extraction with sensory dysfunction involves: history taking; examination; radiographs; sensory testing; provision of information regarding possible treatments; prognosis; and, a decision to monitor or refer.

History taking^{46,47,48,49,50,51,52,53,54}

WHO guidelines suggest that nerve injuries should be assessed in terms of impairment, activity limitation and participation restriction.⁵⁴

Ask the patient the following questions:

- ▶ When did the sensory impairment begin? (Delayed onset may indicate infection, or post-op fracture.)
- ▶ Can you describe the symptoms, i.e., complete numbness, burning, pain, tingling, pins and needles, etc.?
- ▶ Is there a family history of chronic postoperative pain?
- ▶ Is the sensation precipitated by touching the affected area?
- ▶ Has there been a change in character of the sensation (i.e., a complete numbness may change to a paraesthesia indicating possible return of sensation)?
- ▶ Could you point to the area of altered sensation?
- ▶ Has there been an increase or decrease in the size of the area of impairment since it first began?
- ▶ Have you noticed an improvement or disimprovement in the severity of the symptoms?
- ▶ Have you problems with speech, mastication, swallowing, food and liquid incompetence (drooling), or lip or cheek biting (to assess functional deficits)?
- ▶ Does this impede your daily activities or affect you emotionally and how does it impact on your quality of life?

Examination

Examine the patient extraorally and intraorally for: lymphadenopathy;

swelling; heat; redness; tenderness on palpation; step deformities; rash (herpes zoster); discharge; haematoma formation; sequestrae; and, trismus.¹

Medical history

Ask the patient if they have a personal or family history of the aforementioned systemic diseases and review their current and previous medication. Enquire regarding the family's pain threshold.

Radiograph

Consult pre-operative radiographs for proximity of the tooth to the IAN. Take a postoperative radiograph and look for a dislocated root fragment in the mandibular canal or a dislodged bone fragment from the roof of the canal compressing the nerve. If there is deviation or disruption of the canal, then decompression is indicated.

Quantitative sensory testing⁵⁰

Nerve injuries may affect:

- 1) mechanoreception (touch pressure, positional sense);
- 2) thermoreception (hot, cold); and,
- 3) nociception (pain).

These sensations must be assessed to monitor whether a sensory disturbance is persistent or improving. Robinson *et al.* in 1992 described a method of sensory testing and, with this in mind, a similar way of testing may be employed using everyday equipment in the general dental practice.⁵²

Firstly a subjective assessment involves asking the patient about the severity of their symptoms.⁵³ Hillerup in 2008 has shown that there is an excellent correlation between NSD expressed in the patient's words and the objective findings by clinicians.¹⁵

An objective assessment is achieved by testing the injured side and comparing it to the non-injured side, which is used as a control.⁵² The room should be quiet; the patient should close their eyes and raise their finger to indicate they feel a stimulus.⁵²

An objective assessment involves:

1) *Light touch perception*^{22,52,55} (Figure 1)

Using a cotton pellet to lightly touch the affected area, one can map and measure an area within which no stimulus can be felt.

2) *Pain (pin-prick) perception* (Figure 2)

Repeat as above using a dental probe and again map the area of anaesthesia or pinch the lower lip within a tissue forceps to ascertain if the stimulus is felt.^{3,15,52,55}

3) *Two-point discrimination threshold* (Figure 3)

Place a tweezers on the skin and enquire if one point or two points can be felt. Lips can distinguish two points 2-4mm apart, whereas skin over the lower border of the mandible can distinguish only 8-10mm.⁵² The two-point discrimination is usually higher on the injured side.¹⁵

4) *Thermal assessment* (Figure 4)

Test the affected area using a cotton pellet firstly dipped in cold water then in hot water.

(Recommended: Heat 45-50 degrees Celsius. Cold 0-20 degrees

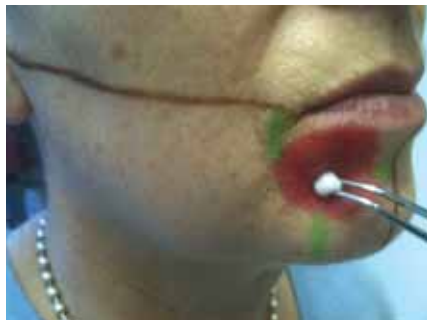

FIGURE 1: Light touch perception.

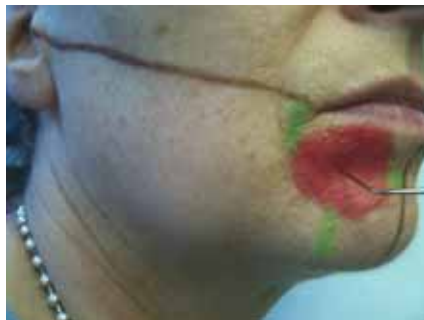

FIGURE 2: Pain (pin-prick) perception.

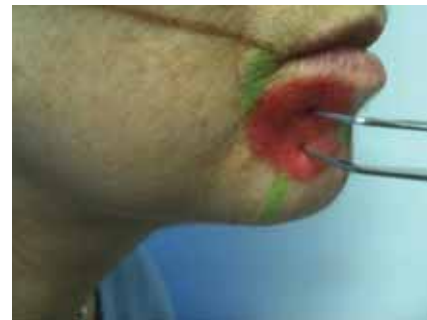

FIGURE 3: Two-point discrimination threshold.

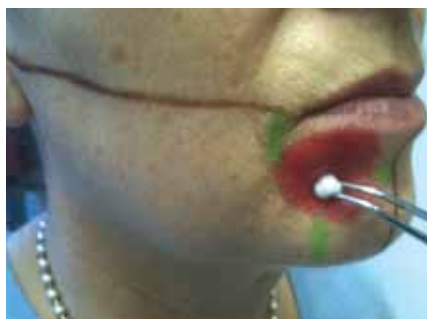

FIGURE 4: Thermal assessment.

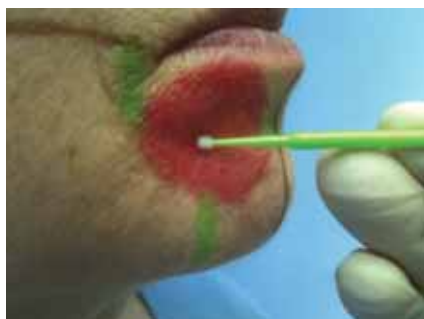

FIGURE 5: Directional sense.

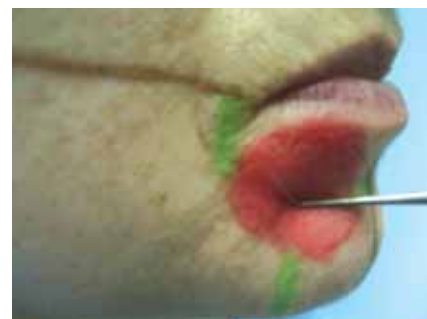

FIGURE 6: Pointed dull discrimination.

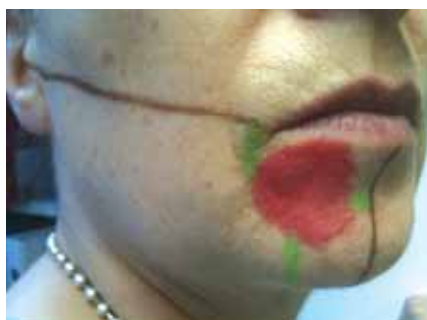

FIGURE 7: Photograph the mapped area.

Celsius. This exact measurement is difficult to achieve in practice.)¹⁵

5) Directional sense (Figure 5)

Brush the area with a brush or probe asking the patient in which direction the instrument is moving.^{15,22}

6) Pointed dull discrimination (Figure 6)

Alternate between the blunt end and the sharp end of a probe and ask the patient is the sensation sharp or dull.⁵²

7) Location of touch

Ask the patient to point to the area that has just been touched by a probe.²⁴

8) Photograph (Figure 7)

By taking a photo of the mapped area, this may be used for comparison at the next visit. It is difficult to achieve reproducibility with photos so reproducible markings should be placed. In Figure 7, a line is drawn from the midpoint of the tragus to the commissure of the mouth and another line drawn from the midpoint of the vermilion border of the lower lip, to the midpoint of

the lower border of the chin (black line). The distance from the affected area (red shaded area) to the reproducible markings may be measured with a ruler and recorded (green lines).

Robinson *et al.* stated that light touch stimuli, pain (pin-prick) stimuli and two-point discrimination thresholds are adequate to detect evidence of early sensory recovery and that the latter two tests are the most likely to reveal a persistent sensory neuropathy.⁵² A patient's objective assessment may disimprove at a future visit and this may be a sign that a neuroma has formed, which is interfering with nerve conduction.¹⁵

Treatment options

1) "Wait and see"

- Reassure the patient as it has been reported that 96% of injuries recover spontaneously.²⁰
- However, if the injury does not improve within three months it is likely to be permanent.⁵⁴
- Monitor by regular objective and subjective sensory testing at one-week, one-month, two-month and three-month intervals.⁵⁵
- Advise the patient to take care with shaving, oral hygiene, and hot food or drinks, and warn them against cheek biting.

2) Treat painful neuropathies

Anticonvulsant drugs (gabapentin 300mg on the first day, 600mg on the second day, 900mg on the third day to be titrated to 1,800mg or to a maximum dose of 3,600mg), tricyclic antidepressants (amitriptyline, starting at 10mg and titrating to a maximum dose of 75mg), 5% lidocaine patches, topical clonazepam, benzocaine lozenges, Botox injections,

benzodiazepines, carbamazepine, steroids and vitamin B supplements have been used.^{3,4,13,39,54,55,56} (NB: Adverse side effects of drugs – dizziness, visual disturbances, depression, rash.)¹⁵

3) *Treat suspected infection*

Antibiotics, surgical drainage, Corsodyl mouthwashes and irrigation of the socket may reduce infection and subsequently decompress the nerve.⁵⁷

4) *Refer to psychologist for cognitive behavioural therapy.*⁵⁴

5) *Refer to a speech therapist if speech function is impaired.*⁵⁴

6) *Refer for further assessment, surgical exploration, +/- microsurgical repair.*

If there is minimal/no resolution of a large neuropathic area, poor mechano-sensory function, or poor daily function with moderate to severe pain, then exploration may be warranted.⁵⁴

This may involve one of the following procedures:

Decompression – This is indicated when a retained root fragment, a fragmented part of the roof of the mandibular canal or a foreign body is compressing the nerve, thus relieving pressure on the nerve by the surgical excision of constricting bands or widening of a bony canal.⁵⁶

Primary direct re-anastomosis – This is indicated where there has been a complete transection of the nerve with both ends lying in close proximity to one another. The ends are then slightly stretched, reapposed and then sutured together using epineurial sutures.⁵⁶

External neurolysis – This procedure frees the nerve from inflammatory adhesions.⁵⁸

Internal neurolysis – This procedure removes the inflammatory adhesions between the nerve fascicles.¹³

Neurectomy – This is the complete removal of the injured nerve.

Nerve grafting – This is indicated where both cut ends of the nerve are far apart and a graft is needed to bridge the continuity defect, e.g., the sural nerve, the great auricular nerve and medial antebrachial nerve may be used.^{59,60}

Vein graft – This reconstructs the nerve gap between the cut ends of a nerve. The vein is placed over each cut end and is inserted via an extraoral approach following decortification of the mandible, e.g., facial vein.⁶⁰

Nerve conduits – These are used to reconstruct a nerve gap. Examples are alloplastic conduits such as gortex.⁶⁰

Muscle graft – Muscles such as the masseter, the tongue or the anterior digastric may be used. Muscles may be freeze-dried and the neuronal elements of the injured nerve can grow over the laminin sheath of the muscle (denatured muscle autograft).^{59,60}

Excision of neuromas – Neuromas (benign tumours of nervous tissue) need to be excised before anastomosis can be achieved.

7) *Refer to a pain management specialist*

In cases of intractable dysaesthesia, urgent referral may be necessary. This condition can severely affect a patient's quality of life, producing significant psychological effects, and has even led patients to take their own life.^{9,15,61} The plan may include a multi-

disciplinary approach with therapeutic medication, counselling and CBT.⁵⁴

Prognosis

The prognosis for recovery from an IAN nerve injury has been estimated as 96% of the injuries recovering within four to eight weeks.²⁰ Gregg in 1995 indicated that higher levels of recovery can be expected in young patients, in good health, where local tissues are well perfused with no foreign bodies obstructing healing and where epineurial sheaths are intact or severed ends are passively opposed.¹³ Persistent injury is more likely to occur if it was a severe injury, an older patient, a delayed presentation or when the injury is more proximal to the cell body.⁵⁴ Loescher *et al.* in 2003 described how following an injury, the nerve often remains in position and regeneration begins.⁶² The advantage that an IAN injury has over a lingual nerve injury is that it has a bony canal, which acts as a conduit for the regeneration of nerve fibres;^{14,15} conversely, the bony canal can predispose it to ischaemic trauma and resultant permanent nerve damage may occur.⁹ However, if the nerve is displaced into the socket, or if a fragment of bone from the roof of the canal is causing an obstruction, regeneration may only be aided by surgery.⁵⁶ The visual sighting of the IAN bundle implies intimate relationship of the tooth to the nerve and carries a 20% risk of paraesthesia.²² Observed injuries should be repaired within 90 days.⁶³ Knowledge of the mechanisms of nerve injuries should influence our decision to refer or monitor (**Table 3**). Neurapraxias, usually as a result of compression, are represented as a paraesthesia and result in complete recovery.⁴ Compression injuries often resolve within four months.⁵⁵ Paraesthesia tends to subside in six months.²⁰ Axonotmesis is usually represented as a severe paraesthesia and incomplete recovery has been described.⁴ Neurotmesis is characterised by anaesthetics or dysaesthetics and may not recover, thus may require surgery.⁴ Anaesthesia beyond one month is likely to have permanent impairment.⁵⁵

Hillerup in 2008 noted how recovery of lesions differed depending on their aetiology, with lesions due to third molar removal recovering more significantly.¹⁵ He expressed how these lesions had an impressive potential for recovery to a level where microsurgical repair may not be necessary.¹⁵ He also found that there was no convincing recovery from lesions caused by endodontic procedures or LA.¹⁵ In contrast to this, Pogrel stated that studies have shown that LA-induced nerve injuries usually result in a spontaneous recovery in an eight-week period and Smith and Lung found that they have an excellent prognosis.^{3,25} Exploratory surgery has been unhelpful in patients with permanent nerve involvement due to LA and may even exacerbate symptoms.²⁵ Surgery for LA-induced NSD is hazardous, as a need to mobilise the medial pterygoid to gain access may be necessary.²⁵ Surgical outcomes may improve the sensory function, but often a complete recovery of nerve function is not achieved and patients must be informed about this.¹⁴ Pogrel and Lam estimate a 50% and 55% improvement after surgery, respectively.^{64,65}

Neurogenic, central pain, and anaesthesia dolorosa is not affected by peripheral surgery and such surgery may worsen the situation.⁶¹ Many

patients can adapt to their neurological deficits and hypoaesthesias are well tolerated.^{15,55} This must be considered in light of the morbidity of surgery. Patients with mild hypoaesthesia or paraesthesia are unlikely to benefit from surgical intervention.⁵⁶ The most rapid phase of recovery occurs within the first six months.¹⁵ Most authors agree that a deficit present beyond 12 months is usually permanent.^{14,15,57}

There is still disagreement as to the timing of referral for exploration/microsurgery. Some authors recommend early repair,^{4,66} another encourages late repair.¹³ Robinson *et al.* in 2004 found no significant correlation between delay and surgery outcomes.⁵⁶ Most surgeons want patients referred within three months of injury.¹⁴ Based on cellular and biomechanical events, the ideal time for surgical repair is two to three weeks post injury, to maximise resolution of sensory function, and minimise neuronal cell death and central changes.⁵⁴ Strauss *et al.* in 2006 state that if microsurgery is performed within one year of injury, recanalisation or neurotisation of distal end organs can be expected to occur.¹⁴ After one year, there is significant distal nerve scarring and atrophy, making surgery more difficult and less predictable.^{14,63} Renton *et al.* in 2010 state that the injury is permanent after three months, as it is after three months that permanent central and peripheral changes occur within the nervous system that are unlikely to respond to surgery.^{9,54} However, in reality, defining the exact type of nerve injury that has occurred and predicting recovery is not so straightforward. Patients must be evaluated with other factors such as: systemic co-morbidities; age; gender; pain threshold; psychological reaction to pain; and, their expectations accounted for. The multifactorial aspects of nerve injuries make prediction of a definite prognosis more difficult.

Prevention of nerve injuries

Firstly, consult NICE Guidelines to ensure that the tooth needs to be extracted and plan to avoid using high concentration LA and multiple blocks.⁹ Precautions to prevent nerve injury include:

- 1) **Radiographs (Figure 8):** Taken from Kosit Bowornchai *et al.*⁶⁷⁾ An OPG and/or periapical radiograph should be taken to assess the likelihood of damage to the IAN. Signs including: a) darkening of the root where it crosses the inferior alveolar canal; b) deflected or hooked roots around the inferior alveolar canal; c) narrowing of the root, implying perforation or grooving by the nerve; d) a bifid root apex, representing intimacy of the apical periodontal membrane; e) interruption or obliteration of either of the cortical lines of the inferior alveolar canal; f) diversion of the inferior alveolar canal in the region of the root apices; g) narrowing of the inferior alveolar canal; and, h) presence of a juxta-apical area warrant caution/further investigation.^{9,15,16,22,68,69} Renton indicated that (f) and (h) were found to be most predictive of nerve injury.⁹
- 2) **CT scans (Figure 9):** Taken from Kosit Bowornchai *et al.*⁶⁷⁾ These are expensive but are being used more often nowadays. As an x-ray only gives a two-dimensional view, errors may arise.^{20,22} If a panoramic +/- a periapical x-ray reveals a suspected close proximity between the tooth to be extracted and the mandibular canal, then dental CT scans are advised to determine the precise

Table 3: Risk assessment of a wait-and-watch approach versus surgical repair following the development of an IAN complication.

SURGICAL REPAIR	MONITORING
PROS	PROS
<ul style="list-style-type: none"> ■ Repair of nerve damage; ■ Decompression of compressed nerve; ■ Conduit/graft repair of severed nerve; ■ Removal of adhesions or neuromas; ■ Method of choice for complete anaesthesia beyond three months, profound hypoaesthesia with no improvement beyond three months, dyaesthesia beyond three months and clinically observed nerve severance; and, ■ May cure intractable/neuropathic pain that is unresponsive to medication. 	<ul style="list-style-type: none"> ■ Sensory deficit is highly likely to recover; ■ Allows the clinician time to observe if the deficit is in the process of recovering; ■ Hyperaesthesia can be made worse by surgery; ■ Absence of abnormal sensations, i.e., allodynia, hypopathia, indicate a good prognosis for spontaneous recovery; ■ Allows patient time to develop a tolerance for the condition; ■ Spares surgical morbidity; and, ■ Sensory deficit may be acceptable to the patient.
CONS	CONS
<ul style="list-style-type: none"> ■ Risk associated with general anaesthetic (GA) or sedation; ■ Improvements shown in only 50-55%; ■ Extra-oral approach may cause scarring or damage to the mandibular division of the facial nerve; ■ Morbidity of the harvest site; ■ Risk of further damage to the nerve; ■ Ineffective for medical neuropathy; ■ May not be appropriate treatment in a medically compromised patient; and, ■ May be ineffective if there is an excessive delay following injury. 	<ul style="list-style-type: none"> ■ Monitoring can subject a patient to chronic pain if the medical management of pain is ineffective; ■ A neuroma may form, causing pain; ■ A neuroma may form, complicating future surgery; and, ■ Delaying surgery by monitoring for more than one year reduces the favourable outcome of the surgery.

relationship between these structures so as to be able to accurately assess the extractive risk.^{23,68}

3) Alternative procedures

Procedures such as a coronectomy (removal of the crown only) or an orthodontic extraction (extruding the tooth before extraction) have been described in the literature to avoid IAN damage for a 'high-risk' extraction.^{23,69}

4) Referral to a specialist

Operator expertise has repeatedly been implicated as a factor in predicting nerve damage.^{5,18,20,21,57,70} Robert *et al.* in 2005 showed that IAN injury rates decrease with years of experience.⁷⁰ Trainee

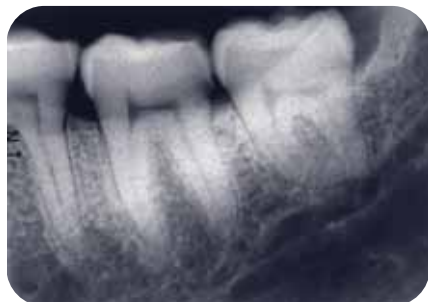

FIGURE 8A: Radiographs.

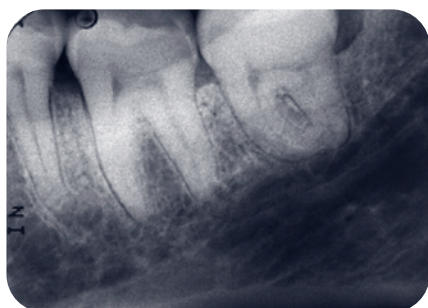


FIGURE 8B

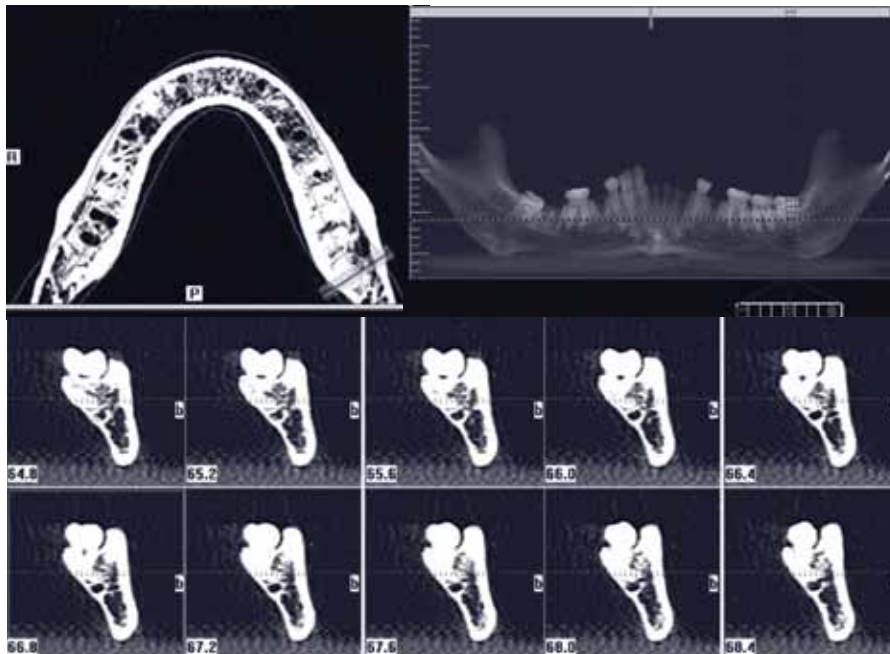


FIGURE 9: CT scans.

surgeons showed a higher prevalence of paraesthesia in their patients than their more experienced colleagues, and permanent nerve damage was four times more likely in the trainee group of patients also.²⁰ It is important that practitioners recognise the need to refer a patient if the extraction does not appear to be within his/her field of expertise.

Consent and legal implications

A patient must be given an informed consent to sign before the extraction. Any extraction that appears to pose a risk to the IAN should be considered for consent, including third molars and surgical extractions near the mental foramen. Risk of a 2% permanent injury and 20% temporary injury should be declared.⁹ Consent should mention hyperaesthesia and pain and not only numbness.⁵ LA injection injury is considered a 'no culpa' incident, i.e., insurance coverage is not conditioned by proven malpractice.¹¹ Financial compensations are usually paid after a two-year period has elapsed since the time of injury. A spontaneous recovery within this period will not be compensated for.⁵ Unfortunately, this delay also results in a patient not seeking exploration/microsurgical repair till the money has been paid and by this time recovery, even after surgery, is unlikely.

Conclusion

Iatrogenic NSDs are a rare complication of dental procedures. IAN injuries are less debilitating than lingual nerve injuries and also have a higher incidence of spontaneous recovery.⁵ Although there is disagreement within the literature about protocols for managing these patients, some common findings are acknowledged. Most authors agree that an urgent referral for surgery is recommended if an

observable injury occurred (nerve appears sectioned in the extraction socket, a bleed requiring packing to control it, retained root or a foreign body in the canal).^{4,9,63} Another shared belief is that most injuries resolve within three to six months and a lack of improvement at three-month follow up warrants specialist referral.¹⁴ There is also agreement among authors that nerve impairment beyond one year is usually permanent and surgery after one year may be unsuccessful or have a worse prognosis.^{14,57} Surgery may potentiate neuropathic symptoms and patients need to be warned about this.⁵⁴ The literature also outlines how many patients become tolerant to their sensory impairment and that surgery may not be indicated in this situation. Most of the literature refers to nerve injuries in the form of neurapraxia, neurotmesis and axonotmesis and predicts the prognosis based on this; however, we must be aware that this anatomical classification is becoming outdated and may be oversimplifying the situation. It is important to realise that nerve injuries have more complex molecular pathways and patients may have multifactorial aetiologies; therefore, this paper serves as a guideline only. These patients can be very difficult to treat. Equipped with this knowledge, general dental practitioners should be able to assess, monitor, refer and advise their patient as to the best individualised treatment for them.

References

1. Ozkan, B.T., Celik, S., Durmus, E. Paraesthesia of the mental nerve stem from periapical infection of mandibular canine tooth: a case report. *Oral Surg Oral med Oral Pathol Radiol Endod* 2008; 105: e28-e31.
2. Seddon, H.J. Three types of nerve injury. *Brain* 1943; 66: 237 – 288.
3. Smith, M.H., Lung, E.K. Nerve injuries after dental injection: a review of the Literature. *J Can Dent Assoc* 2006; 72 (6): 559-64.
4. Donoff, R.B. Surgical management of inferior alveolar nerve injuries (Part 1): The case

Table 4: Neurological post extraction review.

	Asymptomatic	Anaesthesia	Paraesthesia		Hypoaesthesia		Dysaesthesia	
One to two weeks	No treatment required	Monitor/OPG and refer	Monitor/OPG and review 3/12		Monitor/OPG and review 3/12		Monitor/OPG and review 3/12	Pain Mx
Three months			No improvement or worsens or develops dysaesthesia REFER	Improving Monitor 3/12	No improvement or worsens or develops dysaesthesia REFER	Improving Monitor 3/12	No improvement or worsens REFER	Improving Monitor 3/12
Six months			No improvement or worsens REFER	Improving Monitor 3/12	No improvement or worsens REFER	Improving Monitor 3/12	No improvement or worsens REFER	Improving Monitor 3/12
12 months			No improvement or worsens REFER	Improving Monitor 6/12	No improvement or worsens REFER	Improving Monitor 6/12	No improvement or worsens REFER	Improving Monitor 6/12

for early repair. *J Oral Maxillofac Surg* 1995; 53: 1327-1329.

- Libersa, P., Savignat, M., Tonnel, A. Neurosensory disturbances of the inferior alveolar nerve: a retrospective study of complaints in a 10-year period. *J Oral Maxillofac Surg* 2007; 65: 1486-1489.
- Sunderland, S. A classification of peripheral nerve injuries producing loss of function. *Brain* 1951; 74: 491-516.
- Kehlet, H., Jensen, T.S., Woolf, C.J. Persistent post-surgical pain: risk factors and prevention. *The Lancet* 2006; 367: 1618-1625.
- Pogrel, M.A., Kaban, L.B. Injury to the inferior alveolar and lingual nerves. *J Am Dent Assoc* 1993; 21 (1): 50-54.
- Renton, T. Prevention of iatrogenic inferior alveolar nerve injuries in relation to dental procedures. *Dent Update* 2010; 37: 350-363.
- Seo, K., Tanaka, Y., Terumitsu, M., Someya, G. Characterization of different paresthesias following orthognathic surgery of the mandible. *J Oral Maxillofac Surg* 2005; 63: 298-303.
- Hillerup, S., Jensen, R. Nerve injury caused by mandibular block analgesia. *Int J Oral Maxillofac Surg* 2006; 35: 437-443.
- Classification of Chronic Pain (2nd ed.)*. IASP Task Force on Taxonomy IASP Press, Seattle, 1994.
- Gregg, J.M. Surgical management of inferior alveolar nerve injuries (part 11): The case for delayed management. *J Oral Maxillofac Surg* 1995; 53: 1330-1333.
- Strauss, E.R., Ziccardi, V.B., Janal, M.N. Outcome assessment of inferior alveolar nerve microsurgery: A retrospective review. *J Oral Maxillofac Surg* 2006; 64: 1767-1770.
- Hillerup, S. Iatrogenic injury to the inferior alveolar nerve: etiology, signs and symptoms, and observations on recovery. *Int J Oral Maxillofac Surg* 2008; 37: 704-709.
- Renton, T., Yilmaz, Z., Gaballah, K. Evaluation of trigeminal nerve injuries in relation to third molar surgery in a prospective patient cohort. Recommendations for prevention. *Int J Oral Maxillofac Surg* 2012; 41: 1509-1518.
- Chiapasco, M., De Cicco, L., Marrone, G. Side effects and complications associated with third molar surgery. *Oral Surg Oral Med Oral Pathol* 1993; 76 (4): 412-420.
- Sisk A.L., Hammer, W.B., Shelton, D.W., Joy, E.D. Jr. Complications following removal of impacted third molars: the role of the experience of the surgeon. *J Oral Maxillofac Surg* 1986; 44: 855-859.
- Lopes, V., Mumenya, R., Feinmann, C., Harris, M. Third molar surgery: an audit of the indications for surgery, post-operative complaints and patient satisfaction. *Br J Oral Maxillofac Surg* 1995; 33: 33-35.
- Jerjes, W., Swinson, B., Moles, D.R., El-Maaytah, M., Banu, B. et al. Permanent sensory nerve impairment following third molar surgery: a prospective study. *Oral Surg Oral Med Oral Pathol and Endod* 2006; 102 (4): 1-12.
- Bataineh, A.B. Sensory nerve impairment following mandibular third molar surgery. *J Oral Maxillofac Surg* 2001; 59: 1012-1017.
- Tay, A.B.G., Medline, Go., W.S. Effect of exposed inferior alveolar neurovascular bundle during surgical removal of impacted lower third molars. *J Oral Maxillofac Surg* 2004; 62 (5): 1-1.
- Bonetti, J.A., Bemandi, M., Laino, I., Checchi, V., Checchi, L. Orthodontic extraction: riskless extraction of impacted lower third molars close to the mandibular canal. *J Oral Maxillofac Surg* 2007; 65: 2580-2586.
- Robinson, P.P. Observations on the recovery of sensation following inferior alveolar nerve Injuries. *Br J Oral Maxillo-Fac Surg* 1988; 26: 177-189.
- Pogrel, M.A., Thamby, S. Permanent nerve involvement resulting from inferior alveolar nerve blocks. *J Am Dent Assoc* 2000; 131 (7): 901-907.
- Stacy, G.C., Hijar, G. Barbed needle and inexplicable paresthesias and trismus after dental regional anesthesia. *Oral Surg Oral Med Oral Pathol* 1994; 77 (6): 585-588.
- Haas, D.A., Lennon, D. A 21-year, retrospective study of reports of paraesthesia following local anaesthetic administration. *J Can Dent Assoc.* 1995; 61 (4): 319-320, 23-26, 29-30.
- Pogrel, M.A. Permanent nerve damage from inferior alveolar nerve blocks – an update to include articaine. *CDA Journal* 2007; 35 (4): 271-273.
- Malamed, S.F., Gagnon, S., Leblanc, D. Articaine hydrochloride: a study of the safety of a new amide local anaesthetic. *J Am Dent Assoc* 2001; 132: 177-185.
- Daublander, M.M. Need for a change? Articaine vs lidocaine. *JDA* 2011; 57 (5): 265-267.
- Libersa, P. Immediate and late mandibular fractures after third molar removal. *J Oral*

- Maxillofac Surg* 2002; 60: 163-165.
32. Woldenberg Y., Gatot I., Bodner, L. Iatrogenic mandibular fracture associated with third molar removal. Can it be prevented? *Med Oral Pathol Oral Cir Bucal* 2007; 12: E70-2.
 33. Figueiredo, R., Valmaseda-Castellon, E., Berini-Ayres, L., Gay-Escoda, C. Incidence and clinical feature of delayed-onset infections after extraction of lower third molars. *Oral Surg Oral Med Oral Pathol Radiol Endod* 2005; 99: 265-269.
 34. Goldberg, M.H., Galbraith, D.A. Late onset of mandibular and lingual dysesthesia secondary to postextraction infection. *Oral Surg Oral Med Oral Pathol Oral Radiol Endod* 1984; 58: 269-271.
 35. Yeler, O. Infection-related inferior alveolar and mental nerve paraesthesia: case reports. *Quintessence Int* 2004; 35: 313-316.
 36. Scolozzi, P., Lombardi, T., Jacques, B. Successful inferior alveolar nerve decompression for dysaesthesia following endodontic treatment: Report of 4 cases treated by mandibular sagittal osteotomy. *Oral Surg Oral Med Oral Pathol Radiol Endod* 2004; 97: 625-631.
 37. Tilotta-Yasukawa, F., Millot, S., El Haddioui, A., Bravetti, P., Gaudy, J.F. Labiomandibular paresthesia caused by endodontic treatment: an anatomic and clinical study. *Oral Surg Oral Med Oral Pathol Radiol Endod* 2006; 102 (4): 1-16.
 38. Poveda, R., Bagan, J.V., Diaz Fernandez, J.M., Sanchis, J.M. Mental nerve paresthesia associated with endodontic paste within the mandibular canal: report of a case. *Oral Surg Oral Med Oral Pathol Radiol Endod* 2006; 102 (5): 1-7.
 39. Pogrel, M.A. Damage to the inferior alveolar nerve as the result of root canal therapy. *J Am Dent Assoc* 2007; 138: 65-69.
 40. Scarano, A., Di Carlo, F., Quaranta, A., Pittelli, A. Injury of the inferior alveolar nerve after overfilling of the root canal with endontic cement: a case report.
 41. Escoda-Francoli, J., Canalda-Sabli, C., Soler, A., Figueiredo, R., Gay-Escoda, C. Inferior alveolar nerve damage because of overextended endontic material: a problem of sealer cement biocompatibility. *JOE* 2007; 33 (12): 1484-1489.
 42. Worthington, P. Injury to the inferior alveolar nerve during implant placement: a formula for protection of the patient and clinician. *Int J Oral Maxillofac Implants* 2004; 19: 731-734.
 43. Baxmann, M. Mental paresthesia and orthodontic treatment. *The Angle Orthodontist* 2005; 76 (3): 533-537.
 44. Farronato, G., Garagiola, U., Farronato, D., Bolzoni, L., Parazzoli, E. Temporary lip paresthesia during orthodontic molar distalization: report of a case. *AJODO* 2008; 133 (6): 1-5.
 45. Robinson, C.M., Addy, L., Luker, J., Eveson, J.W., Prime, S.S. A study of the clinical characteristics of benign trigeminal sensory neuropathy. *J Oral Maxillofac Surg* 2003; 61: 325-332.
 46. Melzak, R. The McGill Pain Questionnaire: Major properties and scoring methods. *Pain* 1975; 1 (3): 277-299.
 47. Krause, S., Backoja, J., Misha-Miroslav, M.D. Development of a neuropathic pain questionnaire. *The Clinical Journal of Pain* 2003; 19 (5): 306-314.
 48. Thomas, R.J., Meewen, J., Asbury, A.J. The Glasgow Pain Questionnaire: A new generic measure of pain; development and testing. *International Journal of Epidemiology* 1996; 25: 1060-1067.
 49. Aggarwal, V.R., Lunt, M., Zakrzewska, J.M., Macfarlane, G.J., Macfarlane, T.V. Development and validation of the Manchester orofacial pain disability scale. *Community Dent Oral Epidemiol* 2005; 33: 141-149.
 50. Eliav, E., Gracely, R.H., Nahlielei, O., Benliel, R. Quantitative sensory testing in trigeminal nerve damage assessment. *J Orofacial Pain* 2004; 18 (4): 339-344.
 51. Koutantji, M., Pearce, S.A., Oakley, D.A. The relationship between gender and family history of pain with current pain experience and awareness of pain in others. *Pain* 1998; 77: 25-31.
 52. Robinson, P.P., Smith, K.G., Johnson, F.P., Coppins, D.A. Equipment and methods for simple sensory testing. *British Journal of Oral and Maxillofacial Surgery* 1992; 30: 387-389.
 53. Bijur, P.E., Silver, W., Gallagher, E.J. Reliability of the visual analogue scale for measurement of acute pain. *Academic Emergency Medicine* 2001; 8 (12): 1153-1157.
 54. Renton, T., Yilmaz, Z. Managing iatrogenic trigeminal nerve injury: a case series and review of the literature. *Int J Oral Maxillofac Surg* 2012; 41: 629-637.
 55. Queral-Godoy, E., Valmaseda-Castellon, E., Berini-Ayres, L., Gay-Escoda, C. Incidence and evolution of inferior alveolar nerve lesions following third molar extractions. *Oral Surg Oral Med Oral Pathol Radiol Endod* 2005; 99 (3): 259-264.
 56. Robinson, P.P., Loescher, A.R., Yates, J.H.M., Smith, K.G. Current management of damage to the inferior alveolar and lingual nerves as a result of removal of third molars. *Br J Oral Maxillofac Surg* 2004; 42: 285-92.
 57. Blondeau, F., Daniel, N.G. Extraction of impacted mandibular third molars: postoperative complications and their risk factor. *J Can Dent Assoc* 2007; 73 (4): 325-325c.
 58. Greenwood, M., Corbett, I.P. Observations on the exploration and external neurolysis of injured inferior alveolar nerves. *Int J Oral Maxillofac Surg* 2005; 34: 252-256.
 59. Rath, E.M. Skeletal muscle autograft for repair of human inferior alveolar nerve: a case report. *J Oral Maxillofac Surg* 2002; 60: 330-334.
 60. Pogrel, M.A., Maghen, A. The use of autogenous vein grafts for inferior alveolar and lingual nerve reconstruction. *J Oral Maxillofac Surg* 2001; 59: 985-988.
 61. Eriksson, L., Hillerup, S., Dr., A Odont, Reibel, J., Persson, D.D.S. *et al.* Traumatic changes of the inferior alveolar nerve and Gasserian ganglion after removal of a mandibular third molar: Report of a case.
 62. Loescher, A.R., Smith, K.G., Robinson, P.P. Nerve damage and third molar removal. *Dent Update* 2003; 30: 375-380, 382.
 63. Ziccardi, V.B., Steinberg, M.J. Timing of trigeminal nerve microsurgery: a review of the literature. *J Oral Maxillofac Surg* 2007; 65: 1341-1345.
 64. Pogrel, M.A. The results of microsurgery of the inferior alveolar and lingual nerves. *J Oral Maxillofac Surg* 2002; 60: 485.
 65. Lam, N.P., Donoff, R.B., Kaban, L.B. Patient satisfaction after trigeminal nerve repair. *Oral Surg Oral Med Oral Pathol Oral Radiol Endod* 2003; 95: 535.
 66. Meyer, R.A. Applications of microneurosurgery to the repair of trigeminal nerve injuries. *Oral Maxillofac Surg Clin Nth Am* 1992; 4: 405.
 67. Kositbowornchai, S., Densin-Aksom, W., Piumthanaroj, P. Ability of two radiographic methods to identify closeness between mandibular third molar roots and inferior alveolar canal: a pilot study. *Dentomaxillofac Radiol* 2010; 39 (2): 79-84.
 68. Savi, A., Manfredi, M., Pizzi, S., Vescovi, P., Ferrari, S. Inferior alveolar nerve injury related to surgery for an erupted third molar. *Oral Surg Oral Med Oral Pathol Oral Radiol and Endod.* 2007; 103 (2): 1-5.
 69. Renton, T., Hankins, M., Sproate, C., McGurk, M. A randomised controlled clinical trial to compare the incidence of injury to the inferior alveolar nerve as a result of coronectomy and removal of mandibular third molars. *Br J Oral Maxillo-Fac Surg* 2005; 43: 7-12.
 70. Robert, R.C., Bacchett, P., Pogrel, M.A. Frequency of trigeminal nerve injuries following third molar removal. *J Oral Maxillo Fac Surg* 2005; 63: 732-735.

dexketoprofen trometamol
Keral®

**Granules for
Oral Solution**



- **Only NSAID available in an oral solution¹**
- **Onset of analgesic activity as early as 30 minutes²**

**FOR SHORT TERM SYMPTOMATIC TREATMENT
OF MILD TO MODERATE ACUTE DENTAL PAIN²**

Keral® 25 mg granules for oral solution (dexketoprofen). Prescribing information

Please consult the Summary of Product Characteristics (SPC) for full prescribing information.

Presentation: Sachets containing 25 mg Dexketoprofen, as dexketoprofen trometamol.

Use: Short term symptomatic treatment of acute mild to moderate pain.

Dosage: Adults: 25mg every 8 hours or 12.5mg every 4-6 hours. Maximum daily dose 75mg. Use lowest effective dose for the shortest duration necessary to control symptoms. For acute pain administer 15 minutes before meals. For short term use only. In the elderly or those with mild-moderate hepatic dysfunction or mild renal dysfunction, initial maximum daily dose of 50mg. Close monitoring advised in the elderly or those with hepatic dysfunction. Not recommended for children or adolescents.

Contra-indications: Hypersensitivity to dexketoprofen, the excipients or other NSAIDs, NSAID induced attacks of asthma, bronchospasm, acute rhinitis, or nasal polyps, urticaria or angioneurotic oedema. Known photoallergic or phototoxic reactions during treatment with ketoprofen or fibrates. History of gastrointestinal bleeding or perforation related to previous NSAIDs therapy. History of or active peptic ulcer/haemorrhage, chronic dyspepsia or suspected peptic ulcer/haemorrhage, other active bleeding or bleeding disorders, Crohn's disease or ulcerative colitis, severe heart failure, moderate-severe renal dysfunction, severe hepatic dysfunction, haemorrhagic diathesis and other coagulation disorders, severe dehydration, during the third trimester of pregnancy and lactation.

Warnings and precautions: Caution in allergic conditions. Avoid use with concomitant other NSAIDs including COX-2 selective inhibitors. Use lowest effective dose for the shortest duration necessary to control symptoms. Gastrointestinal bleeding, ulceration or perforation which can be fatal, have been reported with all NSAIDs at anytime during treatment, with or without warning symptoms or a previous history of serious gastrointestinal events. When gastrointestinal bleeding or ulceration occurs withdraw treatment. The risk of gastrointestinal bleeding, ulceration or perforation is higher with increasing NSAID doses, in patients with a history of ulcer, particularly if complicated with haemorrhage or perforation, and in the elderly. The elderly have an increased frequency of adverse reactions to NSAIDs especially gastrointestinal bleeding and perforation which may be fatal. Commence treatment in these patients on the lowest dose available. Ensure cure of oesophagitis, gastritis and/or peptic ulcer before starting treatment. Monitor patients with history of GI disease. Special care with NSAIDs in patients with a history of gastrointestinal disease (ulcerative colitis, Crohn's disease). Consider combination therapy with protective agents (e.g. misoprostol or proton pump inhibitors), and in patients requiring concomitant low dose aspirin, or other drugs likely to increase gastrointestinal risk. Monitor patients with a history of gastrointestinal toxicity, particularly when elderly, for unusual abdominal symptoms (especially gastrointestinal bleeding) particularly in the initial stages. Caution in patients receiving oral corticosteroids, anticoagulants, SSRIs or anti-platelet agents. Do not use with warfarin, other coumarins or heparin. Caution in patients with impaired renal function, receiving diuretic therapy or those who develop hypovolaemia. Ensure adequate fluid intake, may increase plasma urea nitrogen and creatinine. Caution in patients with impaired hepatic function. May increase some liver parameters. Monitor and advise patients with hypertension and/or mild to moderate heart failure. Special caution in patients with cardiac disease, especially episodes of previous heart failure. Monitor and advise patients with a history of hypertension and/or mild to moderate congestive heart failure as fluid retention and oedema have been reported. Some NSAIDs (particularly at high doses and long term treatment) may be associated with a small increased risk of arterial thrombotic events (e.g. myocardial infarction or stroke). Careful consideration before treating patients with uncontrolled hypertension, congestive heart failure, established ischaemic heart disease, peripheral arterial disease, and/or cerebrovascular disease. Similar consideration before initiating longer-term treatment of patients with risk factors for cardiovascular disease (e.g. hypertension, hyperlipidaemia, diabetes mellitus, smoking). Serious skin reactions (some

of them fatal), including exfoliative dermatitis, Stevens-Johnson syndrome, and toxic epidermal necrolysis reported very rarely. Discontinue treatment at the first appearance of skin rash, mucosal lesions, or any other sign of hypersensitivity. Particular caution in patients with congenital disorder of porphyrin metabolism, dehydration, directly after major surgery if long term use necessary, monitor hepatic and renal function and blood count. Stop treatment at first signs of severe hypersensitivity reactions. Avoid use with varicella. Caution in patients with haematopoietic disorders, systemic lupus erythematosus or mixed connective tissue disease. As other NSAIDs, dexketoprofen can mask the symptoms of infectious diseases. Contains sucrose.

Interactions: Other NSAIDs, anti-coagulants, heparins, corticosteroids, lithium, methotrexate, hydantoines and sulphonamides, diuretics, ACE inhibitors, antibacterial aminoglycosides and angiotensin II receptor antagonists, peroxylamine, zidovudine, sulfonylureas, beta-blockers, cyclosporin and tacrolimus, thrombolytics, anti-platelet agents and SSRIs, probenecid, cardiac glycosides, mifepristone, quinolone antibiotics.

Pregnancy and lactation: Do not use in pregnancy, lactation or in women attempting to conceive.

Undesirable effects: As with other NSAIDs, the most commonly observed adverse events are gastrointestinal. Peptic ulcers, perforation or gastrointestinal bleeding, sometimes fatal, particularly in the elderly may occur. Common (1-10%): Nausea and/or vomiting, abdominal pain, diarrhoea, dyspepsia. Uncommon (0.1-1%): insomnia, anxiety, headache, dizziness, somnolence, vertigo, palpitations, flushing, gastritis, constipation, dry mouth, flatulence, rash, fatigue, pain, asthenia, rigors, malaise. Rare (0.01-0.1%): anorexia, paraesthesia, syncope, hypertension, bradypnoea, peptic ulcer, peptic ulcer haemorrhage or peptic ulcer perforation, hepatic lesion, urticaria, acne, increased sweating, back pain, polyuria, menstrual disorder, prostatic disorders, peripheral oedema, liver function test abnormal. Very rare (<0.1%): neutropenia, thrombocytopenia, anaphylactic reaction including anaphylactic shock, blurred vision, tinnitus, tachycardia, hypotension, bronchospasm, dyspnoea, pancreatitis, hepatocellular injury, Stevens Johnson syndrome, toxic epidermal necrolysis (Lyell's syndrome), angioedema, facial oedema, photosensitivity reactions, pruritus, nephritis or nephrotic syndrome. Not known: laryngeal oedema, hepatitis, acute renal failure. As with other NSAIDs the following undesirable effects may appear: aseptic meningitis, which might predominantly occur in patients with systemic lupus erythematosus or mixed connective tissue disease; and haematological reactions (purpura, aplastic and haemolytic anaemia, and rarely agranulocytosis and medullar hypoplasia).

Pack size: 20 sachets.

Legal category: POM

Marketing authorisation number: PA 865/2/5

Marketing authorisation holder: Menarini International Operations Luxembourg S.A., 1 Avenue de la Gare, L-1611 Luxembourg.

Marketed by: A Menarini Pharmaceuticals Ireland Ltd

Further information is available on request to A Menarini Pharmaceuticals Ireland Ltd, 2nd Floor, Castlecourt, Monkstown Farm, Monkstown, Co. Dublin, Ireland or may be found in the SPC.

Date of preparation: September 2013

References:

1. MIMS edition, November 2013

2. Keral 25 mg granules for oral solution Summary of Product Characteristics, last updated September 2013

Coronally advanced flap + connective tissue graft techniques for the treatment of deep gingival recession in the lower incisors. A controlled randomised clinical trial

Zucchelli, G., Marzadori, M., Mounssif, I., Mazzotti, C., Stefanini, M.

Aim: The aim of this study was to compare the clinical and aesthetic outcomes of two different surgical approaches for the treatment of deep gingival recession affecting the mandibular incisors.

Methods: A total of 50 patients with Miller class I and II gingival recessions ($\geq 3\text{mm}$) in the lower incisors were enrolled. Some 25 patients were randomly assigned to the control group and the other 25 patients to the test group. All defects were treated with the coronally advanced flap + connective tissue graft (CAF + CTG) and in the test group the labial submucosal tissue (LST) was removed. Postoperative morbidity was evaluated at one week. Clinical and aesthetic evaluations were made at one year.

Results: Statistically greater recession reduction, probability of CRC (adjusted OR 7.94; 95% CI = 1.88-33.50, $p=0.0024$) and greater

increase in GT were observed in the test group. Greater graft exposure and increase in KTH were demonstrated in the control group. Better aesthetic outcomes were observed in the test group. No statistically significant between groups differences were demonstrated in patient analgesic consumption and postoperative discomfort and bleeding.

Conclusions: LST removal during CAF + CTG surgery is indicated to provide better root coverage and aesthetic outcomes in the treatment of gingival recession affecting the lower incisors.

J Clin Periodontol 2014; 41: 806-813.

Efficacy of reciprocating and rotary NiTi instruments for retreatment of curved root canals assessed by micro-CT

Rödig, T., Reicherts, P., Konietschke, F., Dullin, C., Hahn, W., Hülsmann, M.

Aim: To compare the efficacy of reciprocating and rotary NiTi instruments in removing filling material from curved root canals using micro-computed tomography.

Methodology: A total of 60 curved root canals were prepared and filled with gutta-percha and sealer. After determination of root canal curvatures and radii in two directions, as well as volumes of filling material, the teeth were assigned to three comparable groups ($n=20$). Retreatment was performed using Reciproc, ProTaper Universal Retreatment or Hedström files. Percentages of residual filling material and dentine removal were assessed using micro-CT imaging. Working time and procedural errors were recorded. Statistical analysis was performed by variance procedures.

Results: No significant differences among the three retreatment techniques concerning residual filling material were detected ($p>0.05$). Hedström files removed significantly more dentine than ProTaper Universal Retreatment ($p<0.05$), but the difference concerning dentine removal between both NiTi systems was not significant ($p>0.05$). Reciproc and ProTaper Universal Retreatment were significantly faster than Hedström files ($p=0.0001$). No procedural errors such as instrument fracture, blockage, ledging or perforation were detected for Hedström files. Three perforations were recorded for ProTaper Universal Retreatment, and in both NiTi groups, one instrument fracture occurred.

Conclusions: Remnants of filling material were observed in all samples with no significant differences between the three techniques. Hedström files removed significantly more dentine than ProTaper Universal Retreatment, but no significant differences between both NiTi systems were detected. Procedural errors were observed with ProTaper Universal Retreatment and Reciproc.

International Endodontic Journal 2014; 47 (10): 942-948.

Will you still be smiling at the end of the year?

Make sure your practice is profitable in 2014

As Ireland's only specialist dental accountants we're here to help you control your practice costs

QUARTERLY ACCOUNTS PAYROLL SERVICES

TAX CONSULTANCY COST OF TREATMENT

MedAccount SERVICES

Medaccount offer a full range of specialist dental accounting support and advisory services for Associates, Principals, Expense Sharing Partners

FIRST CONSULTATION FREE

MedAccount Services
 96 Lower Georges Street
 Dun Laoghaire
 Co Dublin
 Tel: 01 280 6414
 Email: info@medaccount.ie

First consultation free of charge, with no obligation to engage

Localised aggressive periodontitis treatment response in primary and permanent dentition

Merchant, S.N., Vovk, A., Kalash, D., Hovencamp, N., Aukhil, I., Harrison, P., et al.

Background: The comparative treatment response of children and young adults with localised aggressive periodontitis (LAP) affecting primary and permanent dentition is unknown. The objective of this study was to evaluate the influence of non-surgical periodontal therapy with adjunctive systemic antibiotics on the clinical outcome of children/young adults with primary versus permanent dentition affected by LAP.

Methods: A cohort of 97 African-American participants between the ages of 5 and 21 (30M; 66F; 22 primary and 75 permanent dentition affected), diagnosed with LAP, were included. Patients presented with no significant medical history. All patients underwent periodontal therapy, which consisted of full mouth mechanical debridement at baseline, and three-, six-, and 12-month appointments. Additionally, all patients were prescribed a one-week regimen of systemic antibiotics at the initial appointment. Clinical parameters were analysed, including probing depth (PD), clinical attachment levels (CALs), bleeding on probing (BOP) and percentage of visible plaque.

Results: Overall, periodontal therapy was found to be effective in improving the clinical outcomes of both primary and permanent dentitions. Although baseline CALs were similar between the groups, the reductions in mean CALs at three, six and 12 months, as well as reduction in % plaque at three months, were significantly greater in the primary dentition as compared to the permanent dentition.

Conclusions: Non-surgical therapy with systemic antibiotics is effective for LAP in both the primary and permanent dentitions. A greater reduction in CALs in LAP of the primary dentition may suggest that younger children may carry a greater propensity for positive treatment outcomes and healing potential as compared to children/young adults with permanent dentition.

J Periodontol 2014; 1-13. [Epub ahead of print.]

Analysis of pulp prognosis in 603 permanent teeth with uncomplicated crown fracture with or without luxation

Wang, C., Qin, M., Guan, Y.

Aim: To analyse the pulp prognosis of uncomplicated crown-fractured teeth with or without concurrent luxation injury in adolescents.

Material and methods: Complete dental records of traumatised permanent teeth were obtained, including the patient's name, gender and age, position of the traumatised tooth, its stage of root development, time elapsed between dental injury and treatment, diagnosis, clinical procedures, and follow-up period. Pulp prognosis was evaluated over a period of at least six months using Andreasen's

classification. Kaplan-Meier method and Cox regression were used to examine the risk factors inherent to the prognosis of pulp healing, with $p < 0.05$ accepted as statistically significant.

Results: The study involved 603 teeth with uncomplicated crown fractures followed up for six months or longer, of which 104 suffered luxation at the same time. The frequency of pulp necrosis in teeth with complete root development was higher than in those with incomplete root development. For uncomplicated crown fracture with luxation, crown-fractured teeth with intrusion had a higher incidence of pulp necrosis than other types of concurrent luxation (OR: 33.613). The incidence of pulp necrosis within three months was significantly higher than in other time periods ($p = 0.021$), and the median survival time was 53 days (95% confidence interval: 34-67 days).

Conclusions: Existence of concurrent luxation injury and complete root development are important risk factors of pulp necrosis in teeth with uncomplicated crown fractures in adolescents.

Dental Traumatology 2014; 30 (5): 333-337.

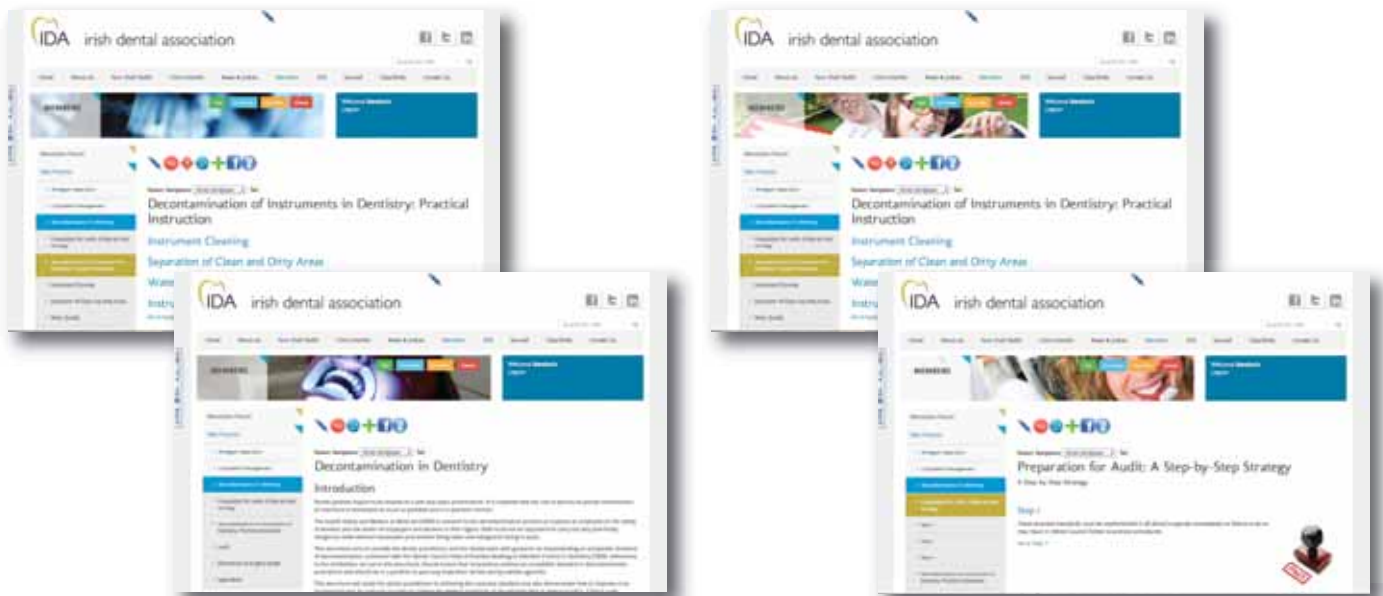
QUIZ

Questions
page 222

1. b) Full-time workers have the right to four working weeks' paid annual leave. Part-time workers have the right to a proportional amount of annual leave based on the amount of time they work.
2. a) The basic period of maternity leave is 26 weeks. At least two weeks of this must be taken before the end of the week of the expected date of birth, and at least four weeks after the birth. The remaining 20 weeks can be taken as the employee decides. Employees usually take two weeks before the birth and 24 weeks after. Employers are not obliged to pay an employee who is on maternity leave (unless there is an agreement to the contrary) and employees are entitled to a Maternity Benefit payment from the Department of Social Protection. An additional 16 weeks' unpaid leave may be taken. This is not covered by the Maternity Benefit payment from the Department of Social Protection and again, employers are not obliged, unless there is an agreement to the contrary, to make any payment during this period.
3. c) Workers have the right to a 15-minute break after four and a half hours of work and a 30-minute break after six hours of work (which may include the first 15-minute break).
4. b) The Minimum Notice and Terms of Employment Act 1973 requires an employee to give an employer a minimum of one week's notice when leaving. However, a contract of employment may require an employee to give more notice and the contractual notice period must be adhered to irrespective of the statutory minimum.

Best Practice – a vital new resource for Irish dentists

The members' section of the IDA website is full of essential advice, including important best practice documents that are easy to use. ANN-MARIE HARDIMAN reports.



Among the many benefits available to members of the Irish Dental Association, the members' section of the IDA website (www.dentist.ie) contains a wealth of information and advice on all aspects of dentistry in Ireland.

As well as forums where dentists can discuss in confidence issues that affect them in practice, members can also access archived editions of IDA member communications such as the IDA Update, regular e-newsletters, and the Dáil Digest.

General dental practitioners (GDPs) and HSE dentists can find out about the work of their representative committees, as well as updates on all of the Association's advocacy activities. There's also information on membership rates and governance.

Practice management

The practice management section covers a huge range of information for dentists in private practice, from employment rights to marketing strategies and complaint handling. The Association has prepared *pro forma* contracts to assist in staff recruitment, and guidance on tax classification issues for associates and hygienists. There is also information on Dental Council Codes of Practice, and everything you need to know about setting up/purchasing a practice.

Best practice

In recent years, the amount of legislation and regulation, often emanating from Europe, that has become part of the dentistry landscape, has increased considerably. Compliance can often seem like an onerous task and dentists might feel overwhelmed by the

amount of work that needs to be done to bring their practice into line with requirements. To address these issues, the Quality and Patient Safety Committee of the Association has prepared a range of guidance documents for members to help them navigate the minefield of regulations.

Dr Eamon Croke is the Chair of the Quality and Patient Safety Committee, and he describes its work as follows: "The Quality and Patient Safety Committee looks at legislation and regulation, gathers the available information and tries to bring that information to members in an easy-to-use fashion".

Where possible, the Committee has also developed audit tools to allow members to measure their compliance with these regulations. The Best Practice section of the website brings these documents together, and covers topics such as amalgam separation, complaints management and decontamination.

Certain topics have been of particular interest in recent times. Radiology in practice is subject to specific legal requirements, and infection control and prevention is also subject to a legal and regulatory framework, with specific Dental Council Guidelines, which the Committee has addressed in its documents.

Another very topical issue, according to Eamon Croke, is hand hygiene. "We have facilitated workshops on this topic, as the World Health Organisation has said that it is absolutely critical in infection prevention and control. So this is an important issue for Irish dentists."

Data protection

In addition to the services already available, the Best Practice section

will shortly include a document on data protection for the dental practice.

The Committee held its first ever non-clinical workshop on this topic at the IDA's Annual Conference in Kilkenny earlier this year, working with Alan O'Grady, a Senior Compliance Officer with the Office of the Data Protection Commissioner. This work has led to the forthcoming document, which the Committee hopes will be invaluable to members.

The document will take the form of a practice privacy statement, which will acknowledge the eight rules of data protection as set out in data protection legislation.

"The idea is for members to use [this document] as a template," says Dr Croke. "If they do, they will be covered as regards the regulations on data protection, and it is also an opportunity to inform themselves on data protection issues."

There will also be an audit document allowing dentists to measure their performance on each of the eight data protection rules. Each audit will be short, with the exception of the section on security, which will be short for dentists who run a paper-based practice but longer if the practice is digital. "More and more dentists are storing

information on handheld devices such as tablets or smartphones, which increases security risks."

What are you waiting for?

Dr Croke urges members to make use of these excellent best practice resources, which have a number of advantages: "More and more, dentists are obliged to fulfill regulatory and legal requirements, and this is a step-by-step way of doing it".

He also points to the fact that practices preparing for HSE inspections in relation to registration to accept medical card patients have found the best practice section of the website very useful.

Furthermore, the Dental Council will shortly issue new guidelines in relation to continuing professional development (CPD), and it is expected that audit will be included in these guidelines as a core competency, so this resource will be of great value.

The Quality and Patient Safety Committee is always happy to receive feedback from members on its work and on the documents included on the website, including suggestions for new topics and sections. Members can be contacted through IDA House.

Dental Implants

Everything together.

One price, one provider.

Enjoy certainty of price with our new all-inclusive implant bundle.



Premium Bundle Fully customised system

Includes:

- ✓ Screw or cement retained crown (choice of Porcelain fused to Metal**, Fully Milled Zirconia, Porcelain fused to Zirconia)
- ✓ Customised Titanium or Zirconia Abutment
- ✓ Titanium Screw
- ✓ Implant analog and soft tissue model
- ✓ Major commercial systems supported

* Terms and conditions apply
** Semi or High precious alloy centre

SCDlab.co.uk

To find out more information call us today
on (ROI) 048 8772 7100 or (NI) 028 8772 7100
or email us at ireland@scdlab.com

Classified advert procedure

Please read these instructions prior to sending an advertisement. Below are the charges for placing an advertisement for both members and non-members. Advertisements will only be accepted in writing via fax (01- 295 0092), letter or email (fionnuala@irishdentalassoc.ie). Non-members must pre-pay for advertisements, which must arrive no later than November 3, 2014, by cheque made payable to the Irish Dental Association. If a box number is required, please indicate this at the end of the ad (replies to box number X). Classified ads placed in the *Journal* are also published on our website www.dentist.ie for 12 weeks.

Advert size	Members	Non-members
up to 25 words	€75	€150
26 to 40 words	€90	€180

Non-members must send in a cheque in advance with their advert. The maximum number of words for classified ads is 40.

Only if the advert is in excess of 40 words, then please contact: Think Media

The Malthouse, 537 North Circular Road, Dublin 1.
Tel: 01-856 1166 Fax: 01-856 1169 Email: paul@thinkmedia.ie

Please note that all classified adverts MUST come under one of the following headings:

- ▶ Positions Wanted
- ▶ Positions Vacant
- ▶ Practices for Sale/To Let
- ▶ Practices Wanted
- ▶ Unwanted/Second Hand Equipment for Sale

Classified adverts must not be of a commercial nature. All commercial adverts must be display advertisements, and these can be arranged by contacting Paul O'Grady at Think Media, Tel: 01 856 1166.

POSITIONS WANTED

Implant dentist available to add to treatments available in your practice. Masters level qualification, more than seven years' experience. All locations considered. Email: irishdentalimplants@gmail.com.

POSITIONS VACANT

Part-time associate required for 2.5 days a week in busy Dublin city centre practice. Fully computerised, OPG, etc. Please email CV to dentaldublin@gmail.com.

Associate position available two days per week. Gorey, 45 minutes from South Dublin. Starting September. Experience preferred. Self-employed status. Hygienist, digital x-rays, OPG, full support staff. Bright airy surgeries, part computerised. Email: info@thebridgedentalsurgery.ie.

Associate position available, three days per week. Experience preferred, self-employed status. Full support staff, friendly atmosphere. Reply to: campbelldental@yahoo.ie.

Associate dentist required for a busy family dental practice located in a rural community about one hour north of Calgary, Canada. All aspects of dentistry experience an asset. Please send CV to gillesdental@yahoo.ca.

Associate dentist required for a busy family dental practice in Castletownbere, Co. Cork. Computerised, friendly support staff. Immediate start. Tel: 086-849 1873, or reply to keoh1981@gmail.com.

Full-time experienced associate required for group practice in south east – one hour from Dublin. Excellent equipment, staff and atmosphere, visiting specialists, implants, on-site laboratory. Fantastic opportunity for ethical, enthusiastic, productive colleague. Minimum three years' experience necessary. Email: southeastdental46@gmail.com.

Associate required – Dublin 6. Ambitious, flexible associate required. Busy modern practice. Excellently equipped. Fully computerised. Knowledgeable staff. Hygienist service. Employee/self-employed status. Low overheads. Excellent profits. View to purchase. Immediate start. Tel:

086-807 5273, or Email: niall@innovativedental.com.

Part-time dental associate position available for busy, established Co. Cavan dental practice. Air-conditioned, digital radiographs, experienced friendly staff, hygienist service, modern equipment. Email: dentaljobcavan@yahoo.co.uk.

Part-time dental associate required for busy modern practice in Galway city. Experienced friendly staff, digital radiography and hygienist service. Please reply to kdavitt@hotmail.com.

Associate required for busy Dublin 13 practice. Please send CV to 1casanaview@gmail.com.

Dentist required two days per week in the Kerry area. Replies to Box No. 848.

Full/part-time dentist experienced in prosthodontics required in busy Cork private practice. Computerised, digital x-ray and CT, modern five-surgery practice. Immediate start/long-term view. Must be warm and friendly. Email CV to corkdentalpractice@gmail.com.

Part-time dentist required for Cork city suburb to replace departing colleague. Start September. Please send CVs to corkdentaljob@gmail.com.

Dentist required to take over block of patients of departing associate in established practice. Applicant should be experienced in general dentistry. Please apply to The Central Dental Clinic, Lucan Village, Co. Dublin, or Email: office@centraldentalclinic.ie.

Part-time dentist wanted for two to three days per week. Modern progressive practice in Co. Galway. Good opportunity for enthusiastic and caring candidate. Email: galwaydent14@gmail.com.

Part-time dentist required for busy south east practice. Modern, computerised with full support staff. Perfect for caring and progressive person. Immediate start available. Email: catriona7339@gmail.com.

Experienced dentist required Cork City to cover part-time for a few months. Immediate start. Email CV to oscardermody@eircom.net.

- New private practice in Dundalk looks for part-time dental nurses, dentists, with a view to extend. For details please Email dentaljob.dundalk@gmail.com.
- Dentist required for Saturdays in modern progressive practice with full clinical back-up. One hour from Dublin. Guaranteed full book. Immediate start. Email: southeastdental46@gmail.com.
- Dentist required three days a week in Waterford city. Modern surgery with friendly support staff. Immediate start available. Reply with CV to dentistrequired3@gmail.com.
- Dentist required for expanding Dublin 4 practice, Tuesday and/or Wednesday afternoon/late evening and Saturday morning. Contact Emma/James, Tel: 01-664 3484, or Email: info@grandcanaldentalclinic.ie.
- Ireland's largest private multidisciplinary centre in Blackrock is looking for a general dentist and also an implant dentist/periodontist to join their busy team. Opportunity to receive external/in-house referrals. On-site laboratory. Applicants should display experience in range of disciplines. Contact victoria@seapointclinic.ie.
- Limerick. Experienced (min. three years) ambitious dentist required for high-profile, modern, busy clinic. Part-time initially with potential to increase to full-time. Computerised, OPG, new equipment, excellent staff. Generous terms for right candidate. Email: limerickdentaljob@gmail.com.
- Locum needed – Waterford. Beginning August for six to seven weeks. Tel: 087-212 6002, or Email: dolphindental7@gmail.com.
- Locum dentist required part-time to cover maternity leave from October in Longford – may lead to long-term opportunity. Email: longdentcent@gmail.com.
- Locum dentist required for part-time maternity cover in a busy north Cork practice. Starting October. Please send CVs to Mallowdentist@gmail.com.
- Locum dentist required for month of November 2014. Practice in Midlands town approx. one hour from Dublin. Candidates should have experience and be capable of operating independently. Well-established practice, nurse and receptionists all in place. CVs welcome by email to cedar.clinic.dental.surgery@gmail.com.
- Two-surgery dental practice in Carndonagh, Co. Donegal seeks locum with a view. Full book six days a week. Also possible part-time position in Killybegs, Co. Donegal. Reply to donegaldental@yahoo.ie.
- Orthodontist required for expanding Cork general practice. Please send CV to receptioncork@gmail.com.
- Orthodontist required to work in very busy private practice in south east. Multiple chairs available. Must be on the Irish specialist register. Email: southeastdentaljobs@gmail.com.
- London, Notting Hill. Part-time orthodontist required for immediate start in brand new boutique private practice. Patient list in place. Please send CVs to info@number18dental.com.
- Opportunity available for specialist prosthodontist in a well-established multidisciplinary dental practice in the Galway Clinic, Galway City, Ireland. Practice predominately referral based and specialises in implant, prosthetic and surgical dentistry. Enquiries to Linda, Tel: 091-720045, Website: obmspecialistdentistry.ie, or Email: suiteg9@gmail.com.
- Hardworking and enthusiastic dental nurse required for busy, friendly specialist dental practice. Previous experience is essential. Email: mags@ncdental.ie.
- Part-time qualified dental nurse for dental clinic in Midleton. Good rate of pay for suitable candidate. Please send CV to carmel@corabbeydentalclinic.ie.
- Qualified dental nurse needed part-time in Co. Galway. Email: dentalsurgeryco.galway@gmail.com.
- Experienced part-time dental nurse required with a view to becoming full-time. Immediate start. Please forward CVs to fiachloir@live.com.
- Qualified dental nurse required for two days a week, Monday and Tuesday, 8.00am-6.00pm with the ability to be flexible to cover holidays, etc. Email: admin@cdpractice.com.
- Dental nurse required for busy modern dental practice in the North Cork area. Excellent equipment and atmosphere. Computer skills essential. Experience preferable but not essential. Fantastic opportunity to become part of our progressive team. Email: nualacagney@gmail.com.
- Looking for dental nurse/receptionist, Saturday mornings only. Three Saturdays per month, 9.00am-1.00pm. October Start. Dun Laoghaire. Contact Jackgrennan@gmail.com.
- Part-time qualified dental nurse required for an expanding dental surgery on Wednesdays and Saturdays, in the Lucan area. Email: westdublindental@gmail.com.
- Part-time qualified dental nurse required for busy South Dublin dental surgery. Email: alex@beechwooddental.ie.
- Experienced dental nurse required to cover maternity leave from late October. Modern bright surgery in Carlow town and a really fun environment to work. Potential for retention after the leave. Email: info@kiwidental.ie.
- Dental assistant required two days per week, Swords. Experience, communication and computer skills essential. Contact smile@oneilldentalcare.ie.
- Hygienist wanted, Fridays only, well-established Dublin 2 practice. Must be friendly with positive, welcoming attitude. Duties include a good mix of periodontal treatments and hygiene maintenance treatments. Please send cover letter and CV to vacancies@dentistry.ie.

PRACTICES FOR SALE/TO LET

- Galway city centre practice sale/lease. 85% private. Excellent opportunity for dentist with interest in advanced restorative work (high demand). Two surgeries, third surgery planning granted, room for expansion. Highly visible, prestigious location, high footfall.
- Confidentiality guaranteed. Email: dentistgalway8@gmail.com.
- Practice with residence in prime Cork suburb for sale. Established 35 years. Will need some renewal. Freehold property with planning. Reply to Box No. 851.
- Practice for sale – Clare. Very busy, freehold, full planning permission, long established, two surgeries. Modern, well-equipped, walkinable. Excellent loyal staff. Immediate profits. Very low overheads. Huge catchment close by. Great potential for growth. Principal retiring. Suits ambitious associate. Tel: 086-807 5273, or Email: niall@innovativedental.com.
- Practice for sale in Waterford City. Bright premises with modern equipment in prime city centre location. Two surgeries. Low overheads with tax allowances transferable. Very low entry price reflecting quick sale. Email: waterfordpracticeforsale@gmail.com.

For sale. Busy, long-established dental practice in thriving Midlands town.

Two surgeries, OPG and fully computerised. 80% private. Reply in confidence to dentalpracticesale2014@gmail.com.

Practice for sale, Co. Mayo. Very busy, long-established, well-equipped walkinable three-surgery practice. Digitalised. Hygienist. Excellent, loyal staff. Immediate profits. Large potential for growth. Principal retiring – price negotiable for speedy sale. Suits ambitious associate. Tel: 086-807 5273, or Email: niall@innovatedental.com.

Practice for sale. Dentist retiring, immediate sale required of long-established, high quality, exclusively private practice in Blackrock Clinic, Dublin. Reception, office, two fully equipped rooms. Fully computerised, would suit experienced personable dentist. Contact rfehily@hotmail.com.

For sale, Trim, Co. Meath. Established dental practice (as a going concern). Contact Sherry Fitzgerald Royal, Trim, Co. Meath. Tel: 046-943 1525, or Email: aidan@sherryfitzroyal.ie.

Dedicated specialist room available in a 2,000 sq ft custom-built practice in Ennis Town Centre. Part of a multi-surgery practice that includes three dentists, two hygienists and an OPG. Excellent daily rate. Email: gbrowne.ennis@eircom.net.

Part-time orthodontic practice in Ennis available due to colleague retiring. Established 20 years. Huge potential for expansion. Part of a multi-surgery practice that includes three dentists, hygienists and an OPG. Excellent daily rate. Contact gbrowne.ennis@eircom.net.

For Sale. Chris Emery's endodontic practice, Portsmouth, UK. Established 16 years. Two-surgery, fully digital, large freehold property, room for development. Principal willing to work alongside new owner. 2014 Gross £447,625.00. Agent Lily Head – www.lilyhead.co.uk. Contact Linda Barry, Tel: 077-8047-4292, or Email: lh@lilyhead.co.uk.

For Sale – South Dublin – Rathmines. Busy, high-profile location. Excellent footfall. Good equipment. Fully computerised. Hygienist. Room for expansion – plans available. Very low overheads. No medical card. Excellent profits. Very competitively priced – dentist retiring. Tel: 086-807 5273, or Email: niall@innovatedental.com.

Full surgery available for day rental in Dublin 13. Suitable for visiting orthodontist. Email: info@smiledesigndental.ie.

PRACTICES WANTED

I wish to buy a practice in/around Dublin from a retiring colleague. Principal can stay for smooth transition. Please reply by Email: buyingpractice@hotmail.com.

Wicklow, South Dublin premises. Practice required. Modern, bright building, ground floor. Disabled access. Current planning permission. Parking on site close. Good footfall. Minimum 1500 sq. ft. Freehold leasehold flexible. Quick turnaround guaranteed. Confidentiality assured. Right location crucial. Email: irishdentalsurgeons@gmail.com.

EQUIPMENT FOR SALE

Surgery equipment for sale. Green Kavo chair 1999 with fibreoptics, cabinetry – 170cm with corian worktop and integrated sink, Trophy x-ray, Zoom light. Photos available on request. Price: €3,900 with delivery. Contact: 098-28753 or Email: info@westportdental.ie.

Diary of events

OCTOBER

Faculty of Dentistry RCSI Annual Scientific Meeting 2014

Thursday and Friday 30-31

RCSI Dublin

For further information, Email: facdentistry@rcsi.ie.

NOVEMBER

CPD Roadshow – Limerick

Saturday 8, 10.00am to 1.00pm

IDA MEMBERS ONLY

Strand Hotel

IDA Metropolitan Branch Meeting

Thursday 13

IDA MEMBERS ONLY

Alexander Hotel, Dublin 2

CPD Roadshow – Kilkenny

Saturday 15, 10.00am to 1.00pm

IDA MEMBERS ONLY

Lyrath Hotel

CPD Roadshow – Dublin

Saturday 15, 10.00am to 1.00pm

IDA MEMBERS ONLY

Radisson Hotel, Dublin Airport

Munster Branch Annual Scientific Meeting and Dinner

Friday 21

Fota Island

CPD Roadshow – Galway

Saturday 22, 10.00am to 1.00pm

IDA MEMBERS ONLY

Clayton Hotel

JANUARY 2015

Metropolitan Branch Meeting

Thursday 29

IDA MEMBERS ONLY

Hilton Hotel, Dublin

FEBRUARY

Metropolitan Branch Meeting

Thursday 12

IDA MEMBERS ONLY

Alexander Hotel, Dublin 2

MARCH

Metropolitan Branch Annual Scientific Meeting

Friday and Saturday 6-7

Alexander Hotel, Dublin 2

APRIL

IDA Annual Scientific Conference 2015

Thursday to Saturday 16-18

Rochestown Park Hotel, Cork

NOVEMBER

Irish Society of Dentistry for Children – Get Ready: dental and medical emergencies in children

Thursday 14

Louis Fitzgerald Hotel, Dublin

Proudly supporting

Mouth Cancer Awareness Day 2014

 DeCare
Dental



Mouth Cancer Awareness Day, September 17th 2014

Pictured above at the Dublin Dental Hospital information day is:
Dr. Ger Gavin, Chief Dental Officer DeCare Dental, Dr. Denise MacCarthy, Associate Professor / Consultant and Current Dental Students from Dublin Dental Hospital

DeCare Dental Insurance Ireland Limited trading as DeCare Dental and DentalCover.ie
is regulated by the Central Bank of Ireland

Get in touch

T: 1890 130 017

E: query@decaredental.ie

W: www.decaredental.ie

 DeCare
Dental

new

1 COMPLETE SENSITIVITY TOOTHPASTE SPECIALLY DESIGNED WITH 7 BENEFITS*



Powered by NovaMin®



*With twice daily brushing

SENSODYNE, NOVAMIN and the rings device are registered trade marks of the GlaxoSmithKline group of companies.

SENSODYNE